




Christopher Herron<sup>1</sup> , David Morales<sup>2,3</sup> and Shabana Shahanavaz<sup>2,4</sup>

## Brief Report

**Cite this article:** Herron C, Morales D, and Shahanavaz S (2024). Transcatheter knocking of a stuck mechanical tricuspid valve. *Cardiology in the Young*, page 1 of 3. doi: [10.1017/S1047951124000660](https://doi.org/10.1017/S1047951124000660)

Received: 13 November 2023

Revised: 10 January 2024

Accepted: 24 February 2024

### Keywords:

mechanical tricuspid valve; transcatheter knocking; CHD

### Corresponding author:

S. Shahanavaz;

Email: [shabana.shahanavaz@cchmc.org](mailto:shabana.shahanavaz@cchmc.org)

<sup>1</sup>Department of Pediatric Cardiology, Arnold Palmer Hospital for Children, Orlando, FL, USA; <sup>2</sup>The Heart Institute, Cincinnati Children's Hospital Medical Center, Cincinnati, OH, USA; <sup>3</sup>Division of Cardiothoracic Surgery, Cincinnati Children's Hospital, Cincinnati, OH, USA and <sup>4</sup>Division of Pediatric Cardiology, University of Cincinnati College of Medicine, Cincinnati, OH, USA

### Abstract

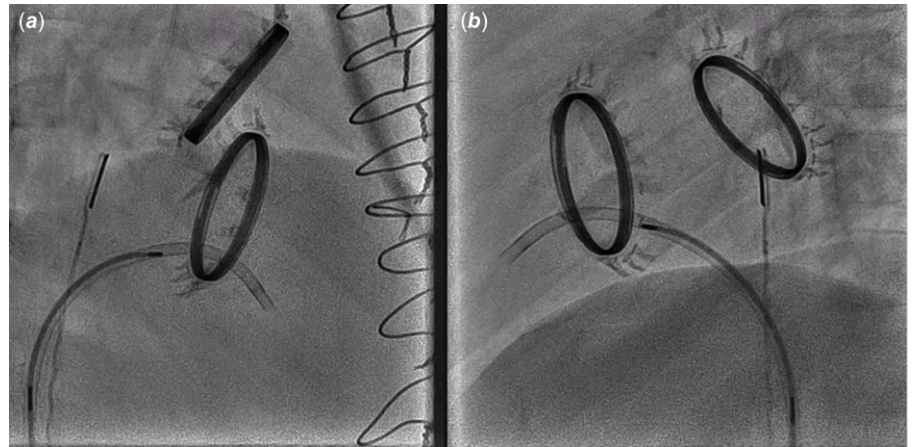
Immobilisation of mechanical valve leaflets can be a life-threatening complication. In the acute setting, medical therapy can be attempted but is not always successful. We present the first described case of a patient with a mechanical tricuspid valve with recurrent leaflet immobilisation that was able to be mobilised using a transcatheter knocking technique.

Stuck mechanical valves can cause significant haemodynamic compromise and require immediate attention. The mechanism for valve failure ranges from thrombus, pannus formation, and leaflet dysfunction. We present a unique case of a paediatric patient who underwent transcatheter knocking of a stuck mechanical tricuspid valve.

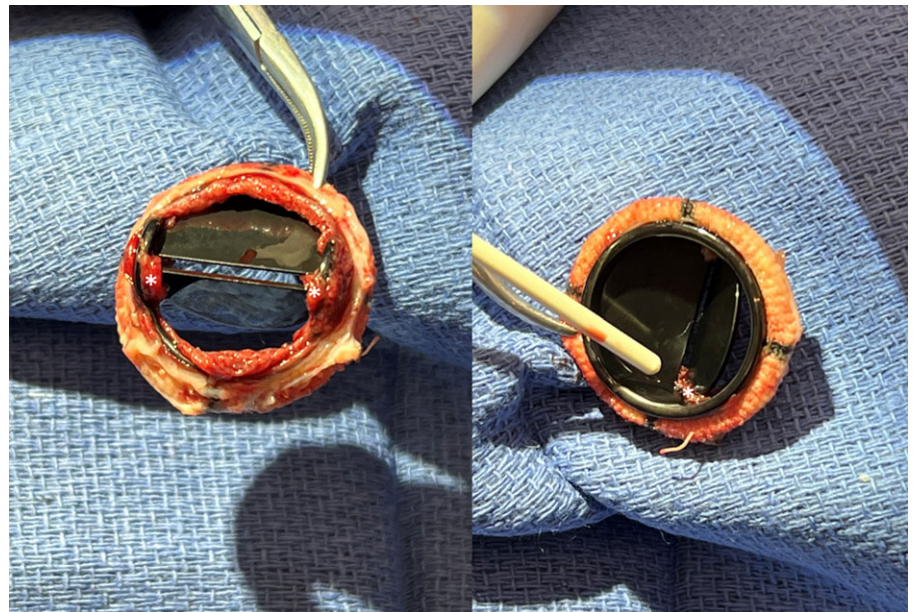
### Case report

A 5-year-old male who was born with tricuspid and mitral valve dysplasia and significant regurgitation of both valves initially underwent a repair of both valves as a neonate but ultimately required mechanical valve placement in both positions as a 5 year old. A 21 mm St Jude (Abbott, Illinois, USA) mechanical valve was placed in the mitral position and a 23 mm St Jude mechanical valve was placed in the tricuspid position. Three months post valve placement, he was found to have moderate tricuspid valve regurgitation, with one leaflet stuck in a partially closed position while the other leaflet opened appropriately. He was found to have fusobacterium on blood cultures and was treated with IV antibiotics. He was initially treated with multiple doses of tPA which initially provided some increased leaflet mobility but over the course of a month became immobile despite repeat dosing. The decision was made to bring the patient to the cardiac catheterisation lab for attempts at knocking the stuck mechanical valve open.

The patient was placed under general anaesthesia and the mechanical valves were imaged. The superior leaflet of the mechanical tricuspid valve had appropriate movement while the inferior leaflet was stuck closed. Through a 6 Fr sheath in the right femoral vein, a 6 Fr JR 3.5 catheter with a tip deflector was used to knock the inferior mechanical valve (Fig 1). The inferior leaflet was able to be pushed into the open position multiple times but once the catheter was withdrawn, the leaflet would mobilise back to the stuck position. With the leaflet remaining stuck, the patient was taken back to the OR for replacement of the mechanical tricuspid valve with another 23 mm St Jude mechanical valve. The removed valve had significant pannus formation on the stuck leaflet (Fig 2). The patient was able to be discharged home post procedure. Four months post replacement, the patient underwent removal of a nasal encephalocele, and his warfarin was stopped 5 days prior to this procedure; he was maintained on lovenox. Post procedure he was reinitiated on heparin with plan to transition to warfarin. On the 3<sup>rd</sup> post-operative day, he had an acute increase in his heart rate and had a repeat echocardiogram with concern for restricted motion of his leaflet on his mechanical tricuspid valve with a 10 mmHg mean gradient through it and moderate regurgitation. Due to the recent neurosurgery, systemic tPA could not be used and the patient could not be placed on cardiopulmonary bypass. He was again brought back to the cardiac catheterisation lab to attempt mobilising the tricuspid valve leaflets. Initial fluoroscopy showed decreased motion of the superior leaflet and no movement within the inferior leaflet (Supp Fig1). Through a 6 Fr sheath and 6 Fr MPA catheter, along with a tip deflector, they were able to be passed through the inferior and superior leaflets (Supp Fig 2). Post intervention, the inferior leaflet had significantly improved motion while the superior leaflet remained stuck (Supp Fig 3). The mean gradient improved to 4 mmHg post intervention. Unfortunately, the inferior leaflet became stuck again within 2 days. A week later after being cleared by neurosurgery, he underwent replacement of his



**Figure 1.** (a) RAO 47deg, cranial 19deg. (b) LAO 90deg, caudal 4deg. The JR catheter with the tip deflecting wire can be seen crossing the lateral leaflet of the tricuspid valve opening it. There is an intracardiac echo probe also in the right atrium.



**Figure 2.** Explanted mechanical tricuspid valve seen with significant pannus formation (\*) present on the leaflet joint.

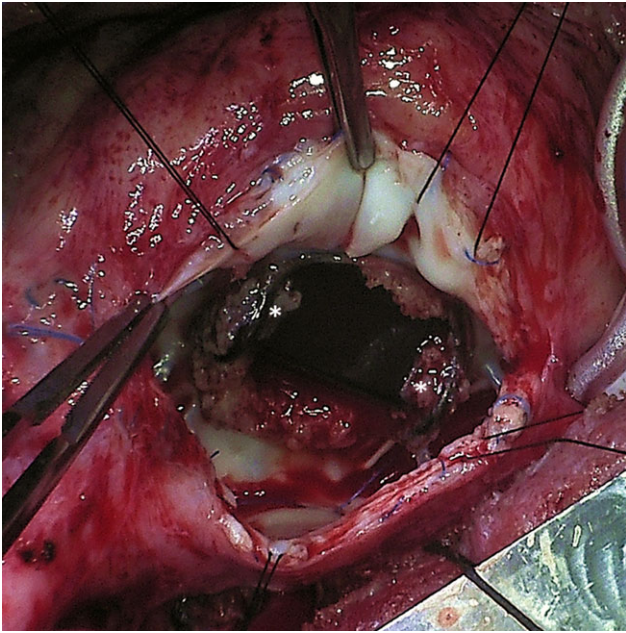
tricuspid valve with a 23 mm CoreMatrix bioprosthesis valve. The mechanical tricuspid valve was again found to have pannus within the leaflets (Fig 3).

### Discussion

Mechanical valve leaflets that become immobile pose a significant risk and can be very difficult to manage. Medical management is the first line of therapy and can be attempted but risk factors can sometimes preclude patients from being managed this way such as our patient's recent neurosurgery.<sup>1,2</sup> We present a unique case of a paediatric patient with a stuck mechanical tricuspid valve that was able to be knocked open via a transcatheter approach.

Transcatheter knocking of a stuck mechanical valve can be a viable option in patients with an acutely immobile valve, failed medical therapy, or if not a candidate for medical treatment. Previous case reports have described the use of balloon valvuloplasties for release of stuck leaflets.<sup>3-5</sup> We approached

the tricuspid valve with a stiffer catheter such as the JR or MPA catheter and a tip deflecting wire to optimise the angle of approach. Supplementary video 2 depicts the angled approach to the stuck mechanical leaflet and the force, aka knocking, required to open the leaflet. Caution should be taken when using force to open a mechanical leaflet as leaflet embolisation is possible with this technique as well as the catheter becoming entrapped within the leaflet. This technique was performed in a mechanical leaflet stuck in the closed position. Performance of this technique in a leaflet stuck in the open position could lead to the leaflet being stuck closed and haemodynamic instability. While the leaflet was able to be opened in the first case, once the catheter was removed, the leaflet retracted to its stuck position due to the pannus formation that was present. While this technique did not work in the long term due to the pannus formation both times, in the acute setting, this technique can be helpful even with pannus formation. In each case, our technique provided enough time for the patient to be safely brought to the OR for valve replacement.



**Figure 3.** The 2<sup>nd</sup> explanted mechanical tricuspid valve with pannus formation (\*) present on the leaflet joint.

### Conclusion

We present the first described case of a paediatric patient with stuck mechanical tricuspid valve leaflets that were able to be mobilised via a transcatheter knocking approach. While pannus formation on the leaflets limited the duration of transcatheter

mobilisation, this technique can still be considered in certain circumstances to mobilize stuck leaflets.

**Supplementary material.** The supplementary material for this article can be found at <https://doi.org/10.1017/S1047951124000660>.

**Financial support.** None.

**Competing interests.** None.

**Ethical standard.** All procedures performed in studies involving human participants were in accordance with the ethical standards of the institutional and/or national research committee and with the 1964 Helsinki Declaration and its later amendments or comparable ethical standards. Informed consent was obtained from all individual participants included in this case report.

### References

1. Soria Jiménez CE, Papolos AI, Kenigsberg BB, et al. Management of mechanical prosthetic heart valve thrombosis: JACC review topic of the week. *J Am Coll Cardiol* 2023; 81: 2115–2127.
2. Taherkhani M, Hashemi SR, Hekmat M, Safi M, Taherkhani A, Movahed MR. Thrombolytic therapy for right-sided mechanical pulmonic and tricuspid valves: the largest survival analysis to date. *Tex Heart Inst J* 2015; 42: 543–547.
3. Chen Y, Waksman R, Satler L, Barnett C, Chen A, Rogers T. Percutaneous transcatheter release of stuck mechanical mitral valve leaflet. *Eur Heart J* 2020; 41: 4072–4072.
4. Smith D, Khurana A, Youhana A, Ionescu A. Kissing balloon “valvuloplasty” of obstructed mechanical aortic valve: when you are running out of options. *JACC Case Rep* 2022; 4: 799–801.
5. Kandzari DE, Carlson H, Gott JP, Kaul P, Brown WM. Balloon “valvuloplasty” for mechanical valve dysfunction. *JACC Cardiovasc Interv* 2017; 10: e47–e49.