

(mean age 29.35 ± 7.41 years) underwent T1-weighted structural MRI at 3T Philips scanner and clinical examination. Images were processed using FreeSurfer 7.1.1. Cortical thickness and area, volumes of subcortical structures and separately volumes of the amygdala nuclei and hippocampal subregions were compared between groups. The morphometry data, PANSS (Positive and Negative Syndrome Scale), CDSS (Calgary Depression Scale for Schizophrenia) and daily chlorpromazine equivalent doses of antipsychotics were included in correlational analysis. Results were considered significant if they retained significance after correction for multiple comparisons.

Results: Compared to healthy controls, TRS patients showed decreased gray matter thickness in frontal, temporal, parietal, occipital, cingulate and insular regions (Figure 1). The temporal lobe showed the most prominent thinning of the cortex. The volumes of the amygdala, hippocampus (Figure 2) and nucleus accumbens, a number of amygdala nuclei and hippocampal subregions bilaterally were also decreased in TRS patients. The volume of the right globus pallidus, on the contrary, was increased (Figure 2). No correlations between altered cortical thickness, PANSS (positive, negative, general psychopathology scales and total score), CDSS and chlorpromazine equivalent doses of antipsychotics were found.

Image:

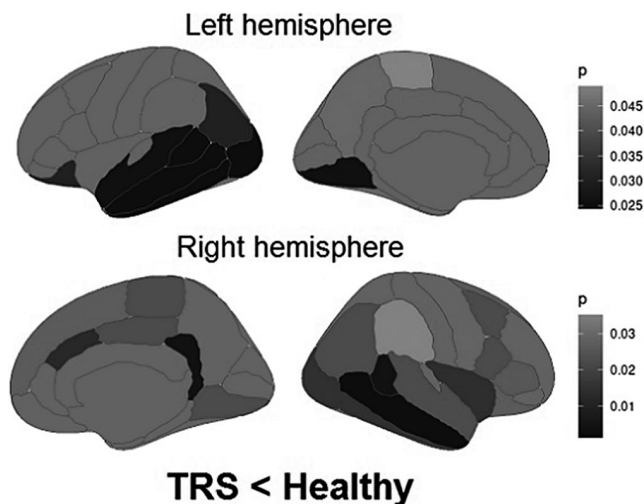
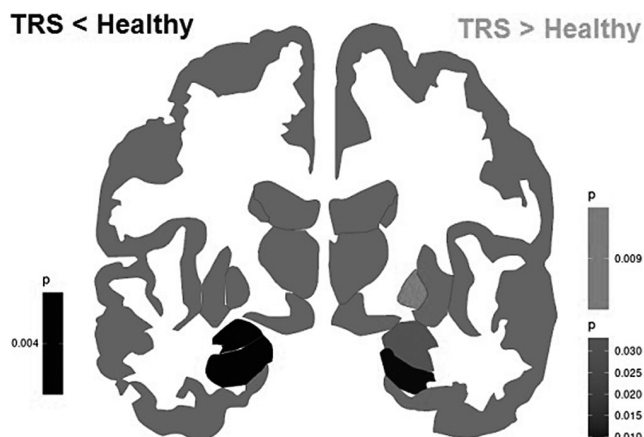


Image 2:



Conclusions: The widespread gray matter cortical and subcortical loss in TRS finds confirmation in the literature. The increased globus pallidus volume is an unexpected and intriguing result. Other studies demonstrated conflicting results on that point. Some studies reported possible therapy influence, others suggested possible associations with symptoms. We did not find any correlations with psychometric or therapy characteristics. It is possible that there are non-linear relationships or relationships that exist only at a certain stage of the disease. As for therapy, patients took individual medication, consisting of various antipsychotics and drugs from other pharmacological groups, and such heterogeneity could affect the results of the study. Further research is going to be carried out.

Disclosure of Interest: None Declared

EPV0617

Brain activity behind the negative and positive emotions: an experimental setting with functional near-infrared spectroscopy (fNIRS)

B. Kabella^{1*}, A. Fehér² and J. Lazáry¹

¹Psychiatry, National Institute of Mental Health- Neurology and Neurosurgery and ²Semmelweis University – Medicine and Health Sciences, Budapest, Hungary

*Corresponding author.

doi: 10.1192/j.eurpsy.2024.1282

Introduction: The fNIRS is an optical brain monitoring technique which uses near-infrared spectroscopy for the purpose of functional neuroimaging. Using fNIRS, brain activity is measured by using near-infrared light to estimate cortical hemodynamic activity which occurs in response to neural activity. In the aspect of psychiatry fNIRS is a tool that can potentially facilitate the clinical diagnostic process and identify stages of psychiatric illnesses by providing objective and quantifiable evidences of brain changes. However, this will require specific cerebral haemodynamic patterns to be validated in larger clinical populations with specific psychiatric disorders.

Objectives: Our team decided to set a fNIRS system to find out the difference in prefrontocortical (PFC) activity pattern between healthy and anhedonic population. This abstract has been created for introduce our first findings about the difference in PFC activity under emotionally positively or negatively coloured stimuli in healthy population.

Methods: We have measured 5 healthy adults, non-anhedonic participants under emotionally different visual and acoustic stimuli with the use of NIRX/NIRScout system with the view of our prefronto-temporo-parietal montage.

Fig 1 We divided our experimental tools into 4 individual 20 second long parts:

Passive neutral visual or acoustic stimuli for baseline (watching a black dot or silence)

Passive visual stimuli (watching a single picture)

Active visual stimuli (choosing from photo collage) to detect contrast of cortical background activation

Passive acoustic stimuli (listening sounds)

In total, we defined emotionally, two neutral, four positive and four negative stimuli in our experimental setting.

Softwares: We used HOMER3 for analyzing our datas and estimate hemodynamic reponse factor (HRF) using general linear matrix

(GLM) regression. We used *AtlasViewer* for reconstructing HRF image onto the Colin27 digitalised brain model. And we also used SPSS for statistical analysis between stimuli types and HRF means. **Results: Fig 2** Significant HRF differences were measured in the dominant hemisphere dorsolateral prefrontal cortex (DLPFC) between the influence of each emotionally negative and positive stimuli ($p < 0.001$). The level of DLPFC activity was positively influenced by emotionally positive stimuli ($p < 0.001$).

Image:

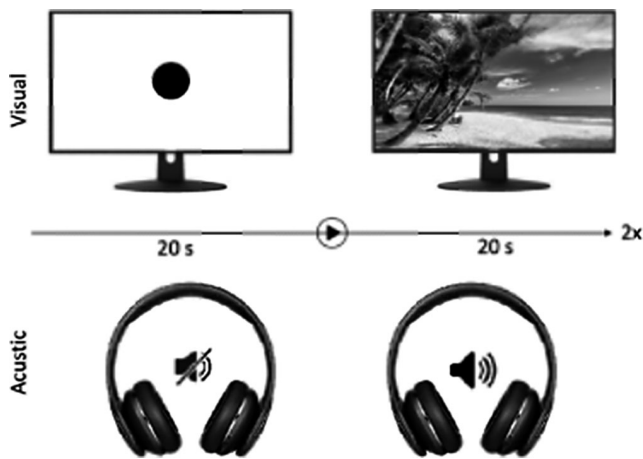


Image 2:

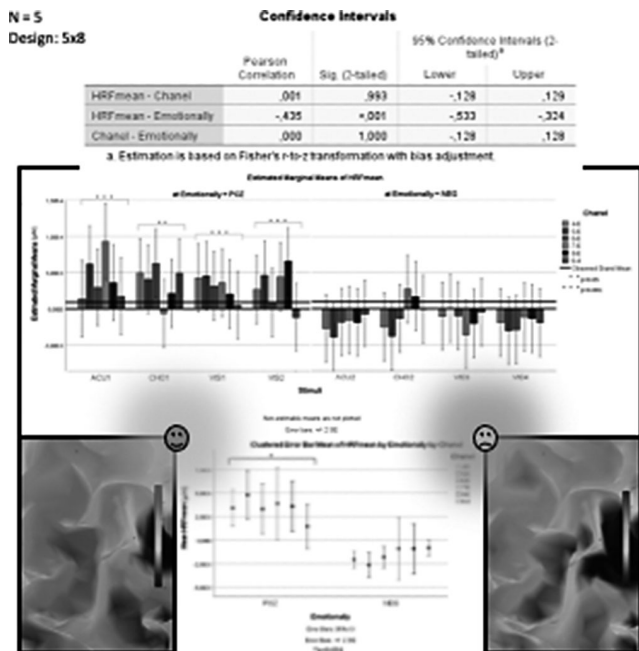
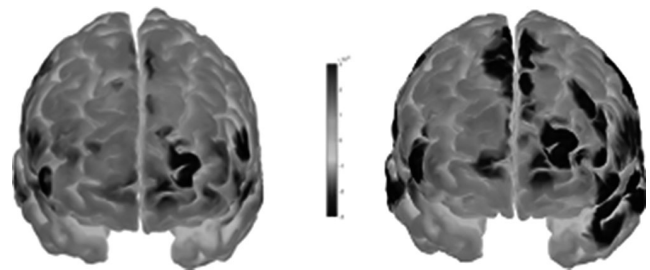


Image 3:



Conclusions: Fig 3 Our fNIRS experimental system is a suitable tool to measure and model the pattern of prefrontal cortical activity. Based on the measured hemodynamic values, we detected a significant activity difference in the dominant hemisphere DLPFC during emotionally positive and negative stimuli, the extent of which is positively influenced by emotionally positive stimuli. The left DLPFC appears to be a promising target for our next studies of anhedonia.

Disclosure of Interest: None Declared

EPV0619

A Machine Learning Model for Predicting Major Depressive Disorder Using Diffusion-Tensor Imaging Data

J. H. Lee* and D.-K. Lee

Department of Mental Health Research, National Center for Mental Health, Seoul, Korea, Republic Of

*Corresponding author.

doi: 10.1192/j.eurpsy.2024.1283

Introduction: Major Depressive Disorder (MDD) stands as a prevalent psychiatric condition within the general population. Despite extensive research efforts, the identification of definitive diagnostic biomarkers for depressive disorders remains elusive. Currently, machine learning methods are gaining prominence in the diagnosis of medical illnesses.

Objectives: This study aims to construct a machine learning-based prediction model for Major Depressive Disorder (MDD) by harnessing diffusion tensor imaging (DTI) data.

Methods: The DTI datasets comprising MDD (N=83) and Healthy Control (N=70) groups were procured from the cohort study of Anxiety and Depression conducted at the National Center for Mental Health in South Korea. A machine learning method using a decision tree algorithm was employed to select relevant brain regions and establish a robust diagnostic model. Features associated with white matter (WM) tracts were chosen through recursive feature elimination.

Results: Demographic characteristics, including age, sex, and handedness, displayed no significant differences between the MDD and Healthy Control groups. However, the total score of the Beck Depression Inventory was notably higher in individuals with MDD compared to Healthy Controls. A diagnostic model