

# Utility of simultaneous triple balloon inflation technique through a single 6-French sheath in treating pulmonary vein stenosis

Bassel Mohammad Nijres  and Osamah Aldoss

Pediatric Cardiology, Stead Family Children's Hospital, University of Iowa, Iowa, IA, USA

## Brief Report

**Cite this article:** Mohammad Nijres B and Aldoss O (2024) Utility of simultaneous triple balloon inflation technique through a single 6-French sheath in treating pulmonary vein stenosis. *Cardiology in the Young* 34: 694–697. doi: [10.1017/S1047951123004511](https://doi.org/10.1017/S1047951123004511)

Received: 10 October 2023

Revised: 9 December 2023

Accepted: 18 December 2023

First published online: 15 January 2024

### Keywords:

Pulmonary vein stenosis; triple kissing balloon; pulmonary vein intervention

### Corresponding author:

Bassel Mohammad Nijres;

Email: [bassel-mohammadnijres@uiowa.edu](mailto:bassel-mohammadnijres@uiowa.edu)

## Abstract

Pulmonary vein stenosis continues to pose significant challenges in children, frequently requiring repeated cardiac catheterisation procedures. This report describes a successful application of a “triple kissing balloon” technique to treat complex pulmonary vein stenosis in two patients, all accomplished with the use of a single 6-French sheath.

## Introduction

Infants with pulmonary vein disease often undergo multiple cardiac catheterisation procedures, including stent placement and balloon angioplasty.<sup>1–4</sup> In practice, one or more pulmonary veins become compressed when adjacent veins are dilated. Interventional cardiologists frequently accept some degree of narrowing in one vein to maintain the patency of others. Although the “triple kissing balloon technique” has been reported in the literature for treating complex coronary artery lesions,<sup>5–7</sup> its application in the context of pulmonary vein stenosis was only described by one of the oral presentations in the 2022 SCAI Scientific Session.<sup>8</sup> Nevertheless, a few programmes likely utilised this technique before.

## Case presentation

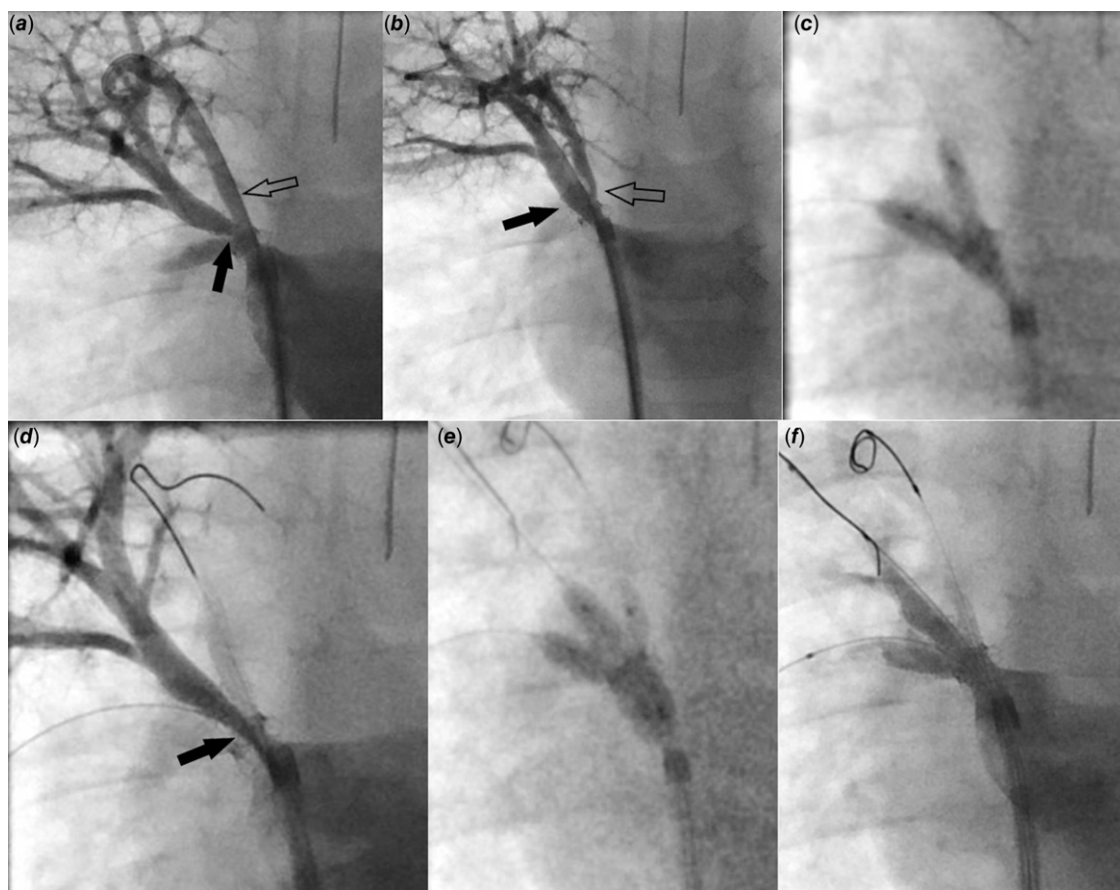
### Case # 1

A 2-year-old male weighing 10.7 kg with a history of prematurity and multivessel pulmonary vein disease presented for repeat pulmonary vein angioplasty. He previously underwent stent placement in the right upper using a 3 × 8 mm Promus Elite stent (Boston Scientific) and at a different date a 4 × 8 mm Synergy stent (Boston Scientific), right middle using a 4 × 8 mm Synergy stent, left upper using a 3.5 × 8 mm Synergy stent, and left lower pulmonary using a 4 × 8 mm Synergy stent. The stent in the right upper pulmonary vein extended inside the apicoposterior segmental vein traversing the take-off of the anterior segment of the right upper and the stented right middle pulmonary veins. The angiogram showed in-stent stenosis with narrowing at the take-off of all three veins [right middle (measured 3.4 mm distally), apicoposterior segmental (measured 3.5 mm distally), and anterior segmental veins (measured 2.2 mm distally)]. All three segments were ballooned separately. However, due to the proximity of all veins, ballooning resulted in compression of whatever segment was not cannulated (Fig. 1*a* and *b*). Through a 6-Fr 35 cm sheath in the right femoral vein, a double kissing ballooning (simultaneous balloon inflation) was performed over 0.014” guide wires in the anterior segment and the right middle pulmonary (Fig. 1*c*). The angiogram showed resolution of the stenosis in the ballooned veins with compression of the apicoposterior segmental vein (Fig. 1*d*). Through the same 6-Fr sheath, a third 0.014” guide wire was placed inside the apicoposterior segment. Subsequently, three monorail Quantum Apex balloons (Boston Scientific) were introduced into the 6-Fr sheath over the 0.014” guide wires, spanning the take-off points of the three segments. These balloons had dimensions of 2.5 × 12 mm for the anterior segmental vein, 3.5 × 12 mm for the apicoposterior segmental vein, and another 3.5 × 12 mm for the right middle vein. All three balloons were simultaneously inflated “triple kissing balloon technique” (Fig. 1*e*). A final angiogram revealed no residual stenosis in all three veins (Fig. 1*f*). The side arm of the sheath was connected to a slow heparinised saline (0.5 IU/ml) flush to prevent bleeding from the valve. At 6 months follow-up cardiac catheterisation, all segments were ballooned again using the same technique.

### Case # 2

An 11-month-old male weighing 5.9 kg presented for a scheduled cardiac catheterisation surveillance. He was born with a truncus arteriosus with an interrupted aortic arch (Van Praagh type A4) that was surgically repaired on the 10<sup>th</sup> day of his life. Additionally, at the age of

© The Author(s), 2024. Published by Cambridge University Press. This is an Open Access article, distributed under the terms of the Creative Commons Attribution licence (<http://creativecommons.org/licenses/by/4.0/>), which permits unrestricted re-use, distribution and reproduction, provided the original article is properly cited.



**Figure 1.** (a) Cine image shows narrowing in the proximal apicoposterior segmental vein (solid arrow) after balloon angioplasty of the anterior segmental vein (empty arrow) of the right upper pulmonary vein. (b) Cine image shows narrowing at the anterior segmental vein (empty arrow) after ballooning the apicoposterior segmental vein (solid arrow) of the right upper pulmonary vein. (c) Saved fluoroscopy cine image shows the double kissing balloon technique applied to the anterior segmental vein and the right middle pulmonary vein. (d) Cine image shows worsening narrowing in the proximal apicoposterior segmental vein (solid arrow) after simultaneous balloon inflation in the anterior segmental vein and the right middle vein. (e) Saved fluoroscopy image shows simultaneous triple balloon inflation in the apicoposterior segmental vein, anterior segmental vein, and right middle vein. (f) Cine images after simultaneous three balloon inflation show all three veins wide open with no localised stenosis.

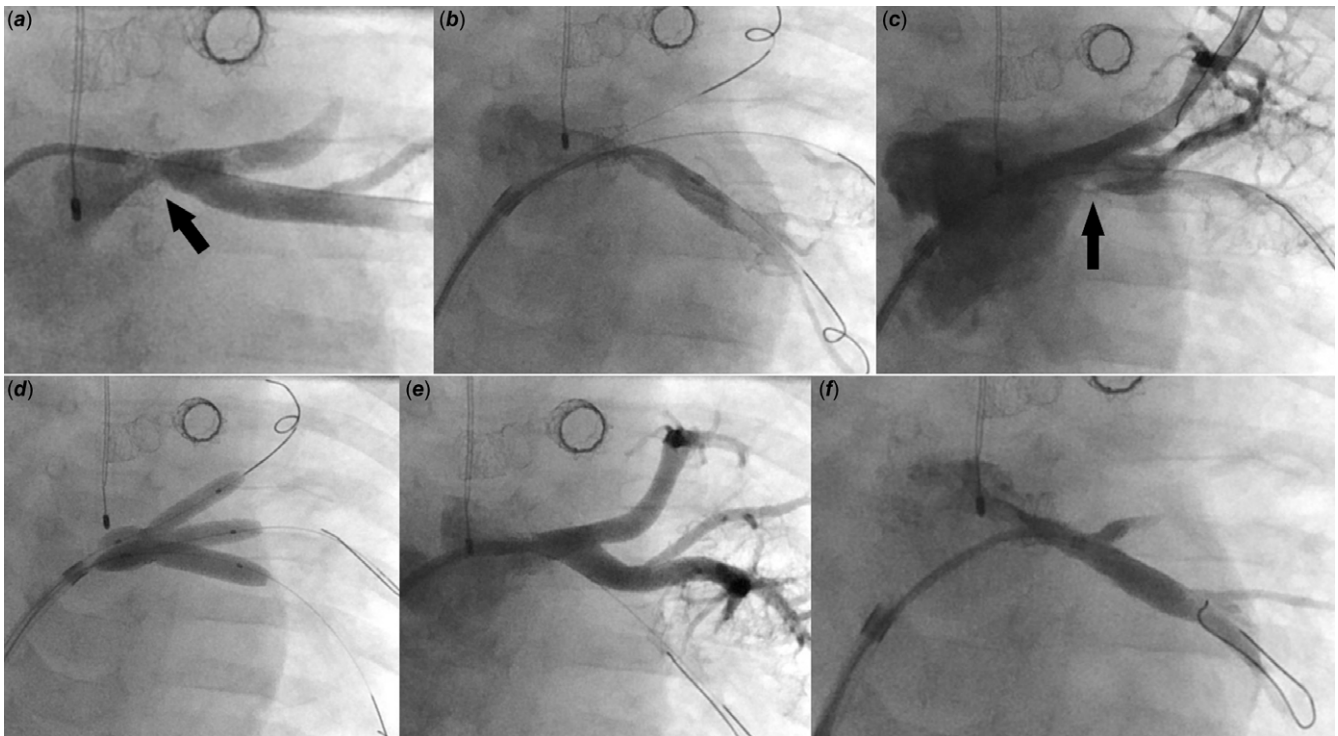
3 months, he developed severe left common pulmonary vein stenosis, which was effectively treated with the placement of a  $4 \times 8$  mm Synergy stent. A baseline angiogram showed complete occlusion of the left lower pulmonary vein with severe in-stent stenosis in the distal inferior aspect of the stent (Fig. 2a). Mild narrowing was also observed in the lingula and the left upper pulmonary veins. The occluded vein was recanalised using a chronic occlusion wire and balloon angioplasty was performed with no residual narrowing (Fig. 2b). Balloon angioplasties were individually carried out on the left upper (measured 4 mm distally), left lower (measured 4.2 mm distally), and lingula (measured 4 mm distally) veins. It was noticed that the narrowing resolved in whatever individually ballooned vein and worsened in the others (Fig. 2c). As such, the triple kissing balloon technique was utilised as described in the first case through a single 6-French 35 cm sheath over 0.014" guide wires using monorail NC quantum apex balloons (Fig. 2d). Balloon sizes were  $3.5 \times 20$  mm in the left upper,  $4.5 \times 20$  mm in the left lower, and  $4 \times 20$  mm in the lingula veins. Again, the side arm of the sheath was kept on a slow heparinised saline (0.5 IU/ml) flush. The final angiogram showed all three veins are wide open with no localised stenosis (Fig. 2e and f).

At 5 months of follow-up cardiac catheterisation, the left upper, lingula, and left lower pulmonary veins were ballooned again using the same technique.

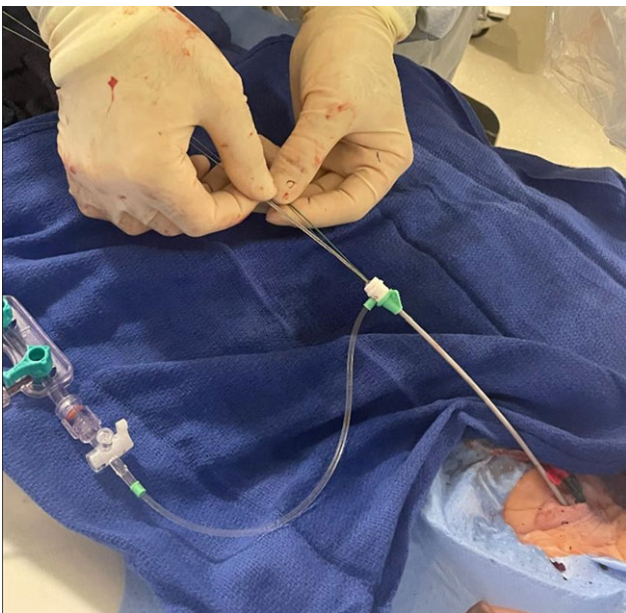## Discussion

Until recently, multivessel pulmonary vein disease was often deemed fatal, and many medical centres considered it untreatable.<sup>9-11</sup> However, over the past decade, a combination of new medical treatments and innovative transcatheter and surgical interventions has brought about substantial improvements in survival rates. Pessimism has given way to optimism in the management of this condition.<sup>1-4</sup>

While trifurcation pulmonary vein lesions are frequently encountered in clinical practice, there is a lack of literature describing their treatment. Most published research primarily focuses on individual pulmonary veins, without addressing lobar or segmental vein involvement.<sup>1-4</sup> Treating trifurcation lesions presents greater challenges in preserving the patency of each segmental or lobar vein's ostium. Interventional cardiologists often face the dilemma of sacrificing patency in one segment to maintain it in the larger ones. The triple kissing balloon technique, initially designed for treating trifurcation left main coronary artery lesions, has not been investigated for pulmonary vein application lesions.<sup>5-7</sup> However, when 0.014" guide wires are employed for trifurcation coronary artery lesions, it typically necessitates the use of a large 9-French guide catheter. In smaller children, utilising a 9-French sheath can be challenging due to their petite anatomy. In this



**Figure 2.** (a) Cine image shows occlusion of the left lower pulmonary vein and in-stent stenosis (solid arrow). (b) Cine image shows the left lower pulmonary vein with good size after recanalisation and balloon angioplasty. (c) Cine image shows iatrogenic narrowing in the left lower vein (solid arrow) after ballooning the lingula vein. (d) Cine image shows simultaneous three balloon inflation “triple kissing balloon technique.” (e and f) Cine images after simultaneous three balloon inflation show all three veins wide open with no localised stenosis.



**Figure 3.** Image shows the 3 balloons are controlled with one hand, and the three wires are controlled with the other hand. Notice the side arm of the sheath is connected to a slow heparinised saline flush to prevent bleeding from the valve.

report, the triple kissing balloon technique was successfully employed a few times in two patients without any complications associated with the procedure.

A few technical points are worth mentioning:

1. Use monorail balloons as they allow controlling all balloons in one hand and all wires with the other hand (Fig. 3).
2. Since three balloons and three wires pass through the sheath valve, there is a potential for blood loss from the valve. This issue can be addressed by connecting the side arm of the sheath to a slow flush (until slow dripping of clear heparinised saline is observed from the valve) (Fig. 3).
3. Although this was not encountered, the wires may become entangled inside the sheath. If it occurs, interventionalists can pull all wires outside the body and reposition them.

It is worth mentioning that, as expected with ballooning coronary stent, we observed that the stent diameters were increased at the expense of foreshortening. In the future, when the stents reach their maximum potential diameter, they will be intentionally fractured using ultrahigh-pressure balloons.<sup>1</sup>

### Conclusion

When appropriate equipment is selected, a triple kissing balloon technique can be employed with a small-bore sheath, specifically a 6-French sheath. While this technique holds promise as a valuable approach for addressing trifurcation pulmonary vein lesions, its ability to effectively maintain the long-term patency of all branches is yet to be learned.

**Competing interests.** The authors declare that there is no conflict of interest.

**Research involving human participants.** All procedures performed in studies involving human participants were in accordance with the ethical standards of the institutional and/or national research committee and with the 1964 Helsinki Declaration and its later amendments or comparable ethical standards.

**Informed consent.** As our case report does not meet the definition of research, it is not subject to Institutional Review Board oversight as per the University of Iowa Institutional Review Board. As such informed consent was not obtained from the individual participant included in the case report.

## References

1. Khan A, Qureshi AM, Justino H. Comparison of drug eluting versus bare metal stents for pulmonary vein stenosis in childhood. *Catheter Cardiovasc Interv* 2019; 94: 233–242.
2. Aggarwal V, Stapleton GE, Eilers LF, et al. Pulmonary vein atresia: feasibility of initial recanalization attempts with subsequent follow-up. *Curr Probl Cardiol* 2023; 48: 101463.
3. Patel JD, Mandhani M, Gray R, et al. Transcatheter recanalization of atretic pulmonary veins in infants and children. *Circ Cardiovasc Interv* 2022; 15: e011351.
4. Callahan R, Esch JJ, Wang G, Ireland CM, Gauvreau K, Jenkins KJ. Systemic sirolimus to prevent in-stent stenosis in pediatric pulmonary vein stenosis. *Pediatr Cardiol* 2020; 41: 282–289.
5. Lindsey RL, Saporito J, Kleist PC, Kalash Y. Triple balloon-on-a-wire or “ménage à trois” coronary angioplasty. *Cathet Cardiovasc Diagn* 1993; 28: 76–79.
6. Cusco JA, Delehanty JM, Ling FS. Trifurcation triple balloon angioplasty in a dual left anterior descending coronary artery: the “Ménage à trois” revisited. *Cathet Cardiovasc Diagn* 1996; 38: 214–217.
7. El-Jack SS, Pornratanarangi S, Ormiston JA, Webster MW. Stenting coronary trifurcation lesions: is “ménage à trois” the solution? *Catheter Cardiovasc Interv* 2006; 67: 372–376.
8. O'Halloran C, Fox J, Tannous P, Nugen AW. Simultaneous triple balloon angioplasty to maintain patency of all lobes and segments in severe pulmonary vein stenosis. In: Oral presentation at SCAI. 2022 Scientific Session 2022.
9. Driscoll DJ, Hesslein PS, Mullins CE. Congenital stenosis of individual pulmonary veins: clinical spectrum and unsuccessful treatment by transvenous balloon dilation. *Am J Cardiol* 1982; 49: 1767–1772.
10. Shuhaiber J, Rehman M, Jenkins K, Fynn-Thompson F, Bacha E. The role of surgical therapy for pulmonary vein atresia in childhood. *Pediatr Cardiol* 2011; 32: 639–645.
11. Pourmoghadam KK, Moore JW, Khan M, et al. Congenital unilateral pulmonary venous atresia: definitive diagnosis and treatment. *Pediatr Cardiol* 2003; 24: 73–79.