

Primary Spontaneous Mesencephalic Hemorrhage

Mark F. Mehler and Philip S. Ragone

ABSTRACT: The case histories of two patients with clinically diverse forms of the very rare entity primary, spontaneous mesencephalic hemorrhage are presented. Each exhibited characteristic mesencephalic signs and neuroimaging profiles. However, both patients differed markedly in their predisposing factors, state of arousal, memory, temporal course and functional residua. One patient was unique in displaying a normal level of alertness throughout his clinical course and an isolated retrograde amnesia. The latter sign suggests a role for mesencephalic reticular activation in long-term retrieval and illustrates the differential effects of a subtle activation deficit on memory and arousal. These findings broaden the distinctive clinico-anatomical profile of primary, spontaneous mesencephalic hemorrhage.

RÉSUMÉ: Hémorragie mésencéphalique spontanée primaire Nous présentons les histoires de cas de deux patients atteints de formes cliniques différentes d'une entité rare, l'hémorragie mésencéphalique primaire spontanée. Chacun d'eux présentait des signes mésencéphaliques et un profil neuro-radiologique caractéristiques. Cependant, les deux patients différaient grandement en ce qui concerne les facteurs prédisposants, l'état de veille, la mémoire, l'évolution dans le temps et la fonction résiduelle. Un patient était particulier en ce qu'il avait conservé un niveau de vigilance normal pendant toute son évolution clinique et une amnésie rétrograde isolée. La présence de ce dernier signe suggère que l'activation de la formation réticulée mésencéphalique joue un rôle dans la mémoire à long terme et illustre les effets différentiels d'un déficit d'activation subtil sur la mémoire et la vigilance. Ces observations élargissent le profil clinico-anatomique distinctif de l'hémorragie mésencéphalique spontanée.

Can. J. Neurol. Sci. 1988; 15: 435-438

Non-traumatic, spontaneous primary mesencephalic hemorrhage is extremely rare. Of the few reported cases to date, most were associated with blood dyscrasias, vascular malformations or hypertension.¹⁻⁶ Hemorrhage into the midbrain has also been seen in a small group of normotensive patients with negative angiograms and normal laboratory studies.⁷ In addition, a more clinically benign form of non-aneurysmal subarachnoid hemorrhage with a perimesencephalic focus has been described.⁸ We present two contrasting examples of primary mesencephalic hemorrhage which expand the clinical spectrum and illustrate the broad range of presenting signs and evolving clinical scenarios. The clinico-anatomical findings are distinctive when compared to thalamic, pontine and analogous intraparenchymal hemorrhages.

CASE HISTORY

Patient 1

A 48 year old right-handed normotensive man noted the gradual onset of complete blindness which lasted for two hours and then quickly resolved. This was associated with generalized throbbing headache

and unsteady gait and later (within one hour) with slurred speech and right eyelid droop. At this later stage the patient noted the occurrence of a total personal amnesia for all events extending back 12-15 years. He had a history of extensive alcohol abuse for many years (two pints of whiskey per day for 20 years) and a bout of severe bleeding from esophageal varices one month prior to admission. These facts were supplied by family members. Admission neurological examination revealed the patient to be alert and fully oriented with a precise isolated retrograde amnesia which was temporally limited (Table 1). There was a remarkable dissociation between tests of recent memory (Wechsler Memory Scale and Buschke/Fuld Selective Reminding Tests)⁹ and those of remote memory (Boston Retrograde Amnesia Battery).¹⁰ He had a corrected visual acuity of 20/200 bilaterally with no field deficits, mild right-sided ptosis, small pupils bilaterally with sluggish light response on the right side, intermittently dysconjugate horizontal eye movements, convergence-retraction nystagmus, direction-changing nystagmus on lateral gaze with an eccentric null point on the right, poor voluntary and induced reflex vertical gaze, skew deviation, mild left arm drift, bilateral increased tone with increased deep tendon reflexes, impaired left-sided coordination and rapid alternating movements and wide-based gait with falling to the left. Brain computed tomography (CT) revealed a right-sided mesencephalic hemorrhage (Figure 1), intra-ventricular and posterior thalamic extension and the absence of additional parenchymal damage. Laboratory examination showed a prothrombin time of 13.9/11.2, a partial thromboplastin time of 51.5/28.6

From the Saul R. Korey Department of Neurology, Albert Einstein College of Medicine, Bronx, New York, U.S.A. and the Neurological Services, Bronx Municipal Hospital Center, Montefiore Hospital Medical Center and J.D. Weiler Hospital of the Albert Einstein College of Medicine

Received March 3, 1988. Accepted May 24, 1988

Reprint requests to: Dr. M.F. Mehler, Department of Neurology (F, G-9), Albert Einstein College of Medicine, 1300 Morris Park Avenue, Bronx, New York, U.S.A. 10461

Table 1: Performance of Patient One on Standardized Memory and Associated Tests

Task	Percentage of Maximal Score	
	Day 1	Day 9
General Knowledge Battery		
Visual recognition	72.5	76.8
Verbal recognition	82.7	83.5
Verbal recall	84.7	86.0
Wechsler Memory Scale		
Total score	79.6	84.4
Boston Retrograde Amnesia		
Recognition	38.6	77.5
Recall	25.5	74.3
Famous faces	29.8	83.6
Buschke/Fuld Selective Reminding		
Total recall	93.0	92.8
Long-term storage	87.5	88.7
Long-term retrieval	79.4	80.5
Consistent long-term retrieval	75.7	76.1

and a platelet count of 195,000. He was given vitamin K and multiple units of fresh frozen plasma with partial correction of his coagulopathy. He showed rapid clinical improvement. Cerebral angiography showed no vascular abnormalities. After five days, his only neurological abnormality, of note, was continued impairment of vertical gaze which persisted unabated.

Patient 2

A 36 year old right-handed hypertensive man experienced the sudden inability to open both his eyes while showering one morning associated with generalized headache and dizziness. Later he noted left-sided numbness of his body and progressive sleepiness. The preceding day he had a similar episode of sudden inability to open his right eye after showering. He had a history of hypertension controlled with captopril 25 mg twice daily. On admission, he had a blood pressure of 180/110 with no signs of meningeal irritation or respiratory abnormalities. He was lethargic but intermittently arousable to voice and occasionally

uttered garbled responses to simple questions. There was early papilledema bilaterally with dilated, unreactive right pupil and small, poorly reactive left pupil. He showed decreased spontaneous and elicited movements of his left side with external rotation of the left leg and extensor plantar response. He was intubated, hyperventilated and given mannitol. CT scan revealed mesencephalic hemorrhage with generalized intraventricular hemorrhage and hydrocephalus (Figure 2a). Laboratory examination was completely normal. A right ventriculostomy was placed (Figure 2b). The cerebrospinal fluid was clear and hemorrhagic with a normal opening pressure. Cerebral angiography showed no abnormalities. The patient slowly improved over the course of several months. The baseline neurological examination now shows him to be mildly lethargic but fully oriented and communicative when aroused. There is a complete right oculomotor nerve palsy, contralateral ptosis, impaired left lateral gaze, bilateral vertical gaze deficits, left central facial paresis and moderate left leg paresis with extensor plantar response.

DISCUSSION

The previously reported cases of primary mesencephalic hemorrhage have displayed a constellation of clinical (Table 2) and neuroimaging findings.¹⁻⁸ The format of the individual case presentations in the literature precludes strict comparative analysis of presenting signs and temporal profiles. The two present patients share a number of distinctive features which help to shape a characteristic clinical and anatomical profile. Severe headache preceded the ictus in both cases but neither individual had nausea or emesis. There were no meningeal signs, neck pain or traumatic associations despite the presence of intraventricular extension in each case and signs of increased intracranial pressure in at least one patient. Both had unequal poorly reactive pupils, ptosis, light-near dissociation and elements of Weber's syndrome (crossed third nerve palsy and hemiparesis). In the recovery phase, each subject had persistent vertical gaze impairment. Both cases demonstrated mesencephalic tegmental

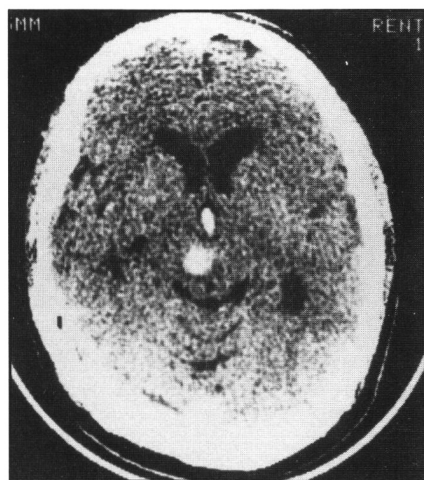


Figure 1 — Admission CT scan of patient 1 showing right-sided mesencephalic tegmental hemorrhage, intraventricular hemorrhage and dilated lateral ventricles. Additional sections and scans on subsequent days revealed significant intraventricular hemorrhage and quadrigeminal plate cisternal involvement, respectively.

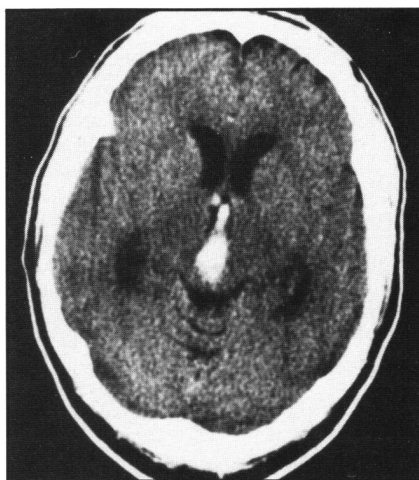


Figure 2a — Admission CT scan of patient 2 showing mesencephalic tegmental hemorrhage, intraventricular hemorrhage and dilated lateral ventricles. Additional sections and scans on subsequent days revealed significant intraventricular hemorrhage and quadrigeminal plate cisternal involvement, respectively.

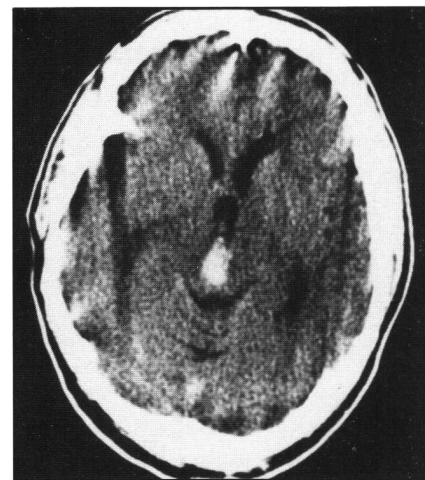


Figure 2b — CT scan of patient 2 after placement of a right-sided ventriculostomy, showing significant reduction in ventricular size.

Table 2: Clinical Signs in Mesencephalic Hemorrhage

prodromal emesis
confusion
lethargy/obundation/coma
clear sensorium*
retrograde amnesia*
head tilt*
Weber's syndrome
Benedikt's syndrome
Horner's syndrome
Oculomotor nerve palsies
Trochlear nerve palsies
Abducens nerve palsies
Unequal, poorly reactive pupils
Parinaud's syndrome
hemiparesis
hyper-reflexia/Babinski signs
hemisensory deficits
intention tremor
limb incoordination/dysmetria
gait ataxia

*newly-described in the present article (patient one).

hemorrhage with intraventricular extension, involvement of the quadrigeminal cisterns, and absence of parenchymal contrast enhancement or pontine extension on serial CT scans. Negative angiograms were obtained from each individual.

Patient one demonstrates several unusual and potentially crucial diagnostic features. The initial clinical symptoms (blindness and gait instability) suggested early rostral basilar ischemia with unusually rapid subjective visual recovery.^{11,12} The patient's long history of alcohol abuse and persistent coagulopathy may well have created the predisposing condition for bleeding into an area of relative ischemia in the midbrain. Although no mesencephalic symptoms were initially noted, right ptosis did develop within one hour. A large number of mesencephalic signs were seen on neurological examination, including elements of the dorsal midbrain syndrome of Parinaud¹³ (impaired upgaze, convergence-retraction nystagmus, light-near dissociation and, possibly, skew deviation), and left head tilt, due to involvement of the contralateral interstitial nucleus of Cajal.¹⁴ The patient also noted the delayed onset and experimentally verified occurrence of a very unusual and relatively isolated, temporally-limited retrograde amnesia which has been implicated in a rare mesencephalic disconnection syndrome in which mesencephalic reticular activation may function in the process of long-term retrieval.¹⁵ In addition, he is the only patient yet described to display a normal state of consciousness throughout his clinical course. In fact, the findings suggest that this isolated retrograde mnemonic deficit may be a much more common accompaniment of mesencephalic dysfunction, but one that can only be documented in the absence of an impairment of overall arousal. His generalized hypertonicity and exaggerated deep tendon reflexes may have been the only other clue to the real extent of hemorrhagic involvement. There was evidence of posterior thalamic extension on CT, which has previously been described,⁷ despite the absence of discrete clinical signs. In addition, in the mesencephalon, the hemorrhage was relatively discrete and localized to the right lateral tegmental region (Figure 1).

By contrast, the second patient displayed a completely different clinical profile. He was much younger (36 years) and had a significant past history of hypertension. His prodromal phase was longer and the initial clinical manifestations implicated the central caudal nucleus of the oculomotor nerve complex in the midbrain (bilateral ptosis).¹⁶ Progressive obtundation ensued in association with signs of increased intracranial pressure and hydrocephalus. Therapeutic intervention with antiedema agents and ventriculostomy did little to reverse the clinical trend. He has been left with significant residual impairment of arousal, vertical gaze, pupillary reactivity and extraocular muscle and motor functioning. Analysis of the CT scan images in this case (Figure 2), suggests that the mesencephalic tegmental hemorrhage was considerably larger, affecting more midline and dorsal anatomical landmarks. Also, the early occurrence of bilateral papilledema, incipient uncal herniation (dilated, unreactive right pupil), and altered mentation confirms the impression that the raised intracranial pressure was exerting a profound clinical effect. Thus, despite the occurrence of both intraventricular hemorrhage and posterior thalamic extension in patient one, the presence of clinically significant raised intracranial pressure and greater mesencephalic parenchymal involvement may well have been responsible for the more severe neurological signs and less favorable clinical outcome in patient two.

The present cases and review of the literature indicate that primary mesencephalic hemorrhage is a distinct clinicopathological entity with a wide clinical and etiological spectrum. It differs from primary thalamic, pontine and associated intraparenchymal hemorrhages by a number of phenomenological, prognostic and neuroimaging features.¹⁷ In primary thalamic hemorrhage, hemipareses and hemisensory abnormalities predominate, pupils are small and poorly reactive and vertical eye movements may be impaired. With primary pontine hemorrhage, coma usually supervenes with respiratory impairment, quadriplegia, miotic but reactive pupils and absence of spontaneous and induced horizontal eye movements.

Prognosis is especially poor with pontine hemorrhage.¹⁷ In thalamic hemorrhage the recovery potential is intermediate but shows a bimodal distribution.¹⁸⁻²¹ Hematomas with a diameter greater than 3.3 cm on CT scan tend to be fatal, while those less than 2.7 cm are usually associated with clinical recovery, though often with residual neurological deficits. The level of consciousness on admission and the occurrence of hydrocephalus are important additional prognostic variables. Of the three locations for intraparenchymal hemorrhage, the mesencephalon is associated with the best potential for useful survival.^{7,22} Most patients recover and many return to an independent existence with minimal neurological residua. However in a sizable fraction of affected individuals, diversionary shunting or hematoma evacuation were necessary during the acute clinical phase of the illness. Recovery may be most favorable in normotensive patients⁷ and in a related clinical entity with a primary perimesencephalic hemorrhagic focus.⁸ The diagnosis should be considered in the premonitory or secondary phase of any neurovascular illness in which mesencephalic signs and even subtle evidence of raised intracranial pressure are present. When such cases are confirmed by screening neuroimaging studies, an immediate inquiry into potentially remediable, occult predisposing factors should be undertaken.

ACKNOWLEDGEMENTS

Supported by a Teacher-Investigator Development Award (NS00856) to M.F.M. from the National Institute of Neurological and Communicative Disorders and Stroke, National Institutes of Health, U.S.A.

The authors are grateful to Ms. Donna Platyan and Ms. Carmela Fucci for their skill and intelligence in the preparation of this manuscript.

REFERENCES

1. Durward QJ, Barnett HJM, Barr HWK. Presentation and management of mesencephalic hematoma. *J Neurosurg* 1982; 56: 123-127.
2. Humphreys RP. Computerized tomographic definition of mesencephalic hematoma with evacuation through pedunculotomy. *J Neurosurg* 1978; 49: 749-752.
3. LaTorre E, Delitala A, Sorano V. Hematoma of the quadrigeminal plate. *J Neurosurg* 1978; 49: 610-613.
4. Morel-Maroger A, Metzger J, Bories J, et al. Les hématomes bénins du tronc cérébral chez les hypertendus artériels. *Rev Neurol (Paris)* 1982; 138: 437-445.
5. Roig C, Carvajal A, Illa I, et al. Hémorragies mesencéphaliques isolées. Trois cas diagnostiques par tomодensitométrie. *Rev Neurol (Paris)* 1982; 138: 53-61.
6. Scoville WB, Poppen JL. Intrapuduncular hemorrhage of the brain. *Arch Neurol Psychiatry* 1949; 61: 688-694.
7. Weisberg LA. Mesencephalic hemorrhages: clinical and computed tomographic correlations. *Neurology* 1986; 36: 713-716.
8. van Gijn J, van Dongen KJ, Vermuelen M, et al. Perimesencephalic hemorrhage: A nonaneurysmal and benign form of subarachnoid hemorrhage. *Neurology* 1985; 35: 493-497.
9. Buschke H, Fuld PA. Evaluating storage, retention and retrieval in disordered memory and learning. *Neurology* 1974; 24: 1019-1024.
10. Albert MS, Butters N, Levin J. Temporal gradient in the retrograde amnesia of patients with alcoholic Korsakoff's disease. *Arch Neurol* 1979; 36: 211-216.
11. Caplan LR. "Top of the basilar" syndrome. *Neurology* 1980; 30: 72-79.
12. Mehler MF. Reversible rostral basilar artery syndrome. *Arch Int Med* 1988; 148: 166-169.
13. Miller NR. Walsh and Hoyt's Clinical Neuro-ophthalmology, Vol. 2. Baltimore: Williams and Wilkins, 1985; 716-719.
14. Brandt T, Dieterich M. Pathological eye-head coordination in roll: Tonic ocular tilt reaction in mesencephalic and medullary lesions. *Brain* 1987; 110: 649-666.
15. Goldberg E, Antin S, Bilder RM, et al. Retrograde amnesia: Possible role of mesencephalic reticular activation in long-term memory. *Science* 1981; 213: 1392-1394.
16. Bogousslavsky J, Meienberg O. Eye-movement disorders in brainstem and cerebellar stroke. *Arch Neurol* 1987; 44: 141-148.
17. Plum F, Posner JB. The diagnosis of stupor and coma. Philadelphia: F.A. Davis and Co, 1980; 167.
18. Barraquer-Bordas L, Illa I, Escartin A, et al. Thalamic hemorrhage: A study of 23 patients with a diagnosis by computed tomography. *Stroke* 1981; 12: 524-527.
19. Kwak R, Kadoya S, Suzuki T. Factors affecting prognosis in thalamic hemorrhage. *Stroke* 1983; 14: 493-500.
20. Piepgras U, Rieger P. Thalamic bleeding: diagnosis, course, prognosis. *Neuroradiology* 1981; 22: 85-91.
21. Walshe TM, David KR, Fisher CM. Thalamic hemorrhage: A computed tomographic-clinical correlation. *Neurology* 1977; 27: 217-222.
22. Lhermitte J. Les hémorragies des pédoncules cérébraux: étude clinique. *Presse Med* 1942; 45: 625-626.