

## Letter to the Editor: New Observation

# Auditory Agnosia in Autoimmune Encephalitis

Kristin Walters<sup>1</sup>, Paolo Federico<sup>2</sup>  and Christopher Hahn<sup>2</sup> 

<sup>1</sup>Department of Family Medicine, University of Calgary, Calgary, Alberta, Canada and <sup>2</sup>Department of Clinical Neurosciences, University of Calgary, Calgary, Alberta, Canada

**Keywords:** Autoimmune disease; Auditory neuroscience; Language disorders; Neuroimmunology

Autoimmune encephalitis (AIE) is an increasingly recognized cause of acute encephalopathy, commonly accompanied by seizures and other neurologic symptoms and signs. Despite a predilection for mesial temporal structures and occasionally the thalami, hearing loss and other auditory symptoms are not commonly reported. Herein, we report a case of possible Contactin-associated protein-like 2 (CASPR2) related AIE resulting in chronic auditory agnosia.

A 21-year-old woman presented to the hospital with 3–4 days of confusion and fever followed by new onset generalized tonic-clonic seizures. Due to refractory seizure activity, she was intubated in the emergency room with subsequent transfer to the critical care unit. Cerebrospinal fluid (CSF) studies showed a lymphocytic pleocytosis with a white cell count of  $146 \times 10^6$  (reference range  $0-5 \times 10^6$ ) and elevated protein at 1.32 g/L (reference range 0.15–0.45 g/L) with negative infectious work-up (see Table 1). Serum and CSF testing for encephalitis and paraneoplastic antibodies showed positive CASPR2 antibodies in the serum only (cell-based assay without confirmatory tissue-based assay, 1:100 dilution, Mitogen Diagnostics). Continuous EEG showed focal electrographic seizures and epileptiform discharges arising from bilateral occipital regions (Figure 1a). Initial MRI demonstrated increased T2/FLAIR signal in the medial thalami bilaterally without enhancement (Figure 1b). Her extended work-up was otherwise unremarkable (see Table 1).

Based on the clinical phenotype, CSF findings and lack of other etiology, a diagnosis of possible AIE was made. Initial treatment consisted of intravenous immunoglobulin (2 g/kg over 5 days) and intravenous methylprednisolone (1 g daily for 5 days). However, due to persistent refractory seizures with weaning of sedation and ongoing encephalopathy, her treatment was escalated to plasmapheresis (five exchanges over 10 days) followed by rituximab (1000 mg IV for two doses, 2 weeks apart). She was extubated and transitioned to oral anti-epileptics 4 days after her first dose of rituximab and 1 day after completion of apheresis. She had no further witnessed seizures and demonstrated slow improvement in cognition over the remainder of her hospitalization. A PET scan of the brain done 2 months after admission demonstrated marked hypometabolism of the anterior left thalamus and moderate hypometabolism of both caudate nuclei. There was patchy mild hypometabolism in the temporal lobes (predominantly hippocampal regions and mesial temporal

**Table 1:** Additional testing done at initial work-up

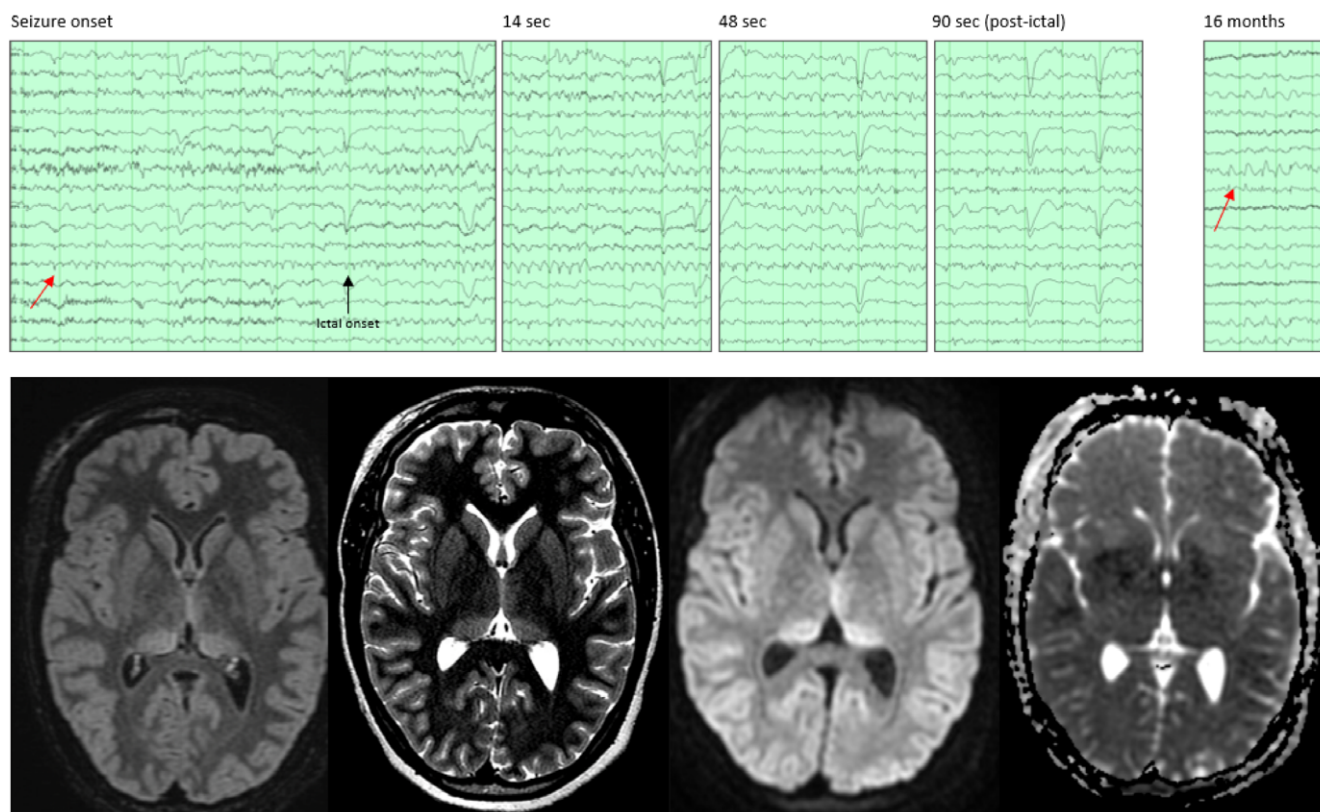
CSF – infectious tests	
Gram stain and bacterial culture	Negative
HSV, VZV PCR	Negative
Viral NAT testing: Enterovirus RNA, Paechovirus RNA, CMV DNA, EBV DNA, WNV DNA	Negative
Cryptococcal antigen	Negative
Oligoclonal bands and IgG index	Not done
CSF/serum – antibody tests	
NMDA, GABA-B, AMPA, DPPX, LGI1, GAD65	Negative
Amphiphysin, PNMA2(Ma2/Ta), CV2.1, Ri, Recoverin, SOX1, Titin, Yo and Hu	Negative
Serum – infectious tests	
Routine blood cultures	Negative
HIV serology, hepatitis B/C serology	Negative
Treponemal testing (RPR, specific treponemal test)	Negative
Quantitative interferon gamma assay (tuberculosis)	Negative
Serum – autoimmune testing	
ENA panel, ANA, dsDNA	Negative
Imaging	
CT chest abdomen and pelvis	No evidence of malignancy
Pelvic US	Complex ovarian cyst. Resolved on follow-up imaging 8 months later
Whole-body FDG PET	No evidence of malignancy

CSF = cerebrospinal fluid; HSV = herpes simplex virus; VZV = varicella zoster virus; PCR = polymerase chain reaction; NAT = nucleic acid testing; RNA = ribonucleic acid; DNA = deoxyribonucleic acid; CMV = Cytomegalovirus; EBV = Epstein-Barr virus; WNV = West Nile Virus; NMDA = N-methyl-D-aspartate; GABA = gamma-aminobutyric acid; AMPA =  $\alpha$ -amino-3-hydroxy-5-methyl-4-isoxazolepropionic acid; DPPX = dipeptidyl-peptidase-like protein 6; LGI1 = leucine-rich, glioma inactivated 1; GAD = glutamate decarboxylase; PNMA2 = Paraneoplastic antigen Ma2; HIV = human immunodeficiency virus; RPR = rapid plasma reagent; ENA = extended nuclear antigen; ANA = anti-nuclear antibodies; dsDNA = double-stranded DNA; CT = computed tomography; US = ultrasound; FDG PET = fluorodeoxyglucose positron emission tomography.

**Corresponding author:** Christopher Hahn, MD FRCPC, Department of Clinical Neurosciences, University of Calgary, 4448 Front Street SE, 4<sup>th</sup> Floor Administration, South Health Campus, Calgary, Alberta, T3M 1M4, Canada. Email: [christopher.hahn@ahs.ca](mailto:christopher.hahn@ahs.ca)

**Cite this article:** Walters K, Federico P, and Hahn C. (2023) Auditory Agnosia in Autoimmune Encephalitis. *The Canadian Journal of Neurological Sciences* 50: 784–786, <https://doi.org/10.1017/cjn.2022.284>

© The Author(s), 2022. Published by Cambridge University Press on behalf of Canadian Neurological Sciences Federation. This is an Open Access article, distributed under the terms of the Creative Commons Attribution licence (<http://creativecommons.org/licenses/by/4.0/>), which permits unrestricted re-use, distribution and reproduction, provided the original article is properly cited.



**Figure 1:** EEG and MR findings. (A) (Top panels) Electrographic seizure and follow-up EEG. Prior to ictal onset, abundant low voltage spikes are seen in the left occipital region (O1). At ictal onset (black arrow) O1 spikes become repetitive and rhythmic 3–4 Hz delta and theta are seen in both posterior quadrants. This ictal rhythm evolves to 3 Hz more in the left hemisphere until the seizure ends after 82 sec. A follow-up EEG obtained 16 months later shows abundant left and right interictal epileptiform discharges, including over the right temporo-occipital region. (B) (Bottom panels) Axial FLAIR MRI (far left) and T2 (centre left), DWI (centre right), and ADC (far right) MR images showing bilateral hyperintensities in both posterior medial thalami without diffusion restriction. EEG = electroencephalogram; FLAIR = Fluid attenuation inversion recovery; DWI = Diffusion-weighted image; ADC = apparent diffusion coefficient; MRI = magnetic resonance imaging.

structures), the left orbital frontal region, and the lateral associative cortex of the occipital lobes. No areas of hypermetabolism were seen.

Neurologic exam 6 months after initial presentation demonstrated absent comprehension of speech, impaired repetition and naming difficulty with low-frequency objects but fluent speech. Reading and writing abilities remained intact. She was dependent on voice to text transcription software for all communication. She was inconsistent in her ability to identify environmental sounds; for example, she correctly identified the sound of a car and a knock on the door but could not identify a bird singing or a car horn. Interestingly she did report hearing the sounds and could mimic them. She reported no longer enjoying music as she could not discern any melody. The remainder of her neurologic exam was grossly unremarkable, and pure tone audiometry testing was normal. A diagnosis of auditory agnosia was made based on her inability to understand verbal and environmental sounds with otherwise preserved language and hearing. Her follow-up electroencephalograms (EEG) continue to demonstrate bilateral temporo-occipital epileptiform discharges without clear clinical correlate or electrographic seizures. The MRI changes improved over the next 1.5 years with complete normalization on follow-up imaging at 2.5 years from onset.

Ongoing follow-up 3 years later has revealed persistence of the auditory agnosia with significant functional impairment in daily

communication. The patient has been unable to return to school or find employment because of her symptoms.

Auditory agnosia is defined as an impairment in perceiving or understanding sounds despite intact hearing and otherwise retained language function including reading, writing, and speech.<sup>1</sup> Subtypes include verbal auditory agnosia (inability to understand spoken words), non-verbal agnosia (inability to understand environmental sounds), and amusia (inability to discriminate pitch or recognize melodies).<sup>1–3</sup> Auditory agnosia may result from bilateral lesions to any structure along the auditory pathway, including the temporal lobes or the medial geniculate bodies of the thalamus.<sup>4</sup> Unilateral lesions, typically affecting the auditory cortex, have also been reported as well as bilateral lesions of the pons and midbrain.<sup>2,4</sup>

Vascular etiologies remain the most common cause of auditory agnosia, often located in the bilateral temporal lobes.<sup>2,4</sup> Other notable causes include herpes simplex encephalitis,<sup>1</sup> Landau-Kleffner syndrome,<sup>5</sup> and dementia.<sup>1,6</sup> Amusia can occur as an isolated finding in otherwise healthy individuals.<sup>3</sup> To our knowledge, AIE has not previously been reported as an etiology of auditory agnosia.

Isolated bilateral medial thalamic lesions are reported in patients with status and/or focal seizures and typically, but not always, resolve rapidly with control of the underlying seizure

disorder.<sup>7</sup> Pulvinar involvement, however, is not reported as an isolated finding in CASPR-related encephalitis. Accordingly, the etiology of the MR changes in our patient remain unclear and may be sequelae of seizure activity rather than direct effects of her presumed AIEs. Additionally the significance of her isolated CASPR2 antibody positivity is unknown given her clinical and imaging phenotype was atypical for CASPR2 encephalitis and no tissue-based corroborative assay was done.<sup>8</sup>

Nonetheless, we suspect in our case that either the bilateral thalamic lesions including the medial geniculate bodies or mesial temporal lobe involvement demonstrated on the PET scan (or both) were responsible for disruption to the auditory pathways leading to auditory agnosia. The auditory agnosia has persisted despite marked improvement in cognition and absence of ongoing seizures. It continues to cause significant functional impairment. Optimal therapy for patients with auditory agnosia remains unclear but speech therapy targeted at using alternate forms of communication including lip reading is recommended.<sup>4</sup> This case highlights that while many patients recover very well long term with AIE, even with early aggressive therapy, persistent focal deficits do occur and can result in significant long-term disability.

**Disclosures.** CH, PF, and KW report no disclosures.

**Statement of Authorship.** KW drafted the manuscript. CH and PF acquired the data and revised the manuscript.

## References

1. Robert Slevc L, Shell AR. Auditory agnosia. *Handb Clin Neurol*. 2015;129:573–87. DOI [10.1016/B978-0-444-62630-1.00032-9](https://doi.org/10.1016/B978-0-444-62630-1.00032-9).
2. Suh H, Shin YI, Kim SY, et al. A case of generalized auditory agnosia with unilateral subcortical brain lesion. *Ann Rehabil Med*. 2012;36:866–70. DOI [10.5535/arm.2012.36.6.866](https://doi.org/10.5535/arm.2012.36.6.866).
3. Ayotte J, Peretz I, Hyde K. Congenital amusia. *Brain*. 2002;125:238–51. DOI [10.1093/brain/awf028](https://doi.org/10.1093/brain/awf028).
4. Silva G, Gonçalves R, Taveira I, Mouzinho M, Osório R, Nzwalo H. Stroke-associated cortical deafness: a systematic review of clinical and radiological characteristics. *Brain Sci*. 2021;11:1383. DOI [10.3390/brainsci11111383](https://doi.org/10.3390/brainsci11111383).
5. Stefanatos G. Changing perspectives on Landau-Kleffner syndrome. *Clin Neuropsychol*. 2011;25:963–88. DOI [10.1080/13854046.2011.614779](https://doi.org/10.1080/13854046.2011.614779).
6. Otsuki M, Soma Y, Sato M, Homma A, Tsuji S. Slowly progressive pure word deafness. *Eur Neurol*. 1998;39:135–40. DOI [10.1159/000007923](https://doi.org/10.1159/000007923).
7. Ohe Y, Hayashi T, Deguchi I, et al. MRI abnormality of the pulvinar in patients with status epilepticus. *J Neuroradiol*. 2014;41:220–6. DOI [10.1016/j.neurad.2013.09.003](https://doi.org/10.1016/j.neurad.2013.09.003).
8. van Sonderen A, Ariño H, Petit-Pedrol M, et al. The clinical spectrum of Caspr2 antibody-associated disease. *Neurology*. 2016;87:521–8. DOI [10.1212/WNL.0000000000002917](https://doi.org/10.1212/WNL.0000000000002917).