

A viral infection of the hand commonly seen after the feast of sacrifice: human orf (orf of the hand)

M. UZEL^{1*}, S. SASMAZ², S. BAKARIS³, E. CETINUS¹, E. BILGIC¹,
A. KARAOGUZ¹, A. OZKUL⁴ AND O. ARICAN²

¹ Department of Orthopedic Surgery, Medical Faculty of University of Kahramanmaraş Sutcuimam, Kahramanmaraş, Turkey

² Department of Dermatology, Medical Faculty of University of Kahramanmaraş Sutcuimam, Kahramanmaraş, Turkey

³ Department of Pathology, Medical Faculty of University of Kahramanmaraş Sutcuimam, Kahramanmaraş, Turkey

⁴ Department of Virology, Faculty of Veterinary Medicine of Ankara University, Ankara, Turkey

(Accepted 15 December 2004)

SUMMARY

Orf of the hand is an uncommon zoonotic infection caused by a dermatropic DNA virus that belongs to the *Parapoxvirus* genus of the family Poxviridae. It is transmitted to humans through contact with infected sheep and goats and is reported as an occupational disease. We report nine cases of human orf seen in the hands of individuals, who were not occupationally exposed, after the feast of sacrifice in Turkey. Three cases were teachers and six out of the nine were housewives. We observed musculoskeletal complications and misdiagnoses. It is important to consider human orf in the differential diagnosis of hand lesions to prevent overtreatment and complications.

INTRODUCTION

Orf (also known as sore mouth disease, scabby mouth disease, infectious pustular dermatitis, contagious ectyma and ovine pustular dermatitis) is a common disease in sheep and goats. It is caused by a dermatropic DNA virus that belongs to the *Parapoxvirus* genus of the family Poxviridae [1–3]. It is a benign disease in humans which is occasionally reported in the literature. It has been reported in professional workers such as shepherds, sheepshearers and individuals bottle-feeding motherless lambs, butchers, abattoir workers and veterinary surgeons [2]. The hands are the most common site of orf, with other sites such as the face only occasionally being involved [4].

Orf is rare among viral infections of the hand [5]. The characteristic localized lesion is similar to a skin tumour and resolves spontaneously [2].

We reported nine orf lesions seen on the hands of non-professional individuals after the feast of sacrifice in Turkey. Their clinical features at different stages, complications and socio-cultural features were investigated.

MATERIALS AND METHODS

Nine cases of orf which were diagnosed in the days following the feasts of sacrifice in 2003 and 2004 are reported in our study. The cases were seen by dermatologists and orthopaedic surgeons on the day of referral. Diagnosis was made by history, appearance and location of the lesion and clinical course. Fluid and scrapings were taken for bacterial staining

* Author for correspondence: Dr M. Uzel, KSU Tıp Fakültesi Ortopedi ve Travmatoloji AD, 46050, Kahramanmaraş, Turkey. (Email: drmuratuzel@ksu.edu.tr or drmuratuzel@hotmail.com)

Table. *General evaluation of orf cases*

Patient no.	Sex	Age (years)	Job	Location in hand*, Surface	Incubation (day)	First referral day after lesion, First referral doctor intervention	Recovery time (day)	Complication
1	M	52	Teacher	L 2 Volar and dorsal	5	5 Dermatologist	33	Stiffness Swan-neck deformity Paresthesia
2	M	43	Teacher	Giant orf L 4 Dorsal	5	— 10 Practitioner Incision	24	—
3	F	51	Housewife	L 5 Dorsal Giant orf	7	30 Orthopaedic surgeon	70	—
4	F	46	Housewife	R 3 Dorsal	19	14 Practitioner Excision	31	—
5	F	58	Housewife	L 5 Dorsal	18	23 Orthopaedic surgeon	55	—
6	F	34	Housewife	L 1 Dorsal	15	9 Practitioner Anthrax treatment	30	—
7	M	41	Teacher	L 2 Dorsal	14	16 Dermatologist	30	—
8	F	49	Housewife	L 5 Dorsal	15	9 Dermatologist	20	—
9	F	33	Housewife	L 2 Dorsal	7	11 Dermatologist	40	—

* L, left; R, right; number, finger order (example: L 2=second finger of the left hand).

techniques and bacterial culture in six cases. Biopsy was performed in five cases for further investigation: histopathological study and cultural isolation attempts, and electron microscopic examinations were performed in these cases.

The existence of any history of contact with sheep or goats, duration of the prodromal period, time from appearance of the lesion to referral, the existence of any intervention to the lesion, profession, age and sex were recorded. The location of the lesions, the patient's dominant extremity, duration of recovery, complications and clinical symptoms were investigated.

RESULTS

All the cases were from the city centre (332 100 inhabitants) of Kahramanmaras in the Mediterranean

region of Turkey. They became contaminated through direct contact with infected goats or sheep during two feasts of sacrifice. All the sacrifices were not subject to veterinary control. The animals were slaughtered or prepared for consumption by the cases. There were six females and three males [mean age 45.2 years (range 33–58 years)]. Three cases were teachers and six out of nine were housewives. The mean incubation period was 11.7 days (range 5–19 days). The resolution of the lesions occurred within 37 days (range 20–70 days) on average (see Table).

Orf was seen in the left hand in eight cases and the right hand in one. The extremities involved were the non-dominant side in eight out of nine cases. All the lesions were located on the dorsum of the fingers. The index finger in three cases, the fifth finger in three cases, and one each for the thumb, third finger and fourth finger. Lesions progressed with distinct clinical

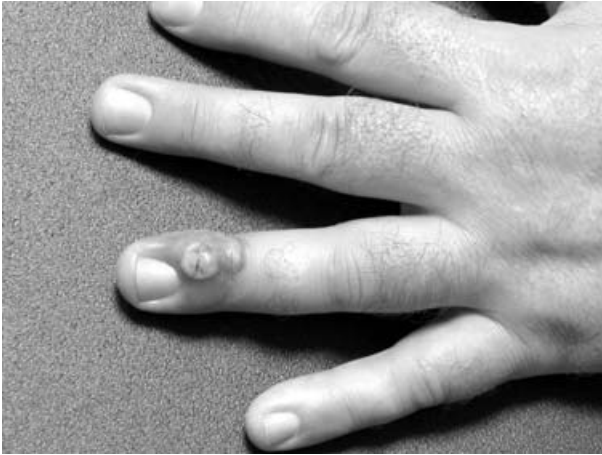

Fig. 1. Case 2. The appearance on referral day. Solitary lesion on nail fold at day 11 of infection and incision of the lesion are seen (acute stage).

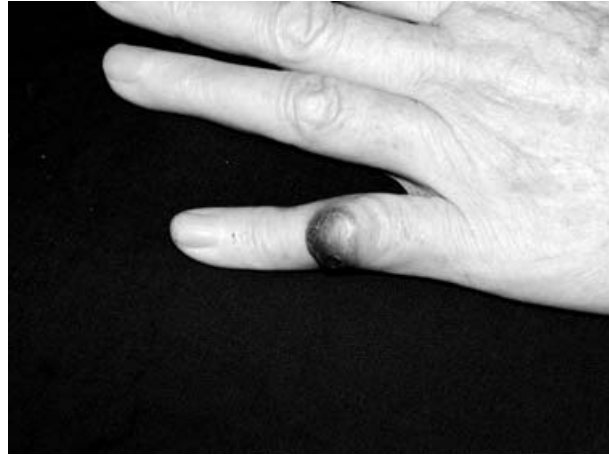


Fig. 3. Case 3. The appearance on referral day. The solitary lesion on the dorsal surface of the finger was seen at day 30 of infection (the end of the target stage).

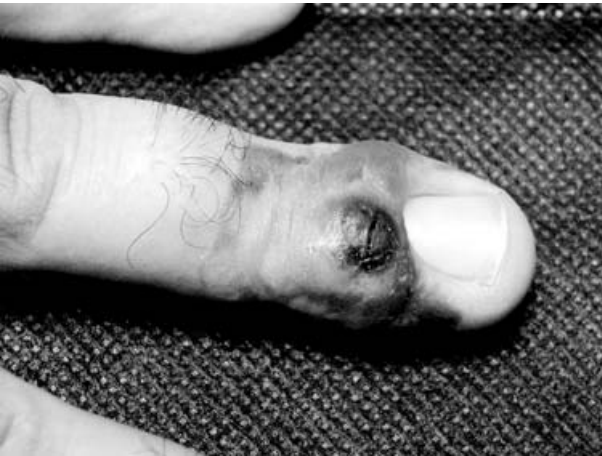

Fig. 2. Case 2. Illustration of the lesion at day 19 of infection (regenerative stage).

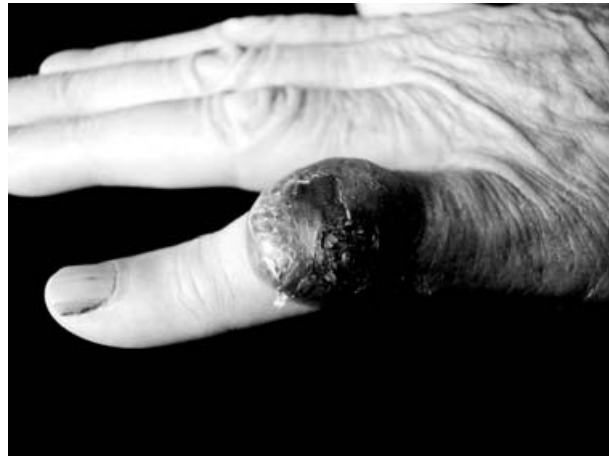

Fig. 4. Case 3. The appearance of the lesion at day 41 of infection (acute stage).

evolution and resolved with no residual scarring in approximately 6 weeks. This clinical course also verified the diagnosis of orf.

Cases had little pain and no fever. History of axillary or elbow lymphadenopathy and malaise were present in two cases.

Three cases received overtreatment from general practitioners. One received treatment for a diagnosis of anthrax. The lesion of another case was incised by a scalpel for drainage (Figs 1 and 2) while the lesion in a third case was excised totally. In two cases giant orf developed (Figs 3 and 4). The appearance and rapid progression of the lesion caused psychological stress and made the patients fearful of having cancer. Psychological support was needed in those cases.

Complete blood counts were normal in all cases. The results of bacterial culture and staining were negative. In five cases, histopathological confirmation was made. There was vacuolization of cells in the upper third of the epidermis in some of the cases, while in other cases the epidermis showed acanthosis with finger-like downward projections and the dermis contained dilated capillaries and mononuclear infiltrate (Fig. 5). Culture inoculations and electron microscopic examinations revealed no virus growth or viral particles in the preparations monitored, respectively.

In all cases, wound care with conservative measures was applied. The symptomatic management consisted of adequate analgesia; wound care with povidone-iodine and keeping the lesion dry. There was no need for antibiotics. All but one case resulted in healing

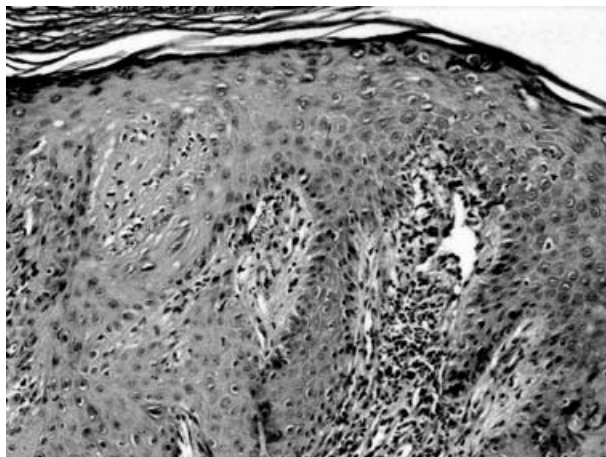


Fig. 5. The epidermis shows acanthosis with finger-like downward projections and the dermis contains capillary proliferation and mononuclear infiltrate (HE $\times 200$).

without any complications. Stiffness in the finger joints, swan-neck deformity and paresthesia developed in one case with giant orf.

DISCUSSION

The first definition of orf disease and a published case report was by Newson & Cross in 1934 [6, 7]. Since that time, two large-scale studies have addressed this disease. A Norwegian study in 1975 reported on 119 patients seen over an 18-year period. The authors noted that both human and animal infections occurred more frequently in certain geographic areas. Diagnosis was made on clinical grounds and was confirmed by laboratory tests in 16 patients. The hands were the most common site of infection. Regional adenitis was present in one third of patients. Erythema multiforme was noted in 16 cases, and in two cases erythema multiforme bullosum was present. Electron microscopic examination of biopsy specimens showed that viral particles were only found in the epidermis and that the number of virus-containing cells was greatest in the first 2 weeks after infection [8]. A study from New Zealand in 1983 documented 231 orf patients in one year and recorded 18 patients with reinfection [9]. In North America human orf is a rare disease [10].

The orf virus is transmissible to humans by direct contact with infected animals and occasionally through contaminated objects [3, 7, 11]. Instead of being reported simply as a professional disease, an epidemic outbreak of human orf may be observed after the feast of sacrifice in Muslim countries [12].

During the feasts of sacrifice, the population may be in contact with sheep and goats for a variety of reasons. In our cases transmission from goats and sheep to humans was observed in the first 2 days of the feast in which animals were generally sacrificed.

A single lesion or occasionally multiple lesions, develop at the site of contact, frequently an abrasion on the hand. The lesions are most commonly seen on non-dominant hands as in our patients [12]. The incubation period may continue from a few days to 1 week with complaints of pain being minimal. Mild systemic symptoms may occur with the lesion. The disease is self-limiting and spontaneous resolution often occurs within 6 weeks. Mendez & Burnett described six distinct clinical stages of orf in detail: maculopapular, target, acute, regenerative, papillomatous, and regressive [3, 11]. The maculopapular stage consists of an erythematous macule or papule. In the target stage, the lesion has a red centre, a central white ring, and an outer red halo. The acute stage consists of an erythematous weeping nodule. In the regenerative stage, the lesion is dry with small black dots on the outside surface. The papillomatous stage is characterized by papillomas appearing on the surface. A dry crust characterizes the regressive stage. Residual scarring is unusual [11].

Prompt diagnosis is easily made by obtaining a complete patient history and by considering human orf as a differential diagnosis when an unusual lesion is seen in an individual who has had contact with sheep or goats. Diagnosis is confirmed by pathological examination of an incisional biopsy specimen.

Electron microscopy can help in establishing the diagnosis but is difficult in later stages of the disease, as proved in our cases. Isolation of the virus by tissue culture inoculation has proved to be difficult; and we failed to do so. Serum analysis for antibodies is seldom used [2].

Differential diagnoses include herpetic paronychia abscess, milker's nodules, cowpox, cutaneous anthrax, infection of *Mycobacterium marinum*, deep fungal infections, pyogenic granulomas, keratoacanthoma and malignant tumours [1–3, 13]. By case history, clinical examination and laboratory findings, exclusion of the enumerated lesions is not difficult.

An awareness of orf is important since its course is benign and does not require any specific treatment. Lesions generally heal without complication [3]. Lymphangitis, lymphadenitis and general malaise with fever can accompany the peripheral lesions. Reported complications include superinfection, erythema

multiforme, chills, fever, and rare ophthalmic involvement [2, 4, 9]. In one of our cases, after spontaneous resolution we observed paresthesia as a neurological complication and also limited movement and swan-neck deformity of the index finger as a musculoskeletal complication. These rare complications were reported previously [14].

Psychological support may be necessary as in two of our cases. In the literature, the same event for a surgeon was also reported and physicians who are unfamiliar with human orf may misdiagnose such rapidly growing tumours as malignant, leading to aggressive treatment such as an amputation. Savage & Black described a lesion on the finger of a patient treated with immunosuppression due to lymphoma; the finger had to be amputated [15]. Two of our cases were also exposed to unnecessary intervention.

All sheep and goats should be considered as a potential source of infection. Veterinary control and preventive measures are very important especially in the meat industry [2, 3].

We observed human orf in the hands of individuals who were not professional workers and believed that the cause was uncontrolled slaughtering of animals by non-professional individuals during the feasts of sacrifice. Information concerning orf should be given to the relevant people and special attention should be paid to the rules of slaughtering an animal. Human orf is well recognized by dermatologists and other physicians, especially orthopaedic surgeons should also recognize orf. It is important to consider human orf as a differential diagnosis of hand lesions to prevent overtreatment and complications.

REFERENCES

1. **Arnaud JP, Bernard P, Souyri N, Pecout C, Dunoyer J.** Human ORF disease localized in the hand: a 'false felon'. A study of eight cases. *Ann Chir Main* 1986; **5**: 129–132.
2. **Chahidi N, de Fontaine S, Lacotte B.** Human orf. *Br J Plast Surg* 1993; **46**: 532–534.
3. **Zimmerman JL.** Orf. *J Am Med Assoc* 1991; **266**: 476.
4. **Gill MJ, Arlette J, Buchan KA, Barber K.** Human orf. A diagnostic consideration? *Arch Dermatol* 1990; **126**: 356–358.
5. **Fowler JR.** Viral infections. *Hand Clin* 1989; **5**: 613–627.
6. **Newson IE, Cross F.** Sore mouth in sheep transmissible to man. *J Am Vet Med Assoc* 1934; **84**: 790–802.
7. **Waldram MA.** A seven-year-old girl with orf of the hand. *J Hand Surg [Br]* 1986; **11**: 467–468.
8. **Johannessen JV, Krogh HK, Solberg I, Dalen A, van Wijngaarden H, Johansen B.** Human orf. *J Cutan Pathol* 1975; **2**: 265–282.
9. **Robinson AJ, Petersen GV.** Orf virus infection of workers in the meat industry. *N Z Med J* 1983; **96**: 81–85.
10. **Moore Jr. RM.** Human orf in the United States. *J Infect Dis* 1972; **27**: 731–732.
11. **Mendez B, Burnett JW.** Orf. *Cutis* 1989; **44**: 286–287.
12. **Gunes AT, Gezen C, Kapdagli H, Marschall HJ.** Ecthyma contagiosum epidemien in der Turkei. *Hautarzt* 1982; **33**: 384–387.
13. **Friedmann PS, Wilkinson M.** Occupational dermatoses. In: Bologna JL, Jorizzo JL, Rapini RP et al. eds. *Dermatology*. Spain: Mosby, 2003: 251–264.
14. **Uzel M, Sasmaz S, Ozkul A, Cetinus E, Karaoguz A.** Swan-neck deformity and paresthesia following giant orf. *J Dermatol* 2004; **31**: 116–118.
15. **Savage J, Black MM.** 'Giant' orf of finger in a patient with a lymphoma. *Proc Roy Soc Med* 1972; **65**: 766–768.