

Inclusion Body Myositis Associated with Systemic Sarcoidosis

Moris J. Danon, Osvaldo H. Perurena, Salve Ronan and Jose R. Manaligod

ABSTRACT: We report an autopsy study of a 64-year-old female with systemic sarcoidosis. In addition many muscles showed typical light and electron microscopic features of inclusion body myositis. To our knowledge this association has not been previously reported.

RÉSUMÉ: Nous rapportons l'étude du matériel anatomopathologique provenant de l'autopsie d'une femme âgée de 64 ans atteints de sarcoïdose systémique. En plus des lésions de sarcoïdose, on retrouvait à la microscopie optique et électronique des manifestations de myosite à corps d'inclusion au niveau de plusieurs muscles. A notre connaissance, cette association n'a encore jamais été rapportée.

Can. J. Neurol. Sci. 1986; 13:334-336

Inclusion body myositis (IBM) is a recently recognized and distinct inflammatory myopathy. Several dozen cases of IBM have been published and probably many more are either unreported or remain undiagnosed. The classically held view of IBM is that it clinically differs from other types of inflammatory myopathies by its relatively benign protracted course, absence of features of collagen-vascular disease, male preponderance and lack of response to immunosuppression. Light microscopy shows muscle fibres containing vacuoles lined with hematoxylinophilic granules, as well as variable degrees of inflammation and necrosis. In many biopsies mixed features of both denervation and myopathy are seen. The prerequisite for the diagnosis is the ultrastructural presence of intracytoplasmic and/or intranuclear masses of abnormal filaments, each measuring 14 to 18 nm in diameter.¹⁻³ Although most patients with IBM lack features of immunological disease, four cases associated with collagen-vascular disease and one with chronic immune thrombocytopenia have recently been reported.³⁻⁷ Adding to this list, we describe here a patient with systemic sarcoidosis and associated IBM.

REPORT OF A CASE

A 64-year-old black female presented with a one year history of progressive difficulty in climbing stairs. On examination she had marked weakness of hip muscles with moderately decreased strength in dorsiflexion of the feet and in hand grip. There was no craniobulbar involvement; stretch reflexes were hypoactive throughout; sensation and coordination were normal. She had no myalgia, dysphagia or skin rash. A presump-

tive diagnosis of pulmonary sarcoidosis was made twenty years before on the basis of an abnormal radiologic study. On admission, a roentgenogram of the chest showed reticulonodular interstitial fibrosis; the image was unchanged when compared with previous films. Nerve conduction velocities were normal. Needle electromyography (EMG) showed short duration, low amplitude, polyphasic motor unit potentials and some fibrillations. Electrocardiogram (ECG), urinalysis, blood urea nitrogen (BUN), glucose, calcium, alkaline phosphatase, serum glutamic-oxalacetic transaminase (SGOT), pyruvic transaminase (SGPT), lactate dehydrogenase (LDH) were normal. Except for a mildly increased sedimentation rate the hemogram was unremarkable. Rheumatoid arthritis (RA) factor, antinuclear antibodies (ANA) and lupus erythematosus (LE) cells were not demonstrated. Serum creatine kinase (CK) was elevated at 255 (N < 87 I.U.). Both serum protein and immunoelectrophoresis showed polyclonal gammopathy. Cerebrospinal fluid (CSF) examination was normal. Repeated cultures of sputum and CSF for acid fast bacilli (AFB) were negative. Serological testing for blastomycosis, coccidiomycosis, histoplasmosis and skin reactions to various antigens (mumps and purified protein derivative) were negative. Pulmonary function tests were abnormal.

A muscle biopsy showed numerous noncaseating granulomas compatible with sarcoidosis. There were no features of IBM. She received prednisone (40 mg/day) for six months with no improvement. One year later, she suffered a femoral fracture and died shortly thereafter, from pulmonary complications.

AUTOPSY FINDINGS

Postmortem examination revealed massive pulmonary thromboemboli involving both right and left pulmonary arteries and their branches. The lungs showed apical emphysema and fibrosis. Microscopically, many noncaseating granulomas were seen in

Presented in part at the XIIIth World Congress of Neurology, Hamburg, West Germany, September 1-6, 1985

From the Departments of Neurology (Drs. Danon and Perurena*) and Pathology (Drs. Danon, Ronan, Manaligod), University of Illinois College of Medicine, Chicago, Illinois

*Dr. Perurena's present address is Department of Neurology, Veterans' Administration Hospital, Topeka, Kansas, U.S.A.

Received February 4, 1986. Accepted in final form August 29, 1986

Reprint requests to: Moris J. Danon, Department of Neurology, University of Illinois College of Medicine, 912 South Wood Street, Chicago, Illinois U.S.A. 60612

peribronchial areas, as well as in the regions of subpleural fibrosis (Figure 1). Similar noncaseating granulomas were seen in the spleen, liver, perihilar and mesenteric lymph nodes, left deltoid (Figure 2) and right gastrocnemius muscles. Special stains for fungus and mycobacteria were negative. The central nervous system was not examined.

Cryostat sections from the left deltoid muscle showed numerous small angulated fibres, at times forming small groups. These fibres were intermingled with many small, rounded and few hypertrophic fibres. However, histochemical stains did not show any type grouping or targets. Scattered necrotic fibres undergoing phagocytosis and few regenerating fibres also were noted. There was some mild inflammation which consisted of both perivenular and endomysial mononuclear infiltrates (Figure 3). About 10 percent of muscle fibres had single or multiple "lined" vacuoles (Figure 4). Intranuclear inclusions and noncaseating granulomas were absent; this was probably a sampling bias since they were seen in other muscle samples processed for paraffin embedding. Electron microscopy (EM) of these vacuoles showed membranous whorls, some glycogen particles, and filaments measuring 14.0 to 18.0 nm in diameter, findings typical for IBM (Figure 5).^{1,2}

COMMENT

Noncaseating granulomas are frequently found in muscle biopsies of patients with generalized sarcoidosis even in the absence of signs and symptoms of muscle disease. In a smaller group, sarcoidosis may present as chronic myopathy and has a preponderance for post-menopausal women in their fifties. Serum enzymes are usually elevated and EMG is compatible with myopathy.⁸ Granulomatous myopathy also can occur without systemic involvement. Although the granulomas histologically are similar to those seen in sarcoidosis, the so-called granulomatous myopathies are usually considered separate clinical pathological entities.^{9,10} A case of sarcoid myopathy associated with the typical clinical and pathological findings of dermatomyositis has been reported in which the patient had major improvement with steroid therapy.¹⁰ In general the response to treatment with corticosteroids in systemic sarcoidosis is quite variable. The overall prognosis appears to be better in patients with peripheral rather than central nervous system involvement.⁸

Like sarcoidosis, IBM is a chronic painless myopathy with similar distribution of muscle weakness and usually shows mild elevation of CK. In some patients, however, the presence of distal weakness and atrophy, absent stretch reflexes, occasional asymmetric distribution and intact sensation, IBM may resemble either a distal myopathy or motor neuron disease.^{1,2} Indeed in many patients EMG studies have shown fibrillation potentials and large, highly polyphasic motor units compatible with a neurogenic phenomenon in addition to electrophysiological "myopathic" derangement. These features, coupled with histological changes of denervation (without reinnervation) and prominent increase in fibre density by single fibre electromyography, prompted Eisen et al¹¹ to suggest a neurogenic origin in some cases of IBM.

The characteristic light microscopic feature of IBM is the so called "lined" or "rimmed" vacuole.^{1,2} In addition to IBM these vacuoles have been found in some cases of oculopharyngeal dystrophy (OPD)¹² and in a familial myopathy of Iranian Jews.¹³

In none of these cases, however, were the classical filamentous inclusions (the prerequisite for a diagnosis of IBM) demonstrated by EM except in one case of OPD where Smith and Chad¹² described a single nucleus containing the typical inclusions. Intranuclear inclusions similar to the ones found in IBM have been reported in an autopsy study of the brain, adrenal gland,

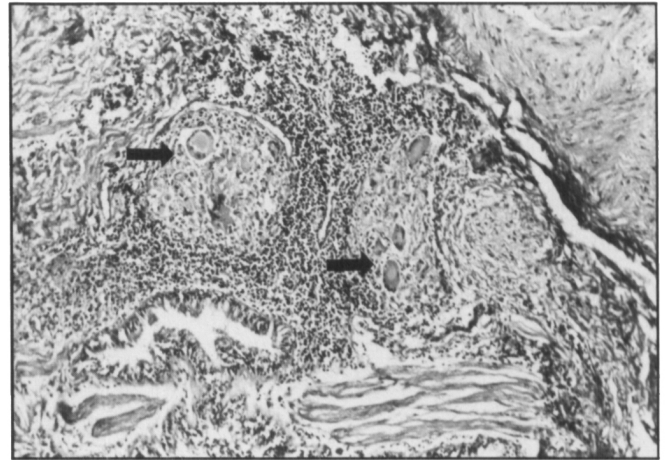


Figure 1 — The lung show numerous noncaseating granulomas with many multinucleated giant cells (arrow). H-E x 60.

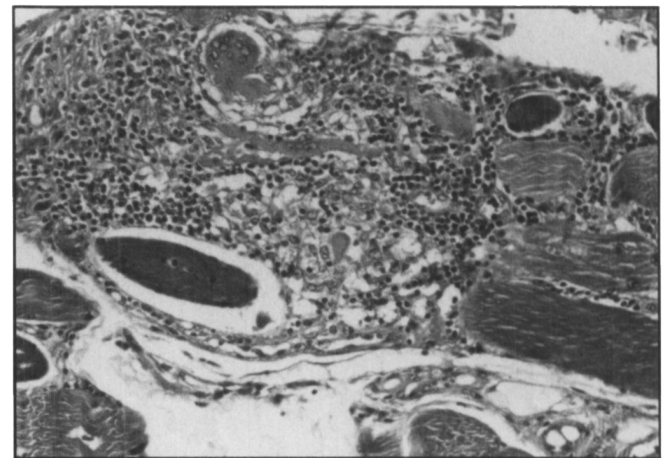


Figure 2 — Sections from formalin fixed, paraffin, embedded muscle also show noncaseating granulomas. H-E x 60.

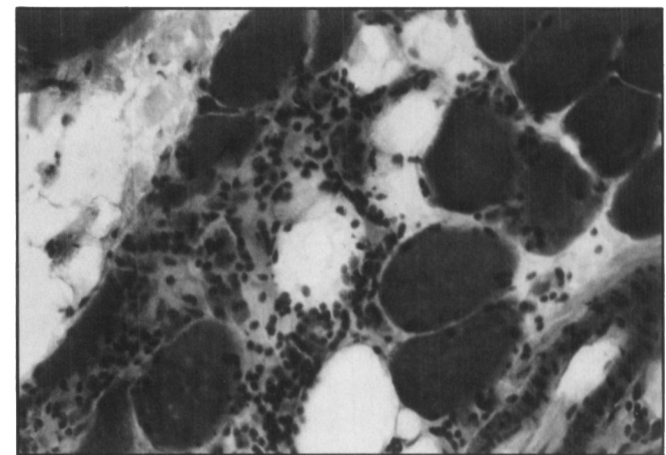


Figure 3 — Cryostat section from deltoid muscle shows mononuclear inflammatory cell infiltrate. H-E x 160.

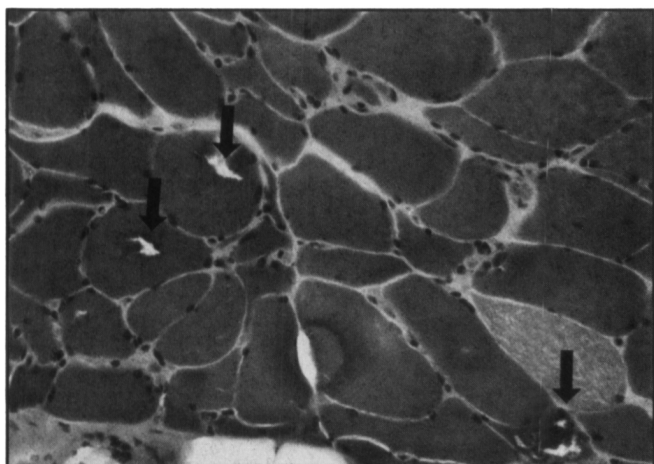


Figure 4 — Cryostat section shows three "lined" vacuoles in muscle fibres (Arrows). H-E x 160.

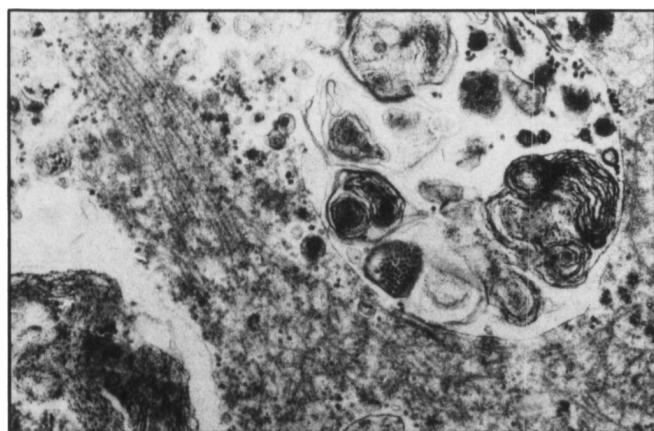


Figure 5 — Electron micrograph from a "lined" vacuole showing whorls of cytomembranes, glycogen particles and randomly oriented, abnormal filaments. x 23,000.

and muscle in a patient who appeared to have some sort of long standing motor neuron disease with bulbar involvement.¹⁴ In addition they have also been noted in two cases of giant cell tumour of bone and in osteoclasts of patients with Paget's disease.¹ It is of interest to note that one of our previous patients had both IBM and Paget's disease.²

Recently a number of patients with IBM, have been reported in association with disorders known to have immunological derangements; chronic immune thrombocytopenia, scleroderma, Sjögren's syndrome and in a patient with some sort of collagen vascular disease with a skin rash.³⁻⁷ Although most cases of IBM are resistant to various types of immunosuppression, two successfully treated cases have been reported. One was treated with steroids, while the other received total body irradiation.^{3,15}

Chronic viral infection in IBM has been suggested by many authors, but viral isolation has been unsuccessful, except in the case of Mikol et al¹⁶ who demonstrated serological evidence of infection for a strain of adenovirus type 2 in a muscle biopsy. Recently Chou and Mizuno using a histochemical technique, demonstrated antigen to mumps virus both in nuclei and "lined" vacuoles of 6 patients diagnosed to have IBM.¹⁷ This is probably the first convincing evidence that implicates viral infection in the etiology of this disease.

There is ample evidence that patients with sarcoidosis have immunological disturbances compatible with altered cell-mediated

immunity.^{18,19} It is possible that a prolonged altered immunological state made our patient susceptible to a viral infection and subsequently developed IBM. Recently Arahata and Engel^{20,21} in a study with monoclonal antibodies of various myopathies have shown an altered immune state in the form of T-cell-mediated muscle fibre injury in IBM and polymyositis. With this body of evidence¹⁶⁻²¹ and the growing number of cases of IBM associated with various diseases³⁻⁷ known to have altered immune states, the presence of IBM in this patient with systemic sarcoidosis appears to be more than a chance association.

REFERENCES

1. Carpenter S, Karpati G, Heller I, et al. Inclusion body myositis: A distinct variety of idiopathic inflammatory myopathy. *Neurology* 1978; 28: 8-17.
2. Danon M, Reyes M, Perurena O, et al. Inclusion body myositis. A corticosteroid-resistant idiopathic inflammatory myopathy. *Arch Neurol* 1982; 39: 760-764.
3. Lane RAM, Fulthorpe SJ, Hudgson P. Inclusion body myositis. A case with associated collagen vascular disease responding to treatment. *J Neurol Neurosurg Psychiatr* 1985; 48: 270-273.
4. Chad D, Good P, Adelman L, et al. Inclusion body myositis associated with Sjögren's syndrome. *Arch Neurol* 1982; 39: 186-188.
5. Salama J, Tomé FMS, Lebon P, et al. Myosite à inclusions. Étude clinique, morphologique et virologique concernant une nouvelle observation associée à une sclérodémie généralisée et à un syndrome de Klinefelter. *Rev Neurol (Paris)* 1980; 136: 863-878.
6. Riggs J, Schochet S, Gutmann L, et al. Inclusion body myositis and chronic immune thrombocytopenia. *Arch Neurol* 1984; 41: 93-95.
7. Gutmann L, Govindan S, Riggs JE, et al. Inclusion body myositis and Sjögren's syndrome. *Arch Neurol* 1985; 42: 1021-1022.
8. Delaney PN. Neurologic manifestations in sarcoidosis. Review of literature, with report of 23 cases. *Ann Int Med* 1977; 87: 336-345.
9. Namba T, Brunnen NG, Grob D. Idiopathic giant cell polymyositis. Report of a case and review of the syndrome. *Arch Neurol* 1974; 31: 27-30.
10. Itoh J, Akiguichi I, Reiko M, et al. Sarcoid myopathy with typical rash of dermatomyositis. *Neurology* 1980; 30: 1118-1121.
11. Eisen A, Berry K, Gibson G. Inclusion body myositis: Myopathy or neuropathy. *Neurology* 1983; 33: 1109-1114.
12. Smith WT, Chad D. Intranuclear inclusions in oculopharyngeal dystrophy. *Muscle Nerve* 1984; 7: 339-340.
13. Argov Z, Yarom R. "Rimmed vacuole myopathy" sparing the quadriceps. A unique disorder in Iranian Jews. *J Neurol Sci* 1984; 64: 33-43.
14. Tateishi J, Nagara H, Ohta M, et al. Intranuclear inclusions in muscle, nervous tissue and adrenal gland. *Acta Neuropathol* 1984; 63: 24-32.
15. Kelly JJ, Madoc-Jones J, Adelman LR, et al. Treatment of refractory polymyositis with total body irradiation. *Neurology* 1984; 34 (Suppl.): 80.
16. Mikol J, Felten-Papaiconomou A, Ferchal F, et al. Inclusion body myositis: Clinicopathological studies and isolation of an adenovirus Type 2 from muscle biopsy specimen. *Ann Neurol* 1982; 11: 576-581.
17. Chou SM, Mizuno Y. Mumps virus antigen in inclusion body myositis (IBM). *Neurology* 1985; 35 (Suppl.): 204.
18. James DG, Neville E, Walker A. Immunology of sarcoidosis. *Am J Med* 1975; 59: 388-394.
19. Hedford E. *Clinical Immunology*, Parker C (ed.), WB Saunders 1; 1980, pp. 556-582.
20. Arahata K, Engel A. Monoclonal antibody analysis of mononuclear cells in myopathies. I: Quantitation of subsets according to diagnosis and sites of accumulation and demonstration and counts of muscle fibres invaded by T cells. *Ann Neurol* 1984; 16: 193-208.
21. Engel A, Arahata K. Monoclonal antibody analysis of mononuclear cells in myopathies. II: Phenotypes of auto-invasive cells in polymyositis and inclusion body myositis. *Ann Neurol* 1984; 16: 209-215.