



# Spinal Dural Arteriovenous Fistula with Unusual Tract Enhancement

Ruba Kiwan, Kevin Wade, Sachin Pandey , Melfort Boulton , Donald Lee, Manas Sharma

**Keywords:** Spinal dural arteriovenous fistula, MRI

doi:10.1017/cjn.2021.8

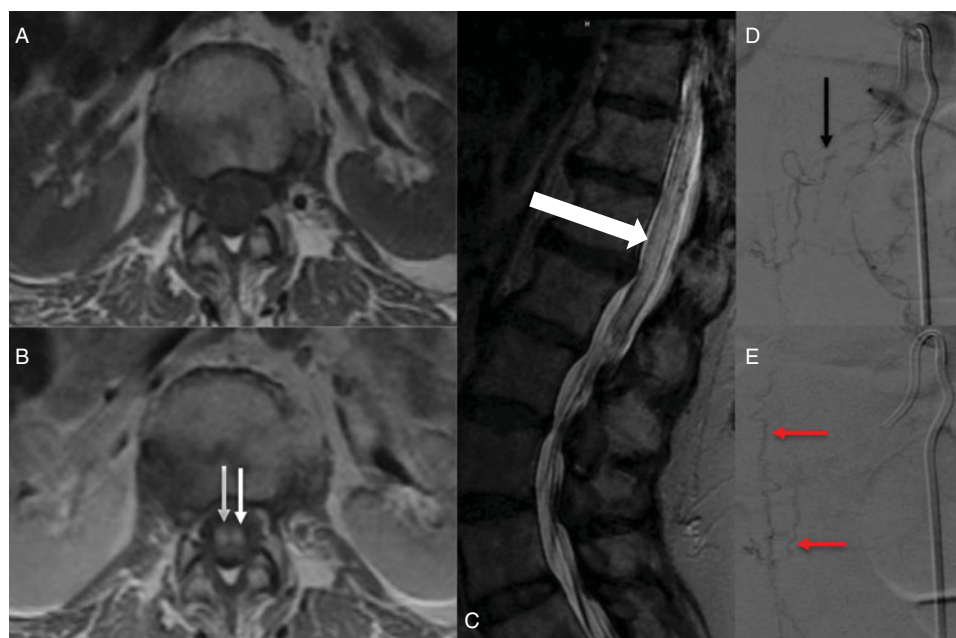
Can J Neurol Sci. 2021; 48: 857–858

An 83-year-old female presented with bilateral feet tingling since 2012, progressively ascending to lower back. She had a 2-year history of recurrent falls and progressive ambulation difficulties and urinary incontinence and retention for 3 months and was found to have bilateral paraparesis, T10 sensory level, and 2+ bilateral reflexes. Clinical picture was consistent with thoracic myelopathy.

Spinal magnetic resonance imaging (MRI) showed diffuse contiguous central spinal cord T2 hyperintensity from T7 through

the conus medullaris (Figure 1c), prominent perimedullary vessels, suspicious of venous congestion secondary to a spinal dural arteriovenous fistula (sDAVF). However, a striking pattern of abnormal ventral cord tract enhancement was seen (Figure 1b), a feature more common in infectious or inflammatory etiologies. The cord enhancement extended from about the level of T8 in the thoracic spine to the conus medullaris (sagittal images not provided).

Initially treated as transverse myelitis with a short course of steroids with no clinical improvement, spinal angiography



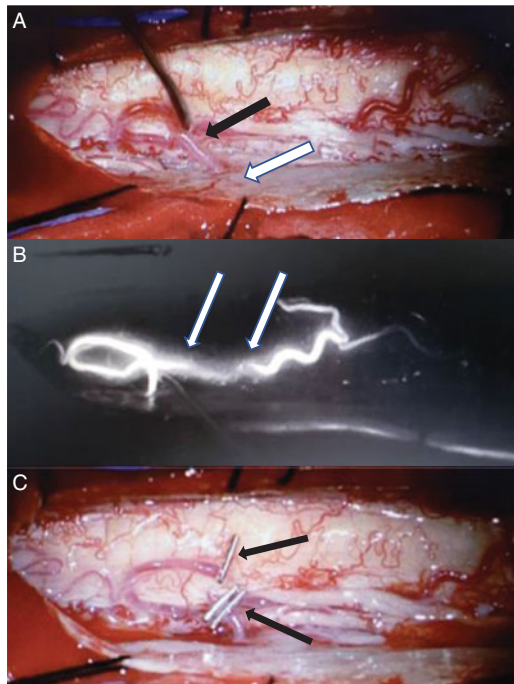
**Figure 1:** Pre- (a) and post- (b) gadolinium axial T1 images at L1 level demonstrate striking pattern of abnormal tract-based ventral spinal cord enhancement (double white arrows), and (c) sagittal T2 MRI demonstrates diffuse lower cord swelling and central T2 hyperintensity (white arrow) from T6–T7 through the conus medullaris. Diagnostic spinal angiography (d) reveals a spinal dural arteriovenous fistula supplied via the left T11 segmental artery, and specifically the radiculo-meningeal branch originating at that level (black arrow); (e) late phase image demonstrates dilated perimedullary vein (double red arrow).

From the Division of Neuroradiology, Department of Medical Imaging, Western University, London, ON, Canada (RK, SP, DL, MS); and Department of Neurosurgery, Western University, London, ON, Canada (RK, KW, MB)

RECEIVED OCTOBER 10, 2020. FINAL REVISIONS SUBMITTED DECEMBER 16, 2020. DATE OF ACCEPTANCE JANUARY 8, 2021.

Correspondence to: Ruba Kiwan MD, Department of Medical Imaging, Western University, London, ON, Canada. Email: [kiwanruba@gmail.com](mailto:kiwanruba@gmail.com)

RK wrote the manuscript, KW and MB provide the intraoperative images and details, and SP, DL, and MS made revisions and approved the final version



**Figure 2:** Intraoperative images showing: (a) microsurgical isolation of the dilated perimedullary vein (black arrow), with entry into the dural root sleeve (white arrow). (b) Abnormal early opacification of the perimedullary vein with intraoperative indocyanine green (ICG) (double white arrow). (c) Microsurgical disconnection of the vein (double black arrow).

demonstrated the sDAVF supplied from the radiculo meningeal branch of the left T11 segmental artery.

Urgent operative intervention with T10–T11 laminectomy, microsurgical dissection of the abnormal perimedullary vein (Figure 2a) followed by confirmation of early filling with indocyanine green (Figure 2b) was done. The vein was then disconnected, with no intraoperative complications. She steadily continued to improve and was discharged to a rehabilitation

center on the 10th day. A 2-month follow-up showed her to be independent in daily activities.

sDAVF is rare and yet the most common treatable vascular abnormality of the spinal cord causing progressive myelopathy,<sup>1</sup> with an average time to diagnosis of 22 months, most commonly seen in elderly men. MRI shows cord edema, dilated perimedullary blood vessels,<sup>2</sup> and diffuse cord enhancement from blood–spine barrier breakdown following chronic venous congestion.<sup>3</sup> A unique pattern of “missing-piece” enhancement<sup>4</sup> as well another case with spinal nerve root enhancement<sup>5</sup> have also been reported.

To the best of our knowledge, a tract-based pattern of cord enhancement in sDAVF has not been reported earlier. The likely pathophysiology for this pattern is blood–spine barrier disruption from long-standing venous congestion. sDAVF needs consideration even in cord tract enhancing patterns, facilitating early investigation and proper diagnosis.

#### DISCLOSURES

The authors have no conflicts of interest to declare.

#### REFERENCES

1. Krings T, Geibprasert S. Spinal dural arteriovenous fistulas. *Am J Neuroradiol.* 2009;30(4): 639–48. doi: <https://doi.org/10.3174/ajnr.A1485>
2. Fox S, Hnenny L, Ahmed U, Meguro K, Kelly ME. Spinal dural arteriovenous fistula: a case series and review of imaging findings. *Spinal Cord Ser Cases.* 2017;3:17024.
3. Chen CJ, Chen CM, Lin TK. Enhanced cervical MRI in identifying intracranial dural arteriovenous fistulae with spinal perimedullary venous drainage. *Neuroradiology.* 1998;40:393–7.
4. Zalewski N, Rabinstein A, Brinjikji W, et al. Unique gadolinium enhancement pattern in spinal dural arteriovenous fistulas. *JAMA Neurol.* 2018;75(12):1542–5. doi: [10.1001/jamaneurol.2018.2605](https://doi.org/10.1001/jamaneurol.2018.2605).
5. Elsaddig AKH, Leyon J, Chowdhury F. Spinal dural avf with nerve root enhancement. *J. Neurol. Neurosurg. Psychiatry.* 2017;88: A70–1.