

F O R E W A R D

Extractions and orthodontics:
Primum non nocere

Philippe AMAT

Former assistant professor at the University of Paris V
Private practice in Le Mans*"A tooth is a thousand times more precious than a diamond."*

Spanish proverb

INTRODUCTION

Deciding whether or not to extract permanent teeth is probably the one aspect of orthodontic practice that has stirred up the most debate. For more than a century, opposing groups of clinicians have disagreed as to whether it is sometimes necessary to extract or if it is always possible to develop the arches in order to avoid extractions.

Besides a laudable desire to spare our patients the trauma and cost of extractions, and the wish to save their permanent teeth, the controversy concerns the supposed consequences of these extractions. Detractors argue that they would be, among other reasons, a contributing factor to the development or worsening of dysfunctional disorders of the masticatory apparatus (TMD) or obstructive sleep apnea-hypopnea syndrome (OSAHS), and

of deleterious effects on the esthetics of the profile and of the smile.

Must we, as a consequence, abandon those treatments involving the extraction of permanent teeth?

As it often happens in the medical field, there is no unequivocal answer to this essential question; however, the clinician must avoid two pitfalls⁵:

- abandoning all critical judgment, and even good clinical reasoning, just because we have read some data identified as *evidence-based*;
- throw the baby out with the bathwater and deprive the patient of the significant contributions provided by a fact-based approach that could improve treatment.

THE PENDULUM SWINGS BOTH WAYS

Like a scale, the therapeutic indication for extractions has swung starting with

Fauchard between two extreme positions: systematically preserving the complete

Address for correspondence:

Philippe Amat
8 rue Buffon
72000 Le Mans
amatph@noos.fr

dentition, regardless of the consequences, or blindly resorting to extractions in order to respect cephalometric norms.

We limited this historical review to two concepts that have particularly marked our concept of therapy.

At the very beginning of the 20th century, based on the laws of Roux and Wolff that had affirmed the predominant influence of functional factors on morphogenesis, E. Angle concluded that occlusion played the dominant role in functional stimulation. Achieving optimal occlusal function was supposed to stimulate growth of the basal bone and make it possible to treat arch length discrepancy without extractions.

Forty years later, once the primacy of control of morphogenesis was attributed to genetic factors, C. Tweed recommended that practitioners resort to extractions, in order to adapt the dentition to the basal bones and to attain the objective of strict repositioning of the incisors.

The evolution of these two therapeutic concepts has now shifted more towards treatment without extractions. Self ligating brackets are the most recent appliances that proponents, particularly Damon¹¹, claim have the capacity to significantly reduce the indications for extractions as well as the length of treatment.

CRITICAL JUDGMENT AND GOOD CLINICAL REASONING

A few simple observations will allow us to illustrate how critical it is to be careful to circumvent one pitfall, that consisting of abandoning our critical judgment and our good clinical reasoning, as soon as we see data labeled *evidence-based*.

One of the questions raised by resorting to the extraction of permanent teeth has to do with allegations that there is a cause and effect relationship between extractions and the appearance or worsening of dysfunctional disorders of the masticatory apparatus (TMD)²⁶.

If the published data^{7,16,22} helped to refute these assertions, the critical reasoning of the clinician reminds him to be prudent. The authors of systematic reviews and of meta-analyses deplore the limitations of the data, due to the lack of homogeneity

of methodologies used in the studies and because of the very vague definition of the diagnostic criteria for TMD.

The critical reasoning of the practitioner also makes him plan for potential associations of TMD with orthodontics through an epidemiological filter that reports a significant increase in the prevalence of TMDs during the second decade in the life of our patients³⁵.

In addition, and regardless of the conclusions of the published data, the critical reasoning of the practitioner forces him to be even more alert to the presence of any previous TMD symptoms or to any factors that might trigger these disorders, such as parafunctions. This same good reasoning will encourage him to aim for the objective of establishing a

therapeutic occlusion that meets the criteria of a functional occlusion.

Before researching the published data for the most significantly effective technique for creating or restoring space, good clinical reasoning would suggest that we at least preserve what is naturally available. Highly recommended since 1947 by Nance²⁵, the mere preservation of 5.15 ± 0.68 mm of space in a mesial direction is critically important in the management of mandibular crowding, as shown by A. A. Gianelly¹⁹. If we remain vigilant to the possibility of the eruption of second molars, whether we ensure this with a lingual arch or a *lip-bumper*, why would we deprive our patients of this advantage?

The early correction of a transverse problem, and of dysfunctional breathing that is associated with it³³, can be recommended. However, all out maxillo-mandibular expansion, particularly in the presence of a thin periodontal biotype, runs the risks of inducing an orthodontic movement of the teeth beyond the bone volume and, secondarily, inducing gingival recessions.

Another element of the debate is the possible effect of extractions on the volume of the airway passages: does the reduction of the length of the arch after extractions decrease the available space for the tongue and, consequently, the pharyngeal volume? A retrospective study³⁰ assessed and compared tridimensional pharyngeal modifications in patients treated, without extractions, or with extractions of four premolars. The volumes of the nasopharynx, of the oropharynx and of the area of maximal

pharyngeal constriction were measured by cone beam computed tomography (CBCT). The results showed no statistically significant difference between the two groups.

The authors concluded that the choice of treatment, with or without extractions, has no effect on the pharynx.

Nonetheless, this study involved patients during growth, whose average age at the beginning of treatment was in the range of 12.97 ± 1.15 years for the group treated by extractions, and 12.86 ± 1.74 years for the control group.

Moreover, for a patient at the end of growth, the good clinical judgment of the practitioner will make him consider it carefully before requiring the extraction of the maxillary premolars to mask a Class II malocclusion with retruded mandible. If there are risk factors for (OHAHS), implementing orthognathic surgery to advance the mandible, may be preferable to compensatory extractions.

Numerous orthodontic publications suggest protocols for treatment *without extractions*, that do not take into consideration the third molars. It is a truism to recall that the dentition consists of 32 teeth. Simple common sense requires that we plan for the therapeutic indication for extraction of permanent teeth, while taking into account the possibility of eruption of the wisdom teeth²⁰. Rather than save the premolars, treat crowding by pushing the teeth beyond the bone volumes, therefore exposing the patient to an increased risk of gingival recession, and practicing *in fine* the germectomy of the wisdom teeth, wouldn't it be better to extract

some premolars to correct crowding and facilitate the development of the third molars⁹ (Fig. 1 a to c, Fig. 2 a and b, Fig. 5 a to c, Fig. 6 a and b)?

Good clinical judgment also helps the practitioner choose the area between the first or second premolars as the extraction site. If the management of the anchorage and taking into account the facial typology allows it, the first premolars are generally preserved. This is because, in particular, of their greater coronal height that will ensure a better esthetic transition from the gingival cervical line between canines and molars. We could also choose to

extract them in case of severe crowding involving the risk of canine impaction, if the patient wishes to shorten the length of treatment (Fig. 1 to c), if their height is similar to that of the second premolars or for endodontic reasons (Fig. 5 a to c).

Finally, ever since Angle, no therapeutic method without extractions has managed to become the standard in any decisive way. This simple observation should persuade us to question whether we should totally abandon the therapeutic indication for the extraction of permanent teeth.

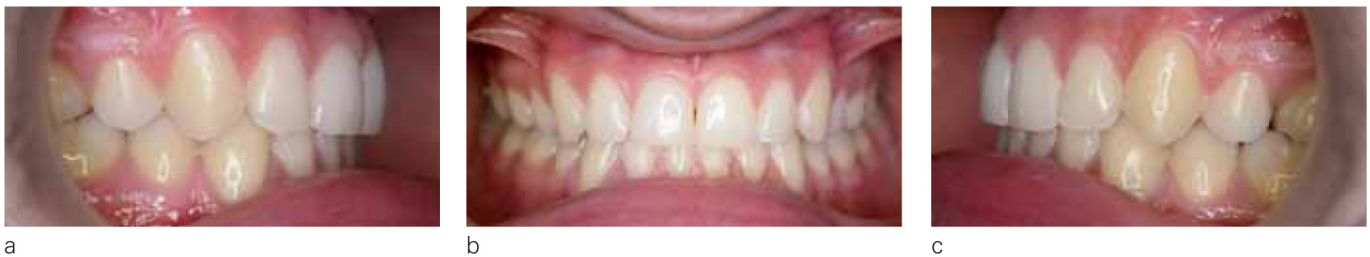

Figure 1

Intraoral buccal views (a) from the right (b) front (c) from the left, taken 6 years after the end of treatment for a Class II div. 2 malocclusion and ALD, with extraction of the first four premolars.

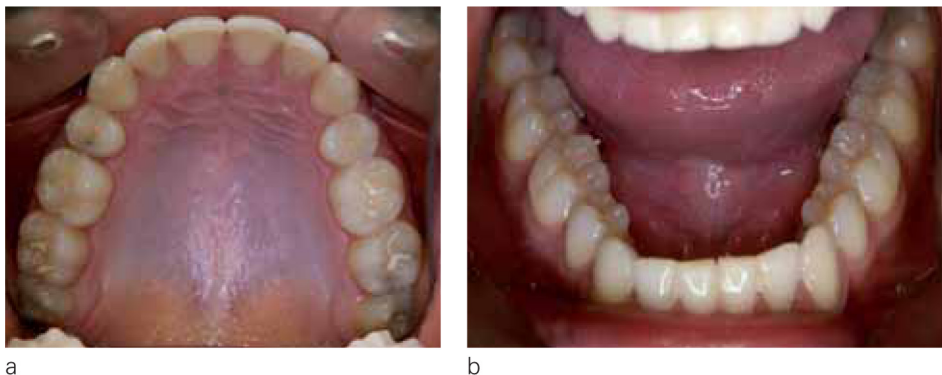


Figure 2

Intraoral occlusal views of the dental arches (a) maxillary and (b) mandible, taken six years after the end of treatment.

FACT-BASED APPROACH TO OFFSET ANY FALSE SENSE OF CERTAINTY

If it is important to retain one's critical judgment and good clinical reasoning, and it is just as crucial to allow the patient to benefit from the contributions of a fact-based approach that improve treatment.

When the superiority of a treatment is demonstrated, it is better if clinicians use it, with patients, factors and conditions all being equal⁶, of course. To not do this might be detrimental to our patients²⁸: research dealing with the evaluation of treatment results have, many times over, demonstrated that patients who receive treatment grounded in proven data have better results than those whose treatment is not^{21,36}.

Being open-minded, is indispensable for the development of scientific knowledge, and must take precedence for any therapeutic decision. Our patients have every right to the most effective therapies, whatever they may be. However, they also have every right to be informed of the difference between convictions and scientific facts⁴. An approach founded on facts makes it possible for the clinician to reconcile open-mindedness, prudence and circumspection, and therefore avoid getting bogged down in some delusional proselytism.

A fact-based approach allows the practitioner to increase his independence vis-à-vis the often partial opinions of "influential power figures". Given the fact that an opinion expressed with conviction is more attractive than a prudent interpretation of the few available data, some authors regularly question published

results. A fact-based approach puts at our disposal proven data in order to respond to their allegations.

We will take two examples of subjects of scientific debate that have significantly altered and advanced our initial beliefs.

The esthetic repercussions of extractions

We have to admit that a becoming smile is privileged in society and that the quest to esthetically improve the teeth and the face is the main initial motivation of patients.

Detractors of treatment by the extraction of permanent teeth argue that it causes, among other things, a flattening of the profile, a retrusion of the lips, and a reduction in the width of the smile. Their only substantiation for their argument is a few isolated clinical cases and the opinions of some authors^{17,19}.

The published data, even if the methodological quality is sometimes uneven, seem to negate these assertions:

- do extractions create a profile or a face "with extractions"?

A panel of orthodontists and seasoned dentofacial surgeons were unable, by simply performing an oral examination of these patients, to determine if they had benefitted from a treatment with or without extractions⁸ (Fig. 3, Fig. 7 a and b);

To illustrate why this was difficult, we can observe the profile of a patient (Fig. 3) after treatment of his Class 2 and ALD, with extraction of

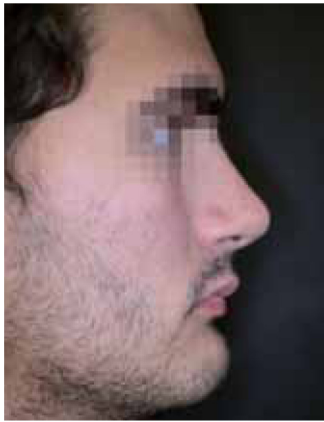

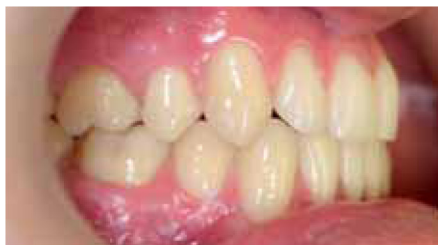Figure 3

Profile photo six years after the end of treatment. The shape of the lips is harmonious and the concavity of the profile is related to the nasal projection and the protruded chin.

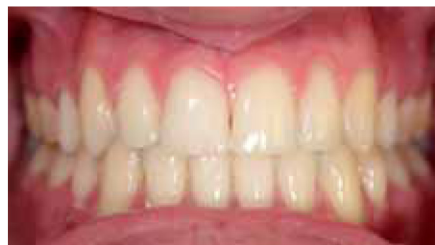


Figure 4

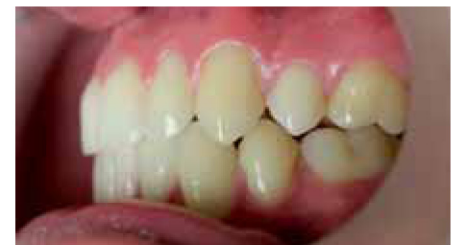Profile of a Greek statue from the 5th century B.C., presenting a retruded profile due to the projection of the nasal pyramid and the protruding chin.



a



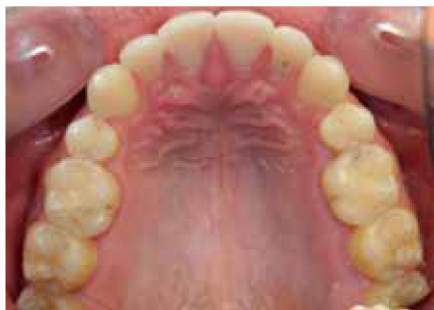b



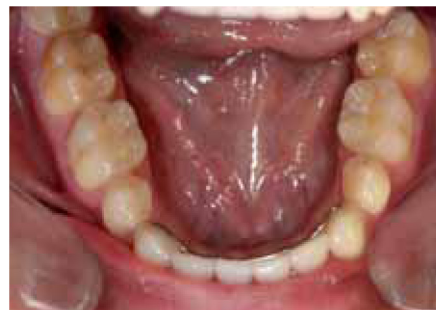c

Figure 5

Intraoral buccal photos (a) from the right, (b) front and (c) left, taken 5 years after treatment for a Class 2 malocclusion and ALD, with the extraction of four first premolars. Notice, a minor tooth alignment discrepancy near 25.



a



b

Figure 6

Intraoral occlusal photos of the dental arches (a) maxillary and (b) mandible, taken 5 years after the end of treatment.

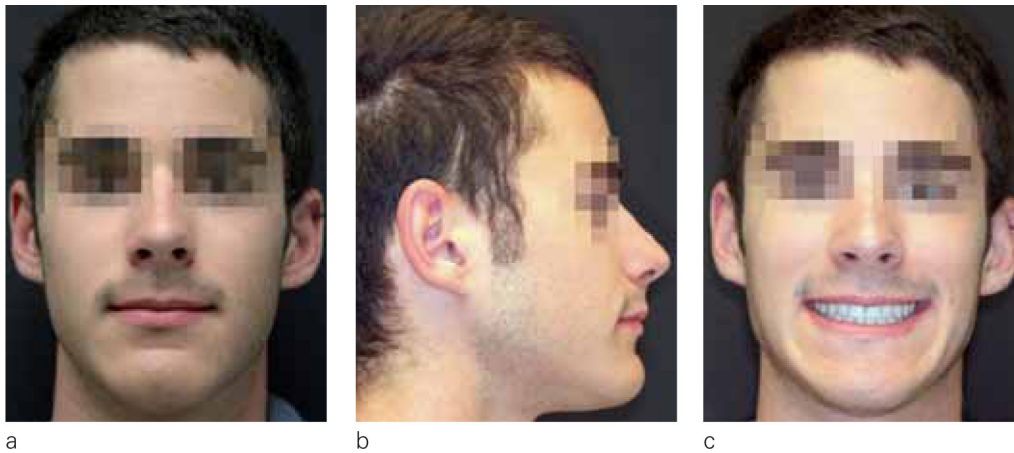


Figure 7

Photos (a) frontal, (b) profile and (c) frontal with an exaggerated smile, 5 years after the end of treatment. The esthetics of the face and of the smile have been preserved.

the four first premolars (Fig. 1a to c, Fig. 2a and b). His profile is retruded but the shape of the lips is harmonious. The retruded appearance is not a consequence of the extractions; the retrusion is in relation to the nasal projection and the protruding chin. The retruded profile would still have been observed even without any treatment, just like the profile of this Greek statue from the Vth century B.C. (Fig. 4) that obviously was not involved in any orthodontic treatment;

- does the extraction of maxillary teeth lead to a narrowing of the arches and a widening of the buccal corridors, that means along with the spaces, when smiling, between the most visibly distal buccal faces of the teeth and the labial commissures?

Data shows that this has nothing to do with it. Treatments by extraction does not induce any narrowing of the arches or widening of the buc-

cal corridors (Fig. 7c), whereas treatments without extractions create a slight expansion of the dental arches^{1,23};

- can the esthetic attractiveness of the smile be affected by the extraction of permanent teeth?

This does not seem to be the case. If treatment has been performed after a complete diagnostic work-up and meticulous planning, choosing to extract or not does not appear to affect the attractiveness of the smile of patients from a frontal view²⁴.

A study of seven characteristics of the smile demonstrates the absence of any deleterious effect from extraction of the four first premolars on the esthetics of the smile¹⁸.

The conclusions of these studies, indicating a general absence of adverse esthetic effects due to extractions, may surprise the clinician given that, for example, there are correlations between the retraction of the maxillary incisors, the retractions and

thickening of the upper lip, and the opening of the nasolabial angle^{2,32}.

This apparent contradiction can be explained if we notice that these publications include patients whose treatment by extractions was judged to have been *carried out successfully* (for example, *"if the treatment has been performed after a complete diagnostic work-up and meticulous planning²⁴"*, or whether, *"the decision to extract or not to extract, if it is not based on rigorous diagnostic criteria, seems to not to have³⁴"*). This seems to exclude, among other factors, an excessive cephalometric repositioning of the mandibular incisors (for example: *"if the objective of attaining a similar position for the incisors is respected, patients treated by extractions or without extractions³¹"*), and compensatory extractions to mask, in the area of occlusion, a significant skeletal imbalance caused by a Class II with mandibular retrognathia.

Obviously, the use of extractions is not synonymous with retrusion of the incisors or contraction of the arches. Their effect on the esthetic outcome, whether positive or nega-

tive, depends mainly on the choice of the extraction sites, the monitoring of the anchorage, the biomechanical management of the treatment and considerations concerning the possibility of ending up with unattractive facial features¹².

We would like to illustrate our discussion with the case of a young girl named Amélie, 9 year and 8 months old, who presented with a dental and skeletal Class II (Fig. 8 a to c, Fig. 9 a and b) and labial inclination of the mandibular incisors (Fig. 10 a and b, Fig. 11).

We have to choose between three therapeutic options:

- treatment with the extraction of four premolars, in order to attain the objective of repositioning the lower incisors. It might probably result in an unattractive flattening of the profile;
- combining orthognathic surgery to advance the mandible with extraction of the four premolars. This would make it possible to correct the labial inclination of the mandibular incisors and to optimize the esthetics of the profile.

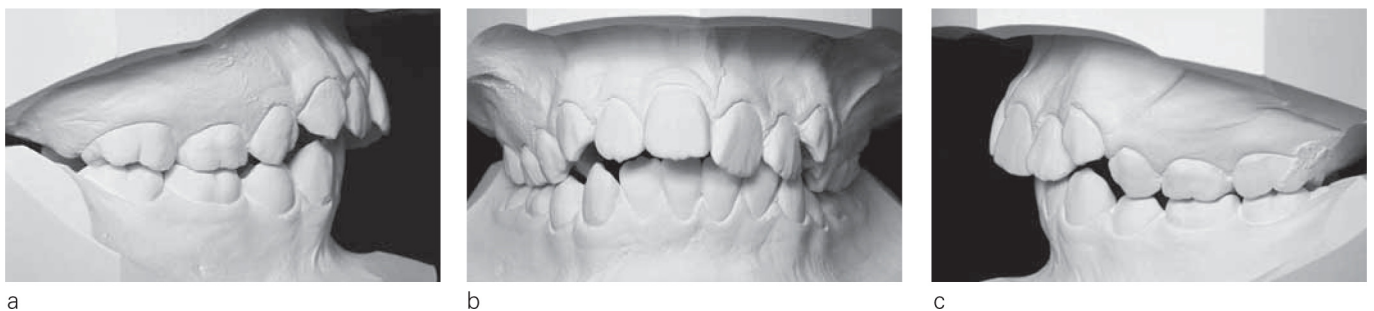

Figure 8

Buccal views of the casts before treatment, (a) from the right, (b) frontal and (c) from the left. The patient presents a Class 2 malocclusion with ALD.

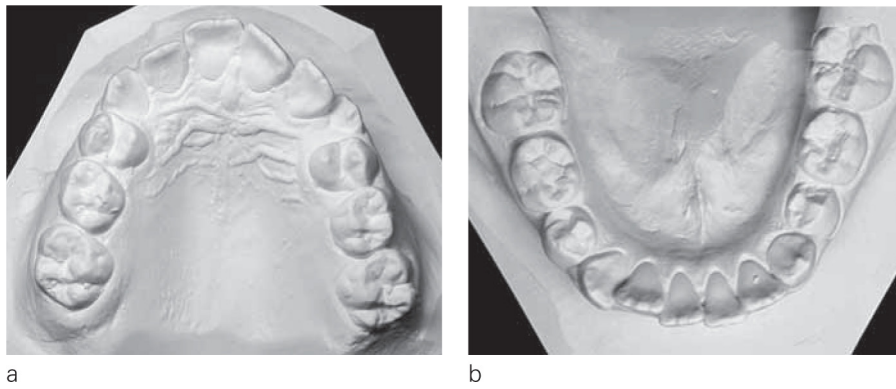


Figure 9
Occlusal views of the casts before treatment, (a) maxillary and (b) mandibular.

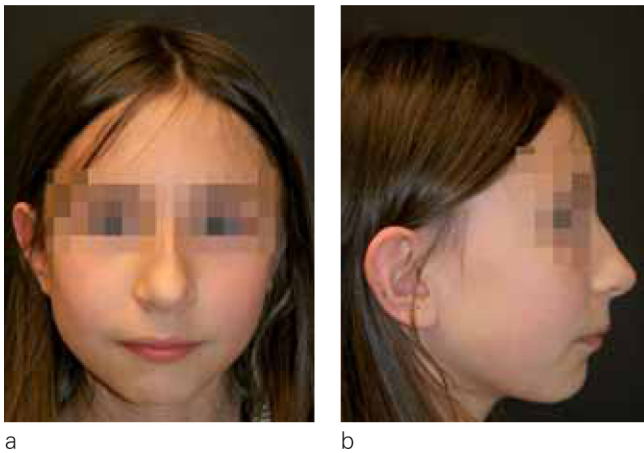

Figure 10
Photos (a) frontal and (b) profile before treatment.

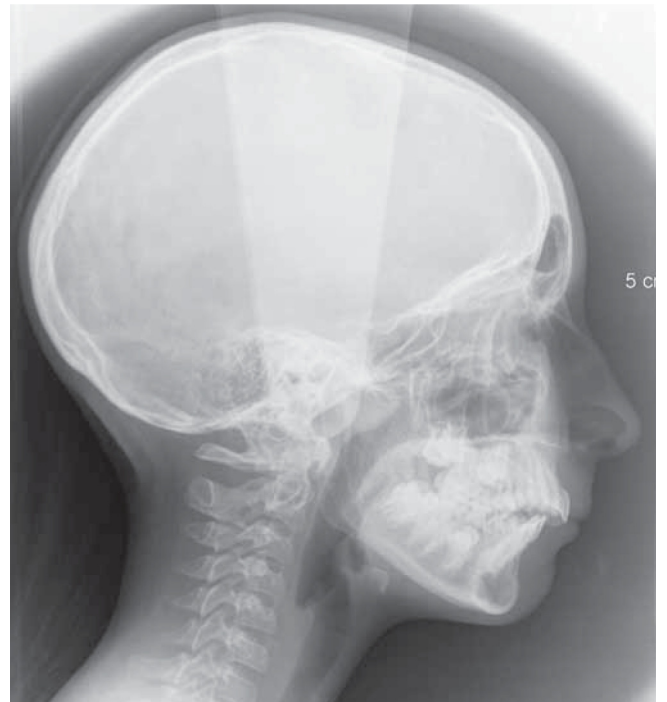

Figure 11
Cephalometric profile xray taken before treatment. The patient presents a skeletal Class 2 with mandibular retrognathia and labial inclination of the mandibular incisors.

If there are no stated indications of problems with sleep or risk factors for OHAHS for the patient, we have to consider the cost/benefit-safety risk of this therapeutic option ;

- treatment without extractions hoping for a favorable mandibular growth response, and testing it

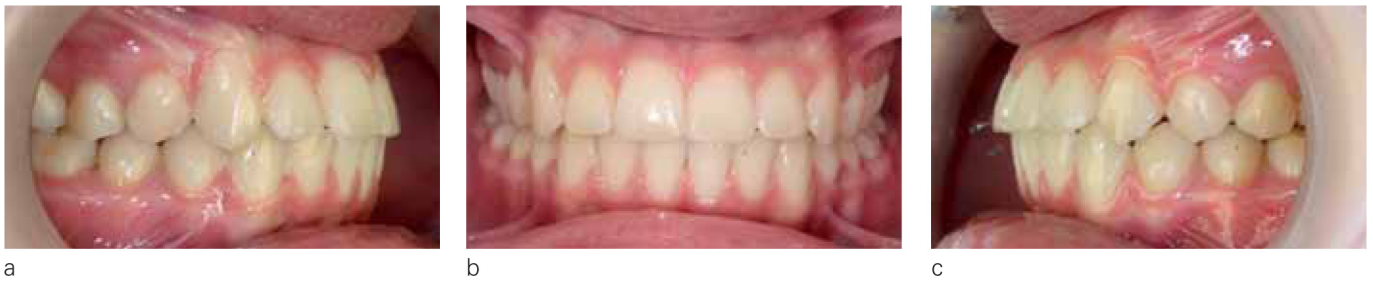

Figure 12

Intraoral buccal photos taken one year after the end of treatment, (a) from the right, (b) frontal and (c) from the left.

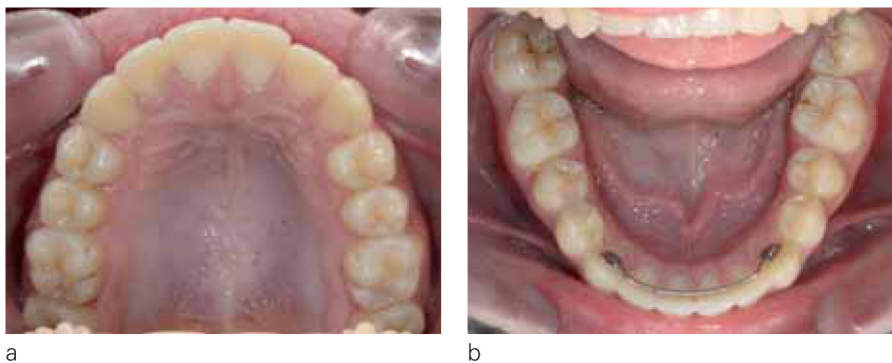


Figure 13

Intraoral occlusal photos of the dental arches taken one year after the end of treatment, (a) maxillary and (b) mandibular.

with an initial phase of orthopedic treatment.

We decided on this third option after presenting the three choices to Amélie and her parents (Fig. 12 a to c, Fig. 13 a and b).

After a treatment phase to align the arches using a quad helix and retaining leeway space with a lingual wire, the maxilo-mandibular growth differential was induced during a phase of orthopedic correction by using a functional and orthopedic device³. An orthodontic phase, was carried out with a multi-bracketted system and finishing and detailing

was next achieved with an elastofinisher. Amélie's growth response to therapy was favorable. This helped to preserve the esthetics of the face and of the smile (Fig. 14 a to c, Fig. 15), at the cost of a 5° labial inclination of the mandibular incisors (Fig. 16).

Are self ligating brackets effective?

We would like to take the example of another debate that has been going on recently in orthodontic journals : are self ligating brackets

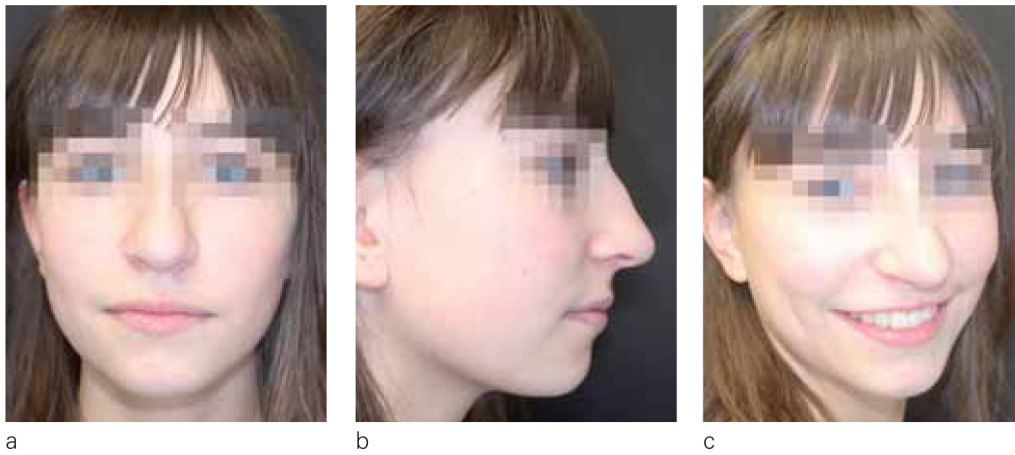


Figure 14
Photos (a) frontal, (b) profile and (c) three quarters, taken one year after the end of treatment.

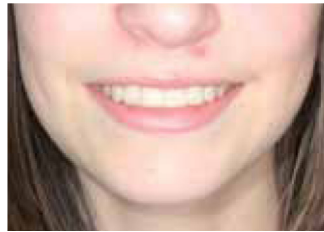


Figure 15
Frontal smile photo taken one year after the end of treatment.

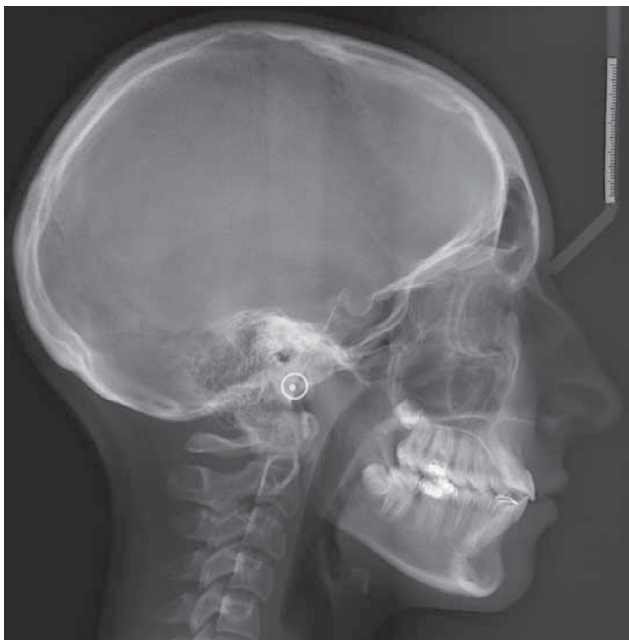

Figure 16
Profile cephalometric xray taken six months after the end of treatment.

effective, at the very least, but when they are used, do they succeed in reducing indications for the extraction of permanent teeth?

In the second part¹⁵ of the section “point/counterpoint” of the *AJODO* published in January 2013, the authors evaluated the claims advanced by the proponents of self ligating brackets as measured against published data. They report that no less than nine random clinical trials and two comprehensive reviews of the literature^{10,14} all show that the use of self ligating brackets does not increase therapeutic effectiveness, with regard to dental alignment or total length of treatment. With typical British humor, they concluded that: “*although technological advances may seem appealing, osteoclasts*

seem to be less impressed than clinicians.”

Dwight Damon self ligating brackets are among the most popular. Their inventor claims that they have the capacity to significantly decrease indications for extractions, pain and length of treatments. These assertions have recently been the object of a review of the literature³⁷. The authors conclude that the use of Damon brackets seems to allow for a reduction in work time for the orthodontist at the chair. On the other hand, there are no in-depth published data that make it possible to confirm that their use reduces the pain of the patient, shortens the length of treatment, achieves a more stable or better result in terms of esthetics or occlusion, or lessens the need for dental extractions.

FACTS AND CONVICTIONS

It must be noted that only a small number of our treatments are based on uncontested facts and that all the published data is far from being proven and undebatable as much as we might wish that it were⁵. Therefore, we have to manage as best as possible uncertainty. Often, we can only use as our sole source of information a few rare studies conducted with uneven methodological quality. Sometimes even, we can only rely on, using reserve and prudence, our experience and/or that of our collea-

gues. This is the whole realm of convictions that have some scientific legitimacy, as long as they are presented just as convictions.

The principle of *primum non nocere*, ethics¹³ and common sense and good judgment summon the orthodontist to inform the patient. An objective presentation founded on a cost-benefit-safety relationship of the various options for treatment will help the patient, and especially the parents, to make their decision.

THE SPECIAL EDITION – EXTRACTION VERSUS NONEXTRACTION

Now it will have been thirteen years since the *Dentofacial and Orthodontic*

Review dedicated an issue to the theme of extractions in orthodontics.

This special editions *extraction/nonextraction* is the first edition in a series of two, whose ambition it is to offer a synthesis of the present debate between the proponents and the detractors of the therapeutic indication for extractions.

Each author, was asked by the editorial committee of the *Dentofacial and Orthodontic Review* to participate in this initial special edition, and to shed light on a particular point of this debate.

M. Limme presents the facts that justify early interceptive management, which is actually etiopathogenic and includes myofunctional reeducation, as opposed to late treatment that may require extractions.

E. Lejoyeux reminds us that the Bioprogressive Concept has always recommended that we try to achieve an optimal highly individualized esthetic and functional outcome, rather than one based on standard values. A significant reduction in the use of extractions, along with the assurance of stable results, is the consequence of doing a comprehensive assessment of each patient, of choosing to treat early, of neutralizing dysfunctions in order to choose the ideal shape for the arch and of utilizing resources from functional and mechanical unlocking with the help of a segmented approach using a multi-bracketed appliance.

J. Cohen-Lévy and N. Cohen discuss the current state of knowledge pertaining to post-extraction healing in orthodontics. After a review of the mechanisms responsible for healing and the various complications, in the

area of the mucous tissues and the alveolar bone, they present the general and local factors implicated in cases that result in failure to heal. Their article also sets out techniques for preserving the alveolus, during the surgical procedure, as well as methods for regenerating tissue.

P. Baron explains the importance of using mini screw anchorage to shorten the length of treatment, achieve corrections in only one phase, and avoid extraction of premolars while maintaining the usual therapeutic objectives. He reports the main findings of pilot studies and presents clinical examples, that illustrate his therapeutic approach for crowding in cases of Class I, II and III.

M. Mujagic details the therapeutic impact of opting for extraction of a lower incisor, as it affects esthetics and occlusion. She lists the advantages and disadvantages of extraction. In the second part, she defines the decision-making criteria that help to ensure a satisfactory therapeutic outcome, by eliminating risks for opening gingival embrasures and for the appearance of an antero-posterior or transverse discrepancy.

The usual sections of the *Dentofacial and Orthodontic Review* create a central thread, that is both anticipated and instructive, between the various issues.

The heading *Clinical Case* hosts a report from J. Faure concerning the optimal treatment management of mechanical forces when the choice is extraction. He explains how to manage space, by therapeutically negotiating between the lack of anterior

and posterior space, to achieve an objective without sacrificing teeth. A clinical case illustrates his presentation.

Finally, J. Cohen-Lévy shares her *Radiological Reflections* on Eagle's Syndrome.

CONCLUSION

Whatever the recognized etiological factors may be, and irrespective of the measures put in place for prevention, arch length discrepancy persists²⁷, and the choice of a treatment protocol remains a delicate therapeutic decision.

If Aesop had been an orthodontist, perhaps he would have written that extractions are neither good nor bad

in and of themselves. They can have a positive or negative effect on the outcome of treatment, depending on the pertinence of their indication and the appropriate biomechanical management of extraction spaces.

We would like to thank Professor O. Sorel for the photographs that appear in Figure 4.

BIBLIOGRAPHY

1. Akyalcin S, Erdinc AE, Dincer B, Nanda RS. Do longterm changes in relative maxillary arch width affect buccal-corridor ratios in extraction and nonextraction treatment? *Am J Orthod Dentofacial Orthop* 2011;139:356-61.
2. Anderson JP, Joondeph DR, Turpin DL. A cephalometric study of profile changes in orthodontically treated cases ten years out of retention. *Angle Orthod* 1973;43:324-36.
3. Amat P. Contribution of a functional and orthopaedic splint to the treatment of Class II malocclusions. 103rd Annual Session of the American Association of Orthodontists 2003 May 2-6; Honolulu, Hawaii.
4. Amat P. What would you choose: evidence-based treatment or an exciting, risky alternative? *Am J Orthod Dentofacial Orthop* 2007;132:724-25.
5. Amat P. *Dentisterie fondée sur les faits : en omnipratique et en orthodontie*. Paris : Éditions CdP, 2012.
6. Bader JD. The fourth phase. *J Evid Base Dent Pract* 2004;4:12-5.
7. Bartala M, Boileau MJ. Conséquences occlusales et articulaires des extractions de prémolaires : revue de littérature. *Rev Orthop Dento Faciale* 2001;35:223-43.
8. Boley JC, Pontier JP, Smith S, Fulbright M. Facial changes in extraction and nonextraction patients. *Angle Orthod* 1998;68:539-46.
9. Bonne-Riahi S, Oueiss A, Faure J, Garnault G. Conservation sur l'arcade des troisièmes molaires dans les cas d'extractions de prémolaires : pronostic et modalités. *Rev Orthop Dento Faciale* 2005;39:367-88.
10. Chen SSH, Greenlee MG, Kim JE, Smith CL, Huang GJ. Systematic review of self-ligating brackets. *Am J Orthod Dentofacial Orthop* 2010;137:726.e1-18.
11. Damon DH. Treatment of the face with biocompatible orthodontics. In: Graber TM, Vanarsdall RL, Vig KWL (eds): *Orthodontics: Current Principles and Techniques*. St Louis: Elsevier Mosby, 2005;753-831.
12. De Brondeau E, Boileau MJ, Duhart AM. Impact esthétique des extractions. *Rev Orthop Dento Faciale* 2001;35:251-73.

13. Deniaud J, Béry A, Hervé C, Talmant J. Les extractions de dents saines permanentes en orthopédie dentofaciale : réflexion éthique. *Rev Orthop Dento Faciale* 2000; 34:629-48.
14. Fleming PS, Johal A. Self-ligating brackets in orthodontics. A systematic review. *Angle Orthod* 2010;80:575-84.
15. Fleming PS, O'Brien K. Self-ligating brackets do not increase treatment efficiency. *Am J Orthod Dentofacial Orthop* 2013;143:11-9.
16. Gebeile-Chauty S, Robin O, Messaoudi Y, Aknin JJ. Le traitement orthodontique peut-il générer des algies et/ou dysfonctionnements articulaires ou musculaires (ADAM) ? Une revue de littérature *Orthod Fr* 2010;81:85-93.
17. Ghafari J. Emerging paradigms in orthodontics – an essay. *Am J Orthod Dentofacial Orthop* 1997;111:573-80.
18. Ghaffar F, Fida M. Effect of extraction of first four premolars on smile aesthetics. *Eur J Orthod* 2011;33:679-83.
19. Gianelly AA. Treatment of crowding in the mixed dentition. *Am J Orthod Dentofacial Orthop* 2002;121:569-71.
20. Kandasamy S, Woods MG. Is orthodontic treatment without premolar extractions always non-extraction treatment? *Aust Dent J* 2005;50:146-51.
21. Krumholz HM, Radford MJ, Wang Y, Chen J, Helat A, Marciniak TA. National use and effectiveness of betablockers for the treatment of elderly patients after acute myocardial infarction. National Cooperative Cardiovascular Project. *JAMA* 1998;280: 623-9.
22. McLaughlin RP, Bennett JC. The extraction-nonextraction dilemma as it relates to TMD. *Angle Orthod* 1995;65:175-86.
23. Meyer AH, Woods MG, Manton DJ. Maxillary arch width and buccal corridor changes with orthodontic treatment. Part 1: differences between premolar extraction and non-extraction treatment outcomes. *Am J Orthod Dentofacial Orthop* 2014;145:207-16.
24. Meyer AH, Woods MG, Manton DJ. Maxillary arch width and buccal corridor changes with orthodontic treatment. Part 2: Attractiveness of the frontal facial smile in extraction and nonextraction outcomes. *Am J Orthod Dentofacial Orthop*. 2014 Mar;145:296-304.
25. Nance HN. The limitations of orthodontic treatment; mixed dentition diagnosis and treatment. *Am J Orthod* 1947;33:177-223.
26. Pollack B. Cases of note: Michigan jury awards \$ 850,000 in ortho case: A tempest in a teapot. *Am J Orthod Dentofacial Orthop* 1988;94:358-9.
27. Proffit WR, Fields HW Jr, Moray LJ. Prevalence of malocclusion and orthodontic treatment need in the United States: estimates from the NHANES III survey. *Int J Adult Orthodon Orthognath Surg* 1998;13:97-106.
28. Simonsen RJ. A plea for clinical trials-belief is not enough. *Quintessence Int* 1992;23:375.
29. Spahl T. Premolar extractions and smile esthetics. *Am J Orthod Dentofacial Orthop* 2003;124:A16-7.
30. Stefanovic N, El H, Chenin DL, Glisic B, Palomo JM. Three-dimensional pharyngeal airway changes in orthodontic patients treated with and without extractions. *Orthod Craniofac Res* 2013;16:87-96.
31. Stephens CK, Boley JC, Behrents RG, Alexander RG, Buschang PH. Long-term profile changes in extraction and nonextraction patients. *Am J Orthod Dentofacial Orthop* 2005;128:450-7.
32. Talass MF, Talass L, Baker RC. Soft-tissue profile changes resulting from retraction of maxillary incisors. *Am J Orthod Dentofacial Orthop* 1987;91:385-94.
33. Talmant J, Talmant JC, Deniaud J, Amat P. Du traitement étiologique des AOS. *Rev Orthop Dento Faciale* 2009;43:253-9.

34. Verma SL, Sharma VP, Tandon P, Singh GP, Sachan K. Comparison of esthetic outcome after extraction or non-extraction orthodontic treatment in class II division 1 malocclusion patients. *Contemp Clin Dent* 2013;4:206-12.
35. Wahlund K. Temporomandibular disorders in adolescents. Epidemiological and methodological studies and a randomized controlled trial. *Swed Dent J Suppl* 2003;164:2-64.
36. Wong JH, Findlay JM, Suarez-Almazor ME. Regional performance of carotid endarterectomy. Appropriateness, outcomes and risk factors for complications. *Stroke* 1997;28:891-8.
37. Wright N, Modarai F, Cobourne MT, Dibiasi AT. Do you do Damon®? What is the current evidence base underlying the philosophy of this appliance system? *J Orthod* 2011;38:222-30.