

Tips from the Trenches

Detection and retrieval of ferromagnetic foreign particles in cosmetically sophisticated regions

Tobias Helfen, MD*; Lorenz Wanke-Jellinek, MD; Viktoria Bogner, MD; Karl Georg Kanz, MD; Wolf Mutschler, MD; Florian Haasters, MD

BACKGROUND

Foreign bodies should be removed from skin lacerations and wounds during the primary wound management stage. Detection can be performed by various investigative techniques, including plain radiography, computed tomography (CT), ultrasonography, and metal detectors.¹⁻³ Removal of foreign bodies depends on the site of injury and the fragment material. Conventional retrieval is done by surgical exploration of the site of injury using additional incisions. This procedure may result in scar tissue and is unfavourable in cosmetically sensitive regions, such as the face, neck, or hands.⁴

Remaining particles can cause pain, neurologic symptoms, vascular compression, functional loss, abscesses or granulomas, infection, and cosmetic impairments, especially in uncovered regions of the body.⁵⁻⁷ Metallic artifacts are a contraindication for magnetic resonance imaging and may cause severe artifacts in CT.⁸

The following magnetic technique provides a minimally invasive alternative for removal and identification of ferromagnetic foreign bodies, especially in sensitive regions, such as the face or hand.

METHODS

In this technical procedure, a neodymium magnet (NeFeB; adhesive force 130 kg; magnetization N45; magnet alignment axial; total weight 0.82 kg; total volume 108 cm³; dimensions 60 × 30 × 60 mm; cost US\$91) was used to retrieve ferromagnetic bodies in the face, neck, upper arm, forearm, and hand. With this magnet, the attraction of iron, nickel, and cobalt is

possible.⁹ This technique should not be used when the patient has a pacemaker. The technical procedure is done in four steps:

Step 1: Initial wound irrigation and disinfection are performed to avoid contamination and to wash out superficial particles. Fluids should be collected to avoid a secondary skin contamination with retrieved fragments and to quantify foreign body retrieval (Figure 1).

Step 2: Affected skin areas are scanned with the magnet as close as possible to the skin (Figure 2). Repeated scanning in different directions is necessary due to the variable orientation of tracks of penetration. This step can be performed for open or closed wounds because the magnet can be applied without skin contact. Sterilization of the magnet is not mandatory. In cases where a sterile magnet is necessary, autoclaving is acceptable for most magnets using temperatures up to 130°C (266°F).⁹

Step 3: A systematic search through the region of interest is recommended after magnetic scanning is completed. If deeper metallic fragments are suspected, a sterile magnet is used for detection and applied directly on the skin. Subcutaneous metal fragments can be attracted through intact skin, the location of magnetic interaction can be marked, and small incisions can be used to retrieve the fragments.

Step 4: After final flushing, conventional radiography or CT can be employed to confirm complete retrieval.

DISCUSSION

We present a minimally invasive and low-cost technique for identification and removal of foreign bodies

From *Munich University Hospital, Department of General, Trauma, Hand and Plastic Surgery, Ludwig-Maximilians-University, Munich, Germany.

Correspondence to: Dr. Tobias Helfen, Munich University Hospital, Nussbaumstr. 20, Munich 80336, Germany; Tobias.Helfen@med.uni-muenchen.de

This article has been peer reviewed.

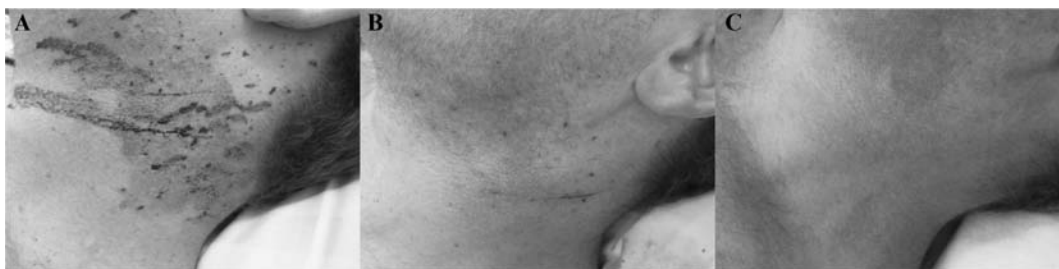

Figure 1. *A*, Findings on admission. Multiple small ferromagnetic bodies (0.2–2 mm) driven into the skin of the left neck and face of a young male worker when disconnecting a compressed air pipeline. *B*, After decontamination, wound irrigation, and magnetic scanning (steps 1–2), the amount of remained particles is marginal. *C*, Findings 6 weeks after the treatment. There is no scarring or remaining particles.




Figure 2. *A*, Total quantity of the retrieved ferromagnetic bodies attached to the neodymium magnet after steps 1 to 3. *B*, Separated large fragments > 1 mm.

when the particles are ferromagnetic. Only a few case reports describe the use of standard magnets to support the localization of ferromagnetic foreign bodies during surgical retrieval.³ NeFeB magnets have become widely available in recent years and are incorporated in various articles of daily life, for example, headphones and mobile telephones. Small NeFeB magnets as used in homes and offices can interfere with cardiac pacemakers.¹⁰

Not all metals (e.g., copper, magnesium, or nickel-cobalt-chromium alloys as in most stainless steels) are ferromagnetic. However, when materials are coated with chromic alloys yet have a magnetic core material for strength, a magnet can be used for retrieval.^{11,12} Objects consisting of iron, nickel, and cobalt, such as needles, staples, blades, and certain pins, are retrievable with a magnet.

We have detected and retrieved multiple ferromagnetic particles from many areas of the human body and highly recommend this technique for a variety of injuries. The skin lesions shown in Figure 1 were caused by an accident with a compressed air pipeline. In Figure 3, our procedure was used to retrieve foreign particles from the upper arm after the detonation of an explosive device. Another recommended application is the detection of subcutaneous ferromagnetic particles. Subcutaneous ferromagnetic nails, splinters, or pieces of wires can also be delivered magnetically through a small incision using the point of maximum magnetic attraction to incise the skin.

A step-by-step surgical procedure for identification and retrieval of single and multiple ferromagnetic foreign bodies is described. It has the potential to

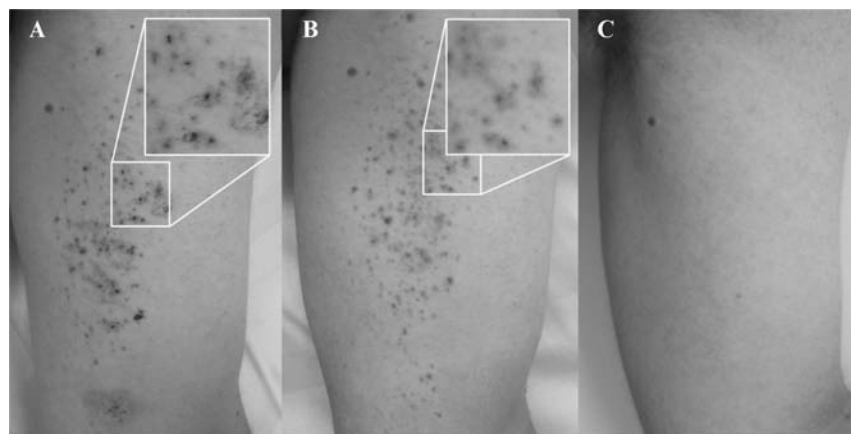


Figure 3. *A*, Upper arm after detonation of an explosive device with metallic particles scattered multiple intra- and subcutaneously after decontamination and irrigation (step 1). *B*, Findings after magnetic scanning (step 2). *C*, Findings 6 weeks after the treatment. There is no scarring or remaining particles.

reduce the use of radiography and to reduce scarring and additional surgical incisions in cosmetically demanding areas. We recommend this method for routine, first-line use to localize and retrieve ferromagnetic particles.

Competing interests: None declared.

Keywords: ferromagnetic, foreign body, localization, neodymium magnet, noninvasive, retrieval

REFERENCES

- Ginsburg MJ, Ellis GL, Flom LL. Detection of soft-tissue foreign bodies by plain radiography xerography, computed tomography, and ultrasonography. *Ann Emerg Med* 1990;19:701-3, doi:[10.1016/S0196-0644\(05\)82483-7](https://doi.org/10.1016/S0196-0644(05)82483-7).
- Abe K, Nakamatsu K, Beppu K, et al. Use of intra-operative ultrasonography to detect a small foreign body in the soft tissue of the upper lip. *Br Dent J* 1994;177:292-4, doi:[10.1038/sj.bdj.4808589](https://doi.org/10.1038/sj.bdj.4808589).
- Chin JT, Davies SJ, Sandler JP. Retrieval of a metallic foreign body in the neck with a rare earth magnet. *J Accid Emerg Med* 2000;17:383-4, doi:[10.1136/emj.17.5.383](https://doi.org/10.1136/emj.17.5.383).
- Owen-Shmith MS. *High velocity missile wounds*. London: Edward Arnold; 1981.
- Janzen DL, Tirman PF, Rabassa AE, et al. Lead “burso-gram” and focal synovitis secondary to a retained intra-articular bullet fragment. *Skel Radiol* 1995;24:142-4, doi:[10.1007/BF00198079](https://doi.org/10.1007/BF00198079).
- Peh WC, Reinus WR. Lead arthropathy: a cause of delayed onset lead poisoning. *Skel Radiol* 1995;24:357-60.
- Tekavcic I, Smrkolj VA. The path of a wounding missile along the spinal canal: a case report. *Spine (Phila Pa 1976)* 1996;21:639-41, doi:[10.1097/00007632-199603010-00020](https://doi.org/10.1097/00007632-199603010-00020).
- Shellock FG, Crues JV III. Safety of MRI in patients with metallic implants or foreign bodies. *Appl Radiol* 1992;11:44.
- Cakir B, Akan M, Yildirim S, et al. Localization and removal of ferromagnetic foreign bodies by magnet. *Ann Plast Surg* 2002;49:541-4, doi:[10.1097/0000637-200211000-00016](https://doi.org/10.1097/0000637-200211000-00016).
- Ryf S, Wolber T, Duru F, et al. Interference of neodymium magnets with cardiac pacemakers and implantable cardioverter defibrillators: an in vitro study. *Technol Health Care* 2008;16:13-8.
- Kuhn F, Heinemann K. A new permanent magnet for removal of intraocular ferromagnetic foreign bodies. *Klin Monbl Augenheilkd* 1991;198:301-3, doi:[10.1055/s-2008-1045969](https://doi.org/10.1055/s-2008-1045969).
- Kalmbach T, Lajos TZ. Retrieval of metallic objects from the pericardial cavity. *Ann Thorac Surg* 1988;46:484, doi:[10.1016/S0003-4975\(10\)64677-2](https://doi.org/10.1016/S0003-4975(10)64677-2).