

The 1981 Silversides Lecture:

The Symptomatology of Tumours of the Anterior Visual Pathways

W. I. McDONALD

Tumours of the visual pathways, though rare amongst the causes of blindness, are one of the most important disorders the neurologist encounters. Diagnosed early, they can often be cured; diagnosed late, disabling visual impairment is common.

Because the neurologist or ophthalmologist can come close to a definitive diagnosis by the exercise of his clinical skills alone and because effective treatment can so often follow, this branch of neurology has particular attractions. Jack Silversides, whom we honour today, is one of those thoughtful, compassionate physicians whose imagination has been captured by the opportunities which neuro-ophthalmology provides for helping patients and by the intellectual stimulation that comes from seeing confirmation by radiology and surgery of clinical predictions based on the logical application of a knowledge of anatomy, pathology and the natural history of disease.

For many physicians, neurology in general and neuro-ophthalmology in particular provide an additional stimulus — that of trying to understand the mechanism of the clinical disorders they see in their patients. In the past, mechanism in relation to our topic today has been comprehended either pathologically — that is, as a concern with the factors influencing the origin, growth and spread of tumours — or anatomically — that is, how tumours in particular locations produce characteristic deficits. We owe our diagnostic skills to the classical investigations within this framework by men such as Cushing, Traquair and Jefferson. But they had little to say about physiological mechanisms. Just how do tumours involving the visual pathways produce the symptoms and signs they did do? What happens to

nerve fibres when a tumour grows near or amongst them?

These problems have interested me increasingly over the past decade and in this lecture I want to discuss some of the questions raised by tumours affecting the optic nerves and chiasm. The first part of what I shall have to say will lie within the traditional framework. I shall have two themes, the first being the broad similarity in the patterns of visual loss with tumours at different sites; the second will be the feasibility of accurate localisation by recognising certain distinctive clinical features despite the fairly stereotyped nature of the visual symptoms. The latter part of the lecture will have a physiological orientation. I shall enquire how far the visual symptoms produced by these tumours can be explained by our present understanding of the pathology and disordered physiology of central nerve fibres.

REGIONAL SYMPTOMATOLOGY ORBITAL TUMOURS

The classical picture of progressive unilateral visual failure with proptosis is produced by a wide range of conditions. Tables 1 and 2 show the diagnoses in 1560 patients referred to the Orbital Clinic at the Moorfields Eye Hospital between 1969 and 1980. All

TABLE 1
CAUSES OF PROPTOSIS
*Data from the Orbital Clinic at the
Moorfields Eye Hospital, City Road*

CAUSE	N	%
Tumour	452	29
Dysthyroid Eye Disease	224	14
Trauma	156	10
Pseudotumour	102	7
Vascular Malformation	78	5
Infections and Infestations	52	3
Mucocoele and Pyocoele	44	3
Others	452	29
	1560	100

The Institute of Neurology, Queen Square and Moorfields Eye Hospital, City Road, London, England.

Requests for Reprints to: Dr. W. I. McDonald, Institute of Neurology, The National Hospital, Queen Square, London WC1N 3BG.

This paper was originally presented as the first J. L. Silversides Lecture in Toronto on May 28, 1981.

TABLE 2

*Types of tumour seen in Orbital Clinic,
Moorfields Eye Hospital*

	N	%
Meningiomas	60	13
- optic nerve 22		
- sphenoid ridge 26		
- others 12		
Cavernous haemangioma etc.	57	13
Cystic tumours (dermoids etc)	55	12
Lacrimal gland tumour	54	12
Lymphoma	46	10
Peripheral nerve tumour	42	9
Conjunctival and eyelid tumours	31	7
Fibro-osseous tumours	25	6
Optic nerve glioma	20	4
Metastases	20	4
Naso-pharyngeal carcinoma	16	4
Rhabdomyosarcoma	14	4
Intraocular melanoma	10	2
Fibro-xanthoma	1	.02
Myeloma	1	.02

patients were seen by Mr. John Wright and his team and most of those with tumours attended my clinic as well. Three cases will serve to illustrate the main types of clinical picture encountered with tumours which interfere with vision.

Progressive Visual Failure

One of the most common orbital tumours producing extrinsic compression of the optic nerve is cavernous hemangioma.

Case 1: A 39-year old woman reported that about a year earlier she had noticed transient episodes of blurring of vision. For some 9 months she had had persistent blurring of vision and over two months the right eye had increased in prominence. Examination revealed 2.5mm of axial proptosis on that side; Visual Acuity Right Eye (VAR) 6/9, Visual Acuity Left Eye (VAL) 6/5. There was an upper temporal quadrantic defect with an arcuate component. The fundus showed horizontal retinal folds radiating from the disc and involving the macula. The axial proptosis suggested that the tumour was contained within the muscle cone, the field loss that it was anteriorly located, and the retinal folds that it was abutting the globe. Surgery was delayed for some three weeks for personal reasons, during which time the acuity fell to 6/36. The predicted location of the tumour was confirmed by Professor Valentine Logue at operation. The acuity returned to 6/5.

The location of the tumour was accurately predicted from the physical signs in this patient. It is important to

remember however that cavernous hemangioma can arise at the apex of the orbit where it may produce slowly progressive visual failure without proptosis for a number of years. A central field defect is common under these circumstances.

Intrinsic tumours of the optic nerve are rare in adult life, but glioma is well known, if uncommon, in childhood. We have recently analysed the clinical picture in 17 patients with optic nerve glioma (Wright et al, 1980). Proptosis, alone or with other features was the commonest mode of presentation. Because most of the patients were young, complaints of loss of vision were exceptional, although squint sometimes appeared as a consequence of it. Examination revealed the expected findings for an intraconal optic nerve mass together with some more distinctive features. Von Recklinghausen's disease was present in somewhat more than half the patients. Tumour was occasionally visible ophthalmoscopically. Opto-ciliary shunt vessels, indistinguishable from those seen with meningioma, were seen in one case. Nine patients showed little change over the years, but eight showed clear signs of progression of the visual impairment or proptosis, sometimes within a matter of months of presentation. We concluded that surgery should be reserved for patients in the latter group.

Transient Visual Failure

A second class of visual distur-

bance is seen in patients with meningioma of the optic nerve sheath.

Case 2: A 37-year old man presented with a 7 week history of transient loss of vision on looking to the right. On examination the visual acuity was 6/6 bilaterally. There was an enlarged blind spot and a swollen disc on the right. When the patient looked to that side, the right pupil became dilated and fixed and he lost vision in that eye. On looking to the front again his sight and the pupillary reactions returned. Figure 1 shows the fluorescein angiograms taken at 20secs in the primary position (fig. 1a) and with the eyes fully deviated to the right (fig. 1b). Figure 1a shows the changes attributable to papilloedema and ischaemia of the optic nerve head and surrounding choroid on the temporal side. The retinal arterioles are well perfused. The fluorescein angiogram taken during abduction shows that there is almost no perfusion of the optic nerve head, the surrounding choroid and the retinal arterioles. These changes can account for the visual loss, but not in themselves for the pupillary dilatation. However the consensual reflex was abolished in the abducted position. It can be inferred that this efferent defect was due to transient ischaemia of the ciliary body. At operation, Mr. John Wright found an optic nerve sheath meningioma. Although this clinical picture is most commonly seen with optic nerve sheath meningioma, we have seen it recently with an optic nerve glioma, and with a granular myoblastoma of the medial rectus muscle. Presumably in each case the ophthalmic artery was occluded as a result of relative restriction of movement of the vessel in relation to the tumour.

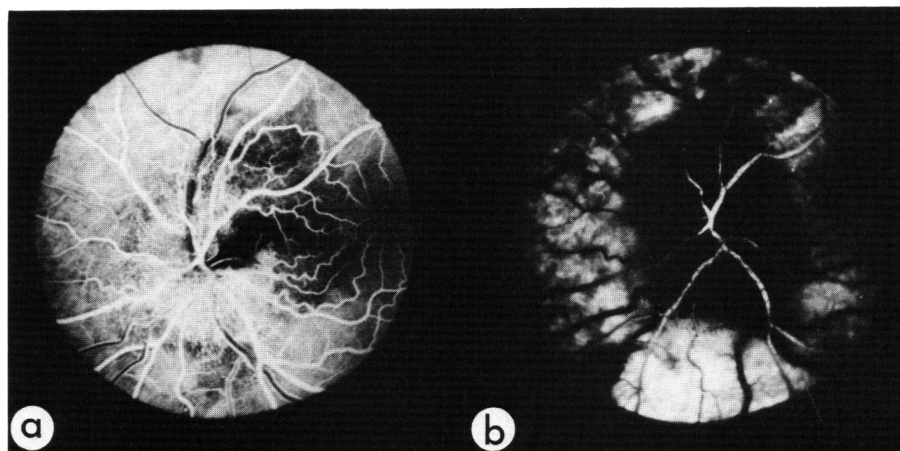


Figure 1a — Fluorescein angiogram 20 seconds after injection with the eye in the primary position.
b — Fluorescein angiogram in the same eye after the same interval (20 seconds) but with the eye abducted. There is virtually no perfusion of the retinal vessels. (By courtesy of Mr. M.D. Sanders.)

COMPRESSION OF THE OPTIC NERVE IN THE OPTIC CANAL

Progressive Visual Failure

Nasopharyngeal carcinoma occasionally causes progressive visual failure.

Case 3: A 48-year old man presented with an 18-month history of diplopia and numbness of the right side of the face. For three months there had been progressive deterioration of vision in the right eye, and right ptosis. For two months there had been increasing prominence of that eye. On examination there was 6mm of proptosis on the affected side. The visual acuity was reduced to counting fingers and there was partial involvement of the right third, fourth, fifth and sixth cranial nerves. VAL 6/6.

Tomograms of the optic canals revealed dilatation and foreshortening of the optic canal on the affected side, medial bowing of the lateral wall of the ethmoid sinus and evidence of a soft tissue mass at the apex of the orbit. Biopsy confirmed the presence of a carcinoma of the nasopharynx. Radiotherapy produced some improvement. Involvement of the third to the sixth cranial nerves on the same side as the visual loss gave a clear clinical indication that the cause of the visual failure was located in the region of the orbital apex.

and recurred approximately once a month. For two years he had noticed a horizontal strip of blurred vision across the middle of the left eye field in association with severe attacks of pain. The pain had been increased by eye movement. A plain x-ray on admission to the National revealed that the floor of the pituitary fossa was eroded except in its anterior part. A CT scan showed pathological attenuation throughout the sphenoid and ethmoid sinuses. A reconstructed view of the optic canal showed no evidence of a bony component in the medial wall. The latter observation is interesting in the light of the description by Young (1924) of the optic canal in 30 sphenoids dissected at post mortem. He found that four had hiatuses in the wall of the canal, one having "actually more hiatus than bone". The optic nerve in such cases would be separated from the sinus and its contents only by its dural sheath. The present patient was subsequently explored and found to have a sphenoid sinus mucocoele associated with evidence of chronic infection. The probable explanation for the recurring episodes of reversible visual loss in this patient is intermittent compression of the optic nerve in its defective canal. The alternative explanation of infection spreading into the nerve itself is unlikely in view of the rapid spontaneous remissions.

COMPRESSION OF THE INTRACRANIAL OPTIC NERVE

Progressive Visual Failure

Progressive visual loss is the common mode of presentation of meningiomas arising in the anterior fossa (where they are often betrayed clinically by anosmia), the sphenoidal wing (where they may produce proptosis) and of the jugum sphenoidale. I have seen a patient with a tumour in the latter site present with remitting visual loss.

Remitting Visual Failure

Case 5: A 49-year old woman presented in June 1977 with a month's history of blurring of vision which began acutely while watching television. When seen in the casualty department the visual acuity on the right was 6/18. Eight days later when she was reviewed in the clinic, the acuity had fallen to 6/24. The optic discs were normal but there was a right relative afferent pupillary defect. A patchy central scotoma was charted a month later. A diagnosis of optic neuritis was made and she subsequently improved spontaneously. When reviewed in March 1978 the original diagnosis of optic neuritis appeared to be confirmed by the observation of a

pale right optic disc and a substantially delayed visual evoked potential (153msec right, 104msec left); VAR 6/9, VAL 6/6. She remained well for a further 21 months. In December 1979, she again developed increasing blurring of vision in the right eye. She did not return to the clinic however until June 1980. On examination; VAR 6/60, VAL 6/5. The right optic disc was pale and the left normal. There was an extensive field loss on the right with only a portion of the nasal field being spared. A plain skull radiograph was normal. Because of the unusual history of progressive visual deterioration following an episode of what appeared to be optic neuritis, a CT scan was carried out which showed an enhancing mass in the region of the jugum. The tumour which was removed by Professor Lindsay Symon proved to be a meningioma. As is so often the case with meningiomas compressing the intracranial optic nerve, there was no recovery of sight.

COMPRESSION OF THE OPTIC CHIASM

Progressive Visual Failure

Progressive visual loss is of course commonly seen with tumours in the sellar and parasellar regions. Two distinct classes of symptoms — those due to slipping of the visual fields and post-fixational blindness (Kirkham, 1972) — may give the clue to localisation as in the following case.

Case 6: A 44-year old woman had noticed 2 years previously white, shiny "flashing lightning" in episodes lasting a few seconds. The flashes appeared to be in both eyes, right more than left, and sometimes seemed to move from the left eye to the right eye. They were unrelated to eye movements. Her right vision deteriorated gradually during the year before admission and she noticed a tendency for words to run together while she was reading. There were no endocrine symptoms. Examination revealed that the right visual acuity varied from 6/18 to 6/36 on different occasions over a matter of a week or two. VAL 6/5. The right optic disc was pale and there was a right afferent pupillary defect. The visual field examination was difficult, because of poor co-operation but there was an obvious central defect on the right which broke out to the periphery both supero-temporally and nasally. Although the field of the left eye appeared to be normal to testing on the Goldman perimeter and on the Bjerrum screen with a red stimulus, there was clear evidence of post-fixational blindness on formal testing; two white objects placed side by side at a dis-

Remitting Visual Failure

I have not seen spontaneously remitting visual failure in association with a neoplasm in this region, but through the courtesy of Professor John Marshall I have seen recently a patient who had intermittent visual failure associated with mucocoele of the sphenoid sinus.

Case 4: A 39-year old man was referred for admission to the National Hospital, Queen Square having been seen at another hospital with a seven-day history of pain in the left eye, increased by eye movement. For six days there had been increasing blurring of vision on that side. Examination at the referring hospital had revealed VAR 6/6, VAL 4/60. There was a left central scotoma and a left relative afferent pupillary defect. The optic discs were normal. Over the course of the 13 days before the patient was admitted to hospital, the pain subsided and the visual acuity returned to 6/5 bilaterally. The visual fields were then normal. Closer enquiry revealed that he had had episodes of pain affecting the left eye for some 3½ years. The pain was severe and sometimes accompanied by nausea. The episodes lasted 7-10 days

tance of about 2 feet were clearly seen but when the patient fixated on one and the other was moved further away, the latter disappeared. A VEP examination with half-field stimulation (Dr. A. M. Halliday) showed an abnormality in the left temporal field, in addition to a severe abnormality from the right eye. A skull x-ray showed evidence of erosion of the floor of the pituitary fossa and a CT scan revealed a uniformly enhancing mass expanding the pituitary fossa and extending into the chiasmatic cistern. She was transferred to the care of Professor Michael Besser at St. Bartholomew's Hospital. The basal prolactin levels were increased (1355 mU/l; upper limit of normal less than 360mU/l) but the secretion of other hormones was normal. A diagnosis of a prolactin secreting pituitary tumour was made and it was decided to treat her medically with a dopamine agonist (CU32 - 085, Sandoz). On discharge 3 weeks later the visual acuity had improved to VR 6/18 and VL 6/6.

The phosphenes experienced by this patient (and by Case 8 below) were not precipitated by eye movement, unlike those commonly associated with acute optic neuritis (Davis et al, 1976). Such spontaneous visual phenomena have been described, though rarely, in association with tumours in the chiasmatic region, but are of poor localising value (Weinberger and Grant, 1940).

Neighbourhood symptoms due to involvement of the third to the sixth cranial nerves and the cavernous sinus or of the hypothalamus producing disorders of endocrine function, growth and sexual development provide additional clinical help in localisation.

Remitting Visual Failure

Case 7: A 29-year old man presented in 1974 with a history that about a month previously he had developed blurring of vision of the left eye which increased over the course of about 24 hours and was accompanied by slight headache. After three weeks there was some improvement but when he was first seen the visual acuity was still reduced to hand movements on the left. There was a central scotoma, a relative afferent pupillary defect and a normal optic disc. VAR was 6/6, VAL-hand movements only. He had experienced a similar episode three months before the original presentation, but because he had made an apparently complete recovery, had not sought medical advice. He continued to improve, but some five months later

presented again with a history of visual deterioration accompanied by pain in the left eye over a three or four-day period. Two days before he was seen he had developed blurring of vision in the right eye. Examination showed VAR 6/6, VAL, counting fingers. The right optic disc showed early swelling and there was an inconstant upper temporal quadrantic field loss. Skull x-ray and CT scan were normal. A visual evoked potential examination revealed no response from the worse affected eye. From the less affected eye there was no delay in the mid-line occipital channel but an asymmetrical distribution of the evoked potential across the lateral channels and the wave form was altered (see fig. 5 by Halliday et al, 1976). These features which are commonly found with tumours in the chiasmatic region (Halliday et al, 1976) led to his having a pneumoencephalogram which revealed a mass. The tumour proved to be a craniopharyngioma. It was successfully removed by Professor Lindsay Symon and the visual acuity and visual evoked potentials returned to normal.

This patient, when first seen, had the typical clinical picture of optic neuritis but the clue later to the correct diagnosis was the presence of two of the less common findings in that condition — involvement of the second eye without a central scotoma and the absence of a delay in the visual evoked potential but an asymmetry in its distribution and alteration in its wave form. It is important to emphasize however that none of these features can distinguish with certainty between optic neuritis and tumour: even a long delay is not a completely safe guide, as Case 5 illustrates.

SUMMARY

Let me summarise this regional account of the symptomatology of tumours of the anterior visual pathways by emphasizing three points. First, while the most common mode of presentation is progressive visual failure, intermittent visual loss occurs sufficiently often to lead to diagnostic confusion. The clue to the correct pathological diagnosis comes from alertness to a discrepancy in the history, examination and investigations, no single feature of which is specific. Secondly, localisation of the tumour can usually be inferred from the clinical features, especially the visual fields, but also from the

manifestations of involvement of neighbouring structures. Thirdly, the visual symptoms themselves fall into two classes. The more important is that of visual loss which is usually slowly progressive but occasionally rapid and rarely abrupt. It sometimes remits spontaneously as in the transient loss associated with optic nerve sheath meningioma or in the optic neuritis-like syndromes. Recovery often follows surgical decompression, the completeness being influenced by the severity and duration of the visual loss and by the location and pathological nature of the tumour (Symon & Jakubowski, 1979). The second class of symptom is that of spontaneous visual phenomena.

MECHANISM

That there is a problem about mechanism was recognised by Thomas Hope when he gave "An Account of a remarkable Cure performed on the Eye of a young Woman in Scotland" in December 1744. This girl had had an orbital tumour for some seven years. It was removed and the patient, having had poor vision in the affected eye, made a remarkable recovery. Summing up, he said "it is true that while the optic nerve was in its state of extension, the sight was impaired; but after seven years extension, how it came to recover itself in a month's time, without any alteration in the sight but for the better, I leave to the speculation of the curious" (Hope, 1744).

Speculation it has largely remained — and little enough of that — for the ensuing 240-odd years. Most contemporary textbooks give little consideration to the origin of symptoms. Jefferson (1945) had obviously thought about the problem. In his Doyne Lecture to the Oxford Ophthalmological Congress in 1945 he discussed at length the Foster Kennedy syndrome. He concluded:

"Clearly the cause of the scotoma and of the atrophy is plain compression, and most ophthalmologists are agreed upon the special vulnerability of the macular fibres, on which Traquair has written. No doubt time will bring more accurate expositions of these macular fibre blocks if it has not already begun to do so obliquely

in the work of Erlanger and Gasser who have demonstrated selective blocking of the different sorts of impulses in nerve tissue.”

Erlanger and Gasser's work which was on peripheral nerve provided a generation later the basis for understanding some of the phenomena of peripheral neuropathy, but it is only recently that some of the basic questions about mechanism of symptom production in tumours of the central nervous system have been tackled. Ultimately, the symptoms depend on alterations in the properties of the nerve fibres and their connections. It is at this level that I want to consider the origin of the symptoms we have been considering.

Pathology of Compression

It is first necessary to return to pathology. Almost all the voluminous literature on tumours of the visual pathways deals with the neoplasms themselves and not with the nerve fibres they affect, interference with which causes the visual symptoms. Clifford-Jones, Landon and I have adopted an experimental approach to the problem (Clifford-Jones et al, 1980). Controlled incremental compression of the optic nerve in the cat was achieved by implanting a silicon balloon alongside it in the orbit. The balloon was connected by a fine plastic tube to a reservoir implanted subcutaneously in the back. At weekly intervals a small volume of radio-opaque

dye was injected into the reservoir. The resulting enlargement of the balloon was monitored radiologically. By choosing an appropriate volume and time course it was possible to achieve significant compression without severe visual loss but with an alteration in pupillary response and sometimes papilloedema.

Fig. 2 shows the types of abnormality seen in the nerve fibres. Some underwent Wallerian degeneration. Others showed selective demyelination with preservation of axon continuity. The proportion of each type of change and the distribution of it in the cross section of the nerve varied, but in the conditions of these experiments demyelination usually predominated. Oc-

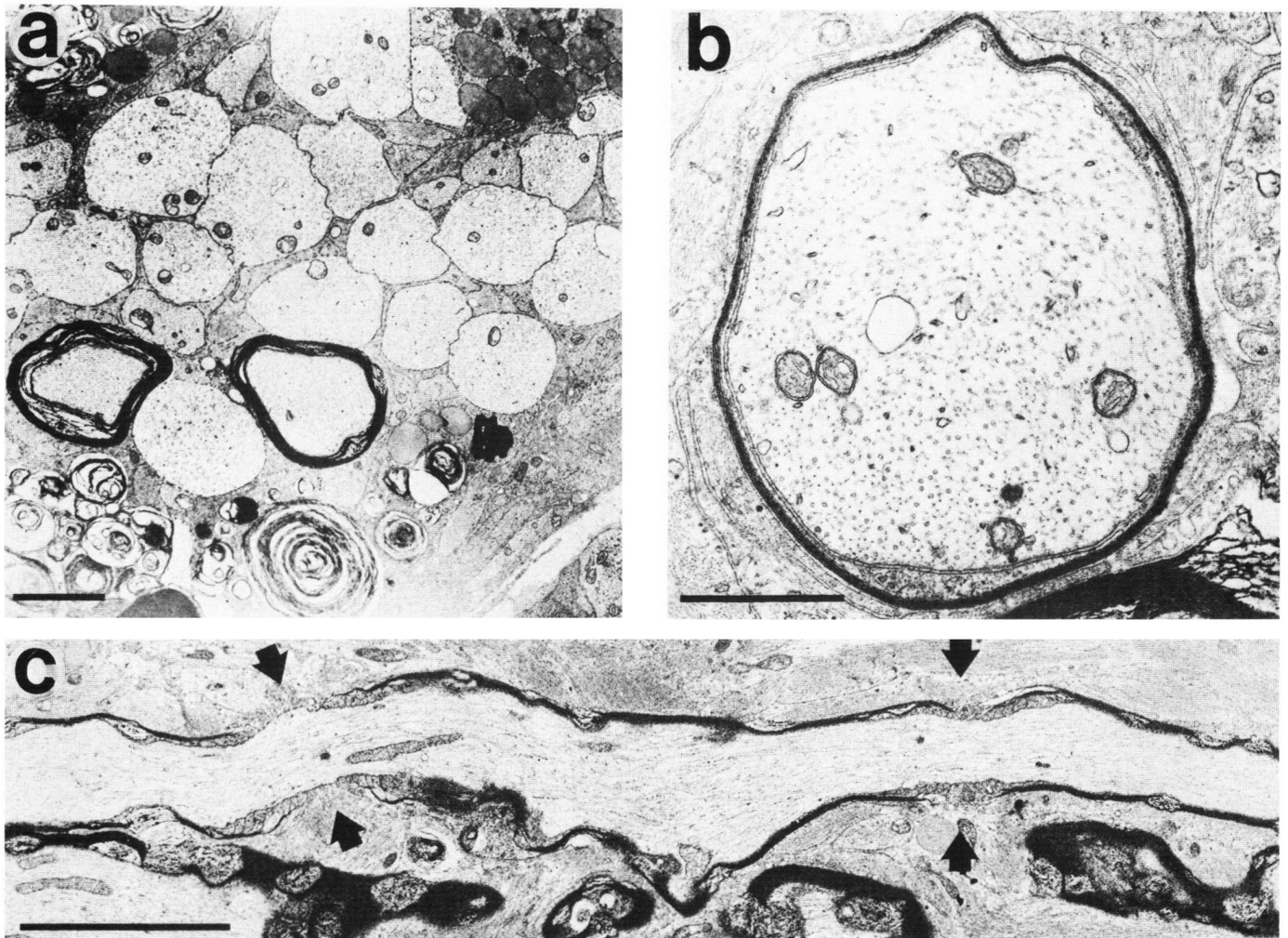


Figure 2a — Transverse section of cat optic nerve one week after compression by an inflated balloon. Note the demyelinated axons and myelin debris. Calibration bar $2 \mu\text{m}$.

b — Electron micrograph of an axon with an inappropriately thin myelin sheath from an optic nerve compressed for 5 weeks. The complete spiral of compact myelin strongly suggests that the fibre is remyelinated. Calibration $1 \mu\text{m}$.

c — Longitudinal section from the same nerve as that in fig. 2b. An abnormally short internode characteristic of remyelination is indicated by the arrows. (From Clifford-Jones et al., 1980.)

asionally it was diffusely distributed throughout the cross section of the nerve, although in all cases apparently normal myelinated fibres were seen scattered amongst the demyelinated fibres.

A description of demyelination is absent from all accounts of optic nerve compression that I have been able to find. It is however recorded by Holmes (1906) in a paper on compression of the human spinal cord. Since the structure of central nerve fibres is similar in spinal cord and optic nerve, it is probable that chronic compression of the optic nerve in man produces demyelination which, if the effects are similar to those observed in our experiments, will occasionally be diffuse. This suggestion is supported by the occasional observation of a substantial delay in the visual evoked potential, as in Case 5.

After five weeks of experimental compression a new appearance was seen: abnormally thin myelin around intact axons (fig. 2b and 3). Electron microscopy showed that the appearances fulfilled criteria for remyelination (Harrison et al, 1972). Longitudinal sections showed the presence of short internodes which are characteris-

tic of remyelination in the central nervous system (fig. 2c) (Gledhill et al, 1973; Harrison et al, 1975; Blakemore and Murray, 1981). It is noteworthy that remyelination of the demyelinated fibres commenced while compression was still present and that it was seen at all durations of compression examined (up to 5 months). The majority of demyelinated axons showed evidence of remyelination.

Physiological Consequences of Remyelination

The next question to consider is whether these new, thin, short internodes are capable of restoring conduction. Smith, Blakemore and I have examined this question in the spinal cord where critical studies of the properties of nerve fibres are easier than in the optic nerve (Smith et al, 1981). We did not use compression, but the lesion produced by the direct micro-injection of lysophosphatidylcholine which produces demyelination followed by remyelination morphologically indistinguishable from that following compression (Blakemore et al, 1977), has the advantage that it is easier to control. Two pairs of stimulating electrodes were implanted over the

posterior columns in the thoracolumbar region of the cat. Recordings of antidromic compound action potentials were made from the saphenous nerve in the thigh. After the responses had been stable for several weeks, an injection of lysophosphatidylcholine was made between the two pairs of stimulating electrodes. The results of a typical experiment are shown in fig. 4. Three days after the injection the compound action potential was greatly reduced in size. That this was due to conduction block was confirmed by direct recording from the spinal cord. Remyelination commenced at approximately two weeks and at this time there was evidence of restoration of conduction in some fibres. As remyelination proceeded, increasing numbers of fibres conducted through the lesion, and the response became stable after about three months. These experiments suggest a mechanism by which recovery of sensory function could occur in lesions dominated by demyelination and remyelination. But as we have seen some of the experimentally compressed nerves contained a significant amount of Wallerian degeneration. That the same is true for compression of the optic nerve in man is shown by the ophthalmoscopic evidence of retinal nerve fibre loss in many cases. Such patients may nevertheless show some recovery, occasionally to a quite striking degree. We must therefore consider the prospects for recovery following Wallerian degeneration.

Recovery after Wallerian degeneration

Jacobson, Eames and I examined this question in lesions of the visual pathways in the cat (Eames et al, 1977; Jacobson et al, 1979). The animals were trained to recognise gratings. We selected a range of spatial frequencies and each day measured the percentage of positive responses to each. After the response rate had been stable for several months a partial destructive lesion was made stereotactically in the intracranial optic nerve and adjacent parts of tract and chiasm. In the experiment illustrated in fig. 5 a subsequent count of the surviving nerve fibres showed that 77% of the fibres from one optic nerve had been destroyed. The

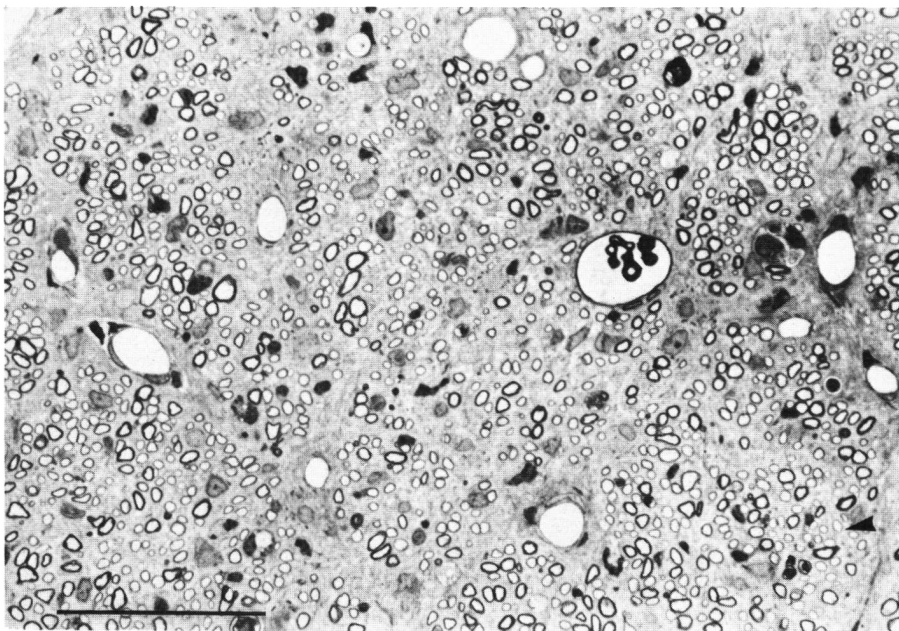


Figure 3 — Transverse section of cat optic nerve five weeks after initiating incremental compression with a balloon. There is some nerve fibre loss attributable to Wallerian degeneration. Around some surviving axons there are inappropriately thin myelin sheaths. Calibration 50 μ m. (By courtesy of Dr. R.E. Clifford-Jones.)

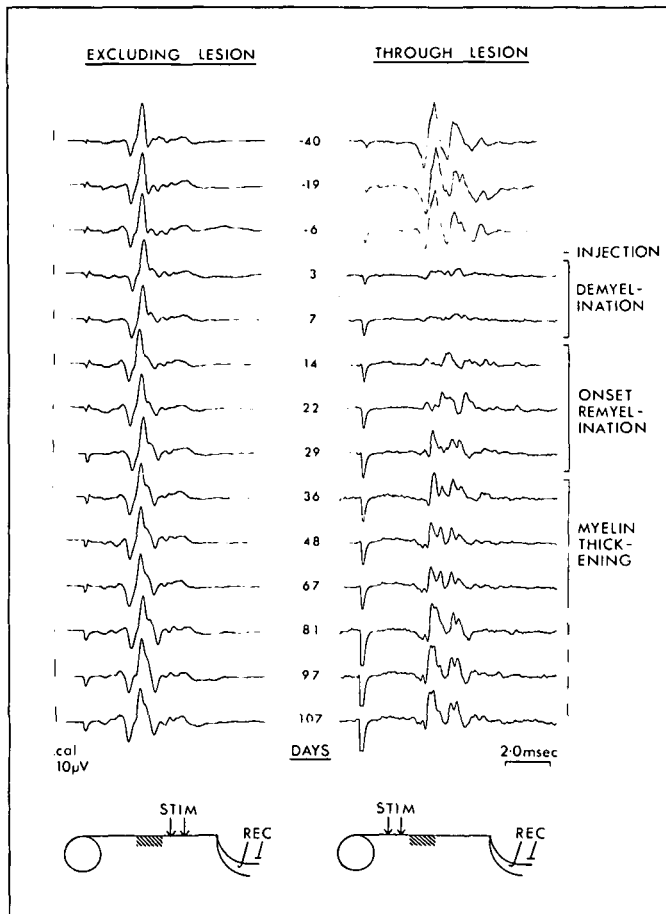


Figure 4 — Compound action potentials recorded from the saphenous nerves at different times during the development of a focal demyelinating and remyelinating lesion in the posterior columns induced by the direct micro-injection of lysophosphatidylcholine. To compensate for variables at the recording site the gain on each control response has been adjusted so that their peak-to-peak amplitudes are equal. The corresponding rostrally-evoked response had been adjusted by the same factor; each was recorded at 3.3 times the gain of its control. The intervals before and after injection of 1.5 to 2 microlitres of 0.8% lysophosphatidylcholine in saline are given in days. Negativity at the active electrode is recorded as an upward deflection. (By courtesy of Dr. K.J. Smith.)

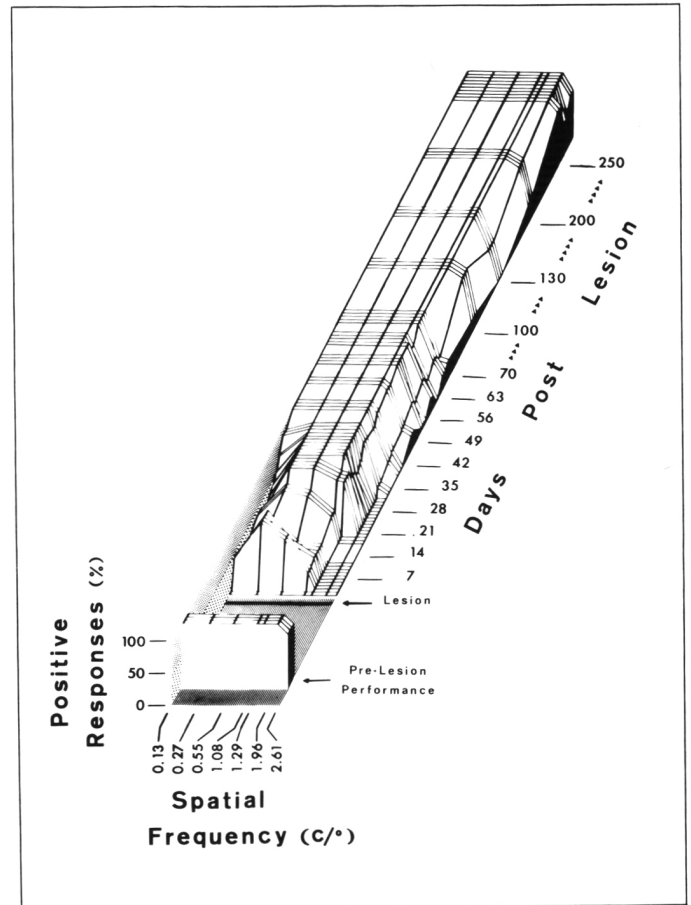


Figure 5 — Frequency-of-seeing curves for a cat in which a predominantly degenerative lesion had been induced in the right optic nerve and adjacent parts of the optic chiasm and optic tract by the stereotactic injection of diphtheria toxin. x axis - spatial frequency (c/degree); y axis - per cent correct responses; z axis - time before and after induction of the lesion. (From Jacobson et al., 1979.)

percentage of positive responses (y axis) to each grating (spatial frequency in cycles/degree on x axis) at increasing times after the operation (z axis) is shown. After four days the ability to recognise medium-sized stripes returned; during the next two weeks larger stripes were discriminated but recovery of the ability to discriminate fine stripes required many months. The time course of recovery thus shows an early rapid phase followed by a later, slower phase. The early phase corresponded well with the dispersal of oedema which was a prominent feature of the early lesion. The mechanism of the later,

slower recovery is not yet established, but since there are no alternative anterior pathways for vision, it must involve some kind of adaptive synaptic changes.

To the extent that nerve fibre degeneration contributes to visual loss in patients with tumours of the visual pathways, I think that the processes operating in these experiments contribute to visual recovery after relief of compression.

Rapidly Reversible Conduction Block

I now wish to turn to a consideration of the short-term changes in properties

of compressed nerve fibres, in particular the rapidly reversible form of conduction block ("physiological" block) with which we are familiar when an arm or leg "goes to sleep" and which is rapidly reversed when the pressure is relieved. This form of conduction block is due to ischaemia (Lewis et al. 1931). A similar phenomenon is easy to demonstrate experimentally in central nerve fibres and the following remarkable case provided evidence from visual evoked potential recordings for its existence in man.

Case 8: A 57-year old woman presented with the history that for a

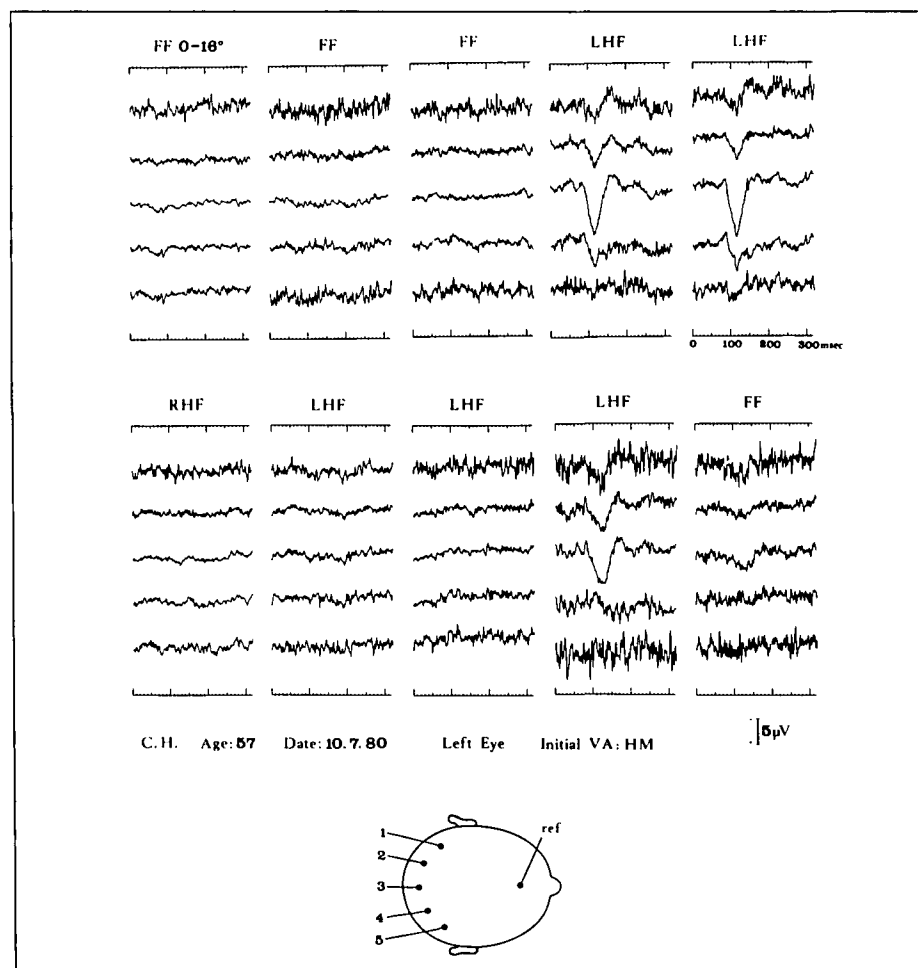


Figure 6 — Case 8. Visual evoked potentials from a patient with a giant aneurysm of the internal carotid artery. The stimulus was a chequerboard pattern reversed at 2Hz. Recordings were made from a mid-line occipital electrode and two laterally-placed occipital electrodes on each side. 200 responses were averaged in each run. The records were taken consecutively in one recording session. FF = 32° field stimulus (16° in each half field). LHF = left half field stimulus. RHF = right half field stimulus. (By courtesy of Dr. A.M. Halliday. From *Evoked potentials in clinical testing*, edited by A.M. Halliday. Edinburgh: Churchill Livingstone, 1982.)

year she had had to turn her head to see to the left. The vision had gradually deteriorated. She saw occasional brief flashes of light without obvious precipitating factors. A CT scan revealed an enhancing mass which was shown by arteriography to be a giant aneurysm arising from the left internal carotid artery just below its bifurcation. The visual evoked potential records are shown in fig. 6. The acuities at the start of the session were VAR 6/5, VAL - hand movements. Responses from the right eye were normal throughout. From the left eye there was no response during the first three averaging runs. In the next run, in which the left temporal field (LHF) was stimulated alone, the patient reported that she could see the checks in the peripheral part of that field. Previously, when this eye was being tested with the full-field stimulus she

was only aware of unpatterned light somewhere in the temporal field. The response of the left eye to the temporal stimulus, which was repeated, showed a well-defined major positive component, largest at the mid-line. A further run showed similar features. The right eye was then tested with half-field stimulation. Some minutes later, the nasal field of the left eye was stimulated, and the patient reported that she could see nothing. No response could be seen in the averaged record (not illustrated). Two further runs were recorded stimulating the temporal field of the left eye, with the same result, the patient saying throughout that she was unable to see the checks now and was only aware of a light. In the fourth run with the temporal stimulus however, the checks suddenly became visible again and the evoked response reappeared in the

record. A final run, stimulating the left eye with the full-field stimulus, produced only a small response, the patient reporting that she could see the checks but less clearly than before.

It is now time to see how far we can explain the clinical features of visual failure and its recovery in terms of alterations in the properties of compressed nerve fibres. Let us consider first the changes in vision experienced by a patient successfully treated for pituitary tumour.

Case 9: A 61-year old man had a craniotomy for a pituitary tumour which had produced visual symptoms for 2 years. His sight improved but the following year it deteriorated again over 2 months. On examination VAR 6/24, VAL 6/12. There was a bitemporal hemianopia (fig. 7). After decompression there was rapid improvement in the first two days, the acuities being VAR 6/9 and VAL 6/12 and the fields already having opened out. There was further improvement at five days and at fifteen days. Over the ensuing four months there was slower recovery, the acuity by that time reaching VAR 6/6 and VAL 6/9.

I suggest that the initial visual impairment was due to a combination of loss of nerve fibres by Wallerian degeneration, conduction block as a result of demyelination, and "physiological" block in fibres that would be able to conduct if they were not compressed. Such fibres would include histologically normal fibres and remyelinated fibres, which from Smith's work we would expect to be able to conduct when the "physiological" block was relieved. I suggest that the early rapid phase of recovery was due to restoration of conduction in the latter two groups of fibres. The slower recovery phase can be accounted for by contributions both from progressive remyelination of demyelinated fibres (as in the later stages of Smith's experiments) and the mechanisms operating in Jacobson's experiments.

Turning now to spontaneously remitting visual loss, the final determining factors will be the properties and relative numbers of normal, demyelinated and remyelinated nerve fibres. The changes in vision are likely to reflect changing severity of compression of the neural structures and their

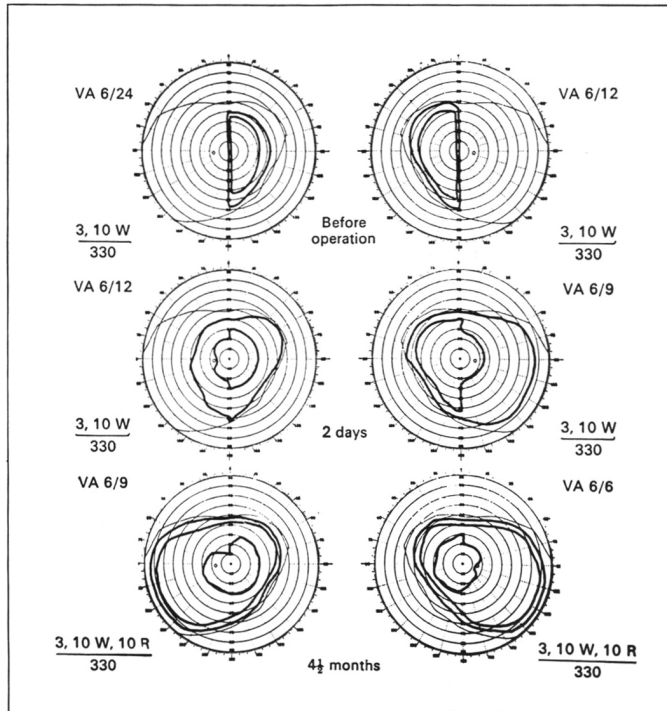


Figure 7 — Case 9. Previous craniotomy 1969 for pituitary adenoma which had caused visual symptoms for two years. Visual symptoms recurred two months before the second admission. Fields: bitemporal hemianopia. Slight pallor of the discs. Pupils: ill-sustained reaction R and L. Operation July 29, 1970. Recurrent chromophobe adenoma. Some field improvement in two days; further improvement by five days, and at fifteen days. Some further improvement in four and a half months. (By courtesy of Dr. C.J. Earl. From Kayan and Earl, 1975.)

blood supply. Direct evidence for such a mechanism comes from a patient reported by Gutin et al. (1980) who had a cystic craniopharyngioma which was drained externally. When the pressure rose the visual evoked potential was abolished, only to return again when the cyst was drained. The explanation for spontaneously reversible visual loss with meningioma probably lies in the development of transient swelling produced by the oedema accompanying the small infarcts which occur in these tumours.

Spontaneous Visual Phenomena

Finally, I should like to consider the origin of the spontaneous visual phenomena. I have argued that compression of the visual pathways results in demyelination of some fibres. The physiological question then becomes "do demyelinated central nerve fibres have properties which could account for the perception of flashes of light?"

Smith and I have examined the possibility in the spinal cord model one to two weeks after injection of lysophosphatidylcholine when demyelination is widespread (Smith and McDonald, 1982). Fig. 8 shows the experimental arrangements. Recordings were made from dorsal root filaments caudal to the injection site. Small (less than 1mm) deformations at the lesion commonly induced bursts of activity, or a transient increase in discharge frequency of fibres which were spontaneously active. Such effects were not seen when the same fibres were similarly manipulated in the histologically normal cord. By recording simultaneously rostral and caudal to the lesion it was possible to show that the mechanically evoked and spontaneous impulses were passing centrally as well as peripherally. If, as I suggest, some compressed optic nerve fibres are demyelinated it is reasonable to suppose that they will be abnormally excitable. The central transmission of

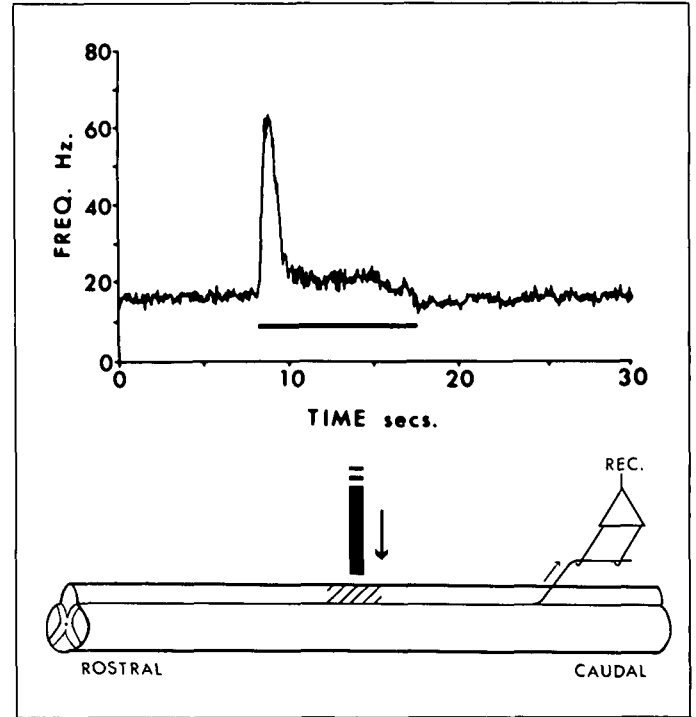


Figure 8 — Effect of deformation on the spontaneous discharge of a fibre passing through a demyelinating lesion induced by the injection of lysophosphatidylcholine 8 days previously. The diagram shows how single unit activity was recorded from a cut dorsal root filament. The lesion is indicated by cross-hatching. The graph shows that the resting frequency of 18Hz was increased during deformation (bar) of the lesion by 0.75 mm with a glass rod. (From Smith and McDonald, 1982.)

bursts of spontaneously arising impulses would provide a satisfactory explanation for the flashes of light that patients describe. The explanation for their comparative rarity is less certain. I suspect that it lies in part in the presence of widespread remyelination and in part in the existence of pressure block in many of the damaged fibres.

But we are now returning to speculation which Hope explicitly avoided and I shall too. We have in the experiments I have described a sufficient explanation at one level of analysis for the visual symptoms experienced by many patients with tumours of the anterior visual pathways. But our observations raise questions at other levels. What is the mechanism of demyelination and remyelination? There is good evidence that ischaemia accounts for the episodes of transient visual loss seen with optic nerve sheath meningioma and it is probable that it accounts for the rapid fluctuations in vision seen in

patients such as Case 8. But its role in the pathogenesis of the chronic compressive lesion is much less certain. In the peripheral nervous system ischaemia can produce demyelination (Hess et al., 1979, Fowler and Gilliatt, 1981) but there is good evidence that compression can do so independently of it by complex mechanical effects on the myelin-axon junction (Ochoa et al., 1972; Ochoa and Marotte, 1973; Gilliatt, 1981). The anatomical arrangements in the central nervous system are different and whether similar mechanisms operate there remains to be determined. Finally, we know very little about the factors which regulate the recovery process. The next step is to identify them and to unravel the way in which they work. We must then learn to manipulate them to the benefit of our patients, the primary concern of Jack Silversides and of us all.

REFERENCES

- BLAKEMORE, W.F., EAMES, R.A., SMITH, K.J. & McDONALD, W.I. (1977) Remyelination in the spinal cord of the cat following intraspinal injections of lysolecithin. *J. Neurol Sci.* 33: 31-43.
- BLAKEMORE, W.F. & MURRAY, J.A. (1981) Quantitative examination of internodal length of remyelinated nerve fibres in the central nervous system. *J. Neurol Sci.* 49: 273-284.
- CLIFFORD-JONES, R.E., LANDON, D.N. & McDONALD, W.I. (1980) Remyelination during optic nerve compression. *J. Neurol Sci.* 46: 239-243. (Also published in *Trans Ophthalmol Soc UK* 100: 274-275.)
- DAVIS, F.A., BERGEN, D., SCHAUF, C., McDONALD, I. & DEUTSCH, W. (1976) Movement phosphenes in optic neuritis: a new clinical sign. *Neurology*. Minneap. 26: 1100-1104.
- EAMES, R.A., JACOBSON, S.G. & McDONALD, W.I. (1977) Pathological changes in the optic chiasm of the cat following local injection of diphtheria toxin. *J. Neurol Sci.* 32: 381-393.
- FOWLER, C.F. & GILLIATT, R.W. (1981) Conduction velocity and conduction block after experimental ischaemic nerve injury. *J. Neurol Sci.* 52: 221-238.
- GILLIATT, R.W. (1981) Physical injury to peripheral nerves: physiologic and electrodiagnostic aspects. *Mayo Clin. Proc.* 56: 361-370.
- GLEDHILL, R.F., HARRISON, B.M. & McDONALD, W.I. (1973) Demyelination and remyelination after acute spinal cord compression. *Exp. Neurol* 38: 472-487.
- GUTIN, P.H., KLEMME, W.M., LAGGER, R.L., MACKAY, A.R., PITTS, L.H. & HOSOBUCHI, Y. (1980) Management of the unresectable cystic craniopharyngioma by aspiration through an Ommaya reservoir drainage system. *J. Neurosurg.* 52: 36-40.
- HALLIDAY, A.M., HALLIDAY, E., KRIS, A., McDONALD, W.I. & MUSHIN, J. (1976) The pattern-evoked potential in compression of the anterior visual pathways. *Brain*, 99: 357-374.
- HARRISON, B.M., GLEDHILL, R.F. & McDONALD, W.I. (1975) Remyelination after transient compression of the spinal cord. *Proc. Aust. Assoc. Neurol* 12: 117-122.
- HARRISON, B.M., McDONALD, W.I. & OCHOA, J. (1972) Remyelination in the central diphtheria toxin lesion. *J. Neurol. Sci.* 17: 293-302.
- HESS, K., EAMES, R.A., DARVENIZA, P. & GILLIATT, R.W. (1979) Acute ischaemic neuropathy in the rabbit. *J. Neurol Sci.* 44: 19-43.
- HOLMES, G. (1906) On the relation between loss of function and structural changes in focal lesions of the central nervous system, with special reference to secondary degeneration. *Brain*, 29: 514-523.
- HOPE, T. (1744) An account of a remarkable cure, performed on the eye of a young woman in Scotland. *Phil. Trans. Roy. Soc. Lond.* 43: 194-200.
- JACOBSON, S.G., EAMES, R.A. & McDONALD, W.I. (1979) Optic nerve fibre lesions in adult cats: pattern of recovery of spatial vision. *Exp. Brain Res.* 36: 491-508.
- JEFFERSON, G. (1945) The Doyne Lecture: On compression and invasion of the optic nerves and chiasma by neighbouring gliomas. *Trans Ophthalmol Soc. UK* 65: 262-304.
- KAYAN, A. & EARL, C.J. (1975) Compressive lesions of the optic nerves and chiasm. Pattern of recovery of vision following surgical treatment. *Brain* 98: 13-28.
- KIRKHAM, T.H. (1972) The ocular symptomatology of pituitary tumours. *Proc. R. Soc. Med.* 65: 517-518.
- LEWIS, T., PICKERING, G.W. & ROTHCHILD, P. (1931) Centripetal paralysis arising out of arrested bloodflow to limb, including notes on form of tingling. *Heart* 16: 1-32.
- OCHOA, J., FOWLER, T.J. & GILLIATT, R.W. (1972) Anatomical changes in peripheral nerves compressed by a pneumatic tourniquet. *J. Anat* 113: 433-455.
- OCHOA, J. & MAROTTE, L. (1973) The nature of the nerve lesion caused by chronic entrapment in the guinea-pig. *J. Neurol Sci.* 19: 491-495.
- SMITH, K.J., BLAKEMORE, W.F. & McDONALD, W.I. (1981) The restoration of conduction by central remyelination. *Brain* 104: 383-404.
- SMITH, K.J. & McDONALD, W.I. (1982) Spontaneous and evoked electrical discharges from a central demyelinating lesion. *J. Neurol Sci.* 55: 39-47.
- SYMON, L. & JAKUBOWSKI, J. (1979) Transcranial management of pituitary tumours with suprasellar extension. *J. Neurol Neurosurg Psychiatry* 42: 123-133.
- WEINBERGER, I.M. & GRANT, F.C. (1940) Visual hallucinations and their neuro-optical correlates. *Arch. Ophthalmol.* 23: 166-199.
- WRIGHT, J.E., McDONALD, W.I. & CALL, M.B. (1980) The management of optic nerve gliomas. *Brit. J. Ophthalmol.* 64: 545-552.
- YOUNG, G. (1924) Retrobulbar neuritis of the sphenoidal sinus origin. *J. Laryngol Otol* 39: 381-383.