

Letter to the Editor: New Observation

Four Octapeptide Repeat Insertion (4-OPRI) in *PRNP* Causing Huntington Disease Phenocopy

Jacky Ganguly , Mellany Tuesta Bernaola and Mandar Jog 

Movement Disorder Centre, London Health Sciences Centre, The University of Western Ontario, London, ON, Canada

Keywords: HD phenocopy; PRNP; 4-OPRI

A 67-year-old retired gentleman, who finished his 10th grade of education and a professional cyclist, was seen with a past history of a major road traffic accident at his 36 years of age. He was hit by a truck while riding a bicycle that resulted in multiple fractures, concussion and was almost bedridden for a prolonged period of 5 years. Gradually, he recovered his mobility significantly. However, for the past 3 years, he started having unsteadiness and fidgetiness with tendency to fall, for which he started using walking aids. For the past 2 years, he developed progressive cognitive decline in the form of inattention, misplacing objects and getting lost. He was unable to drive, cook or do laundry and became incapable of managing his finances due to his cognitive issues. He also noticed progressive slowness in gross and fine motor activities for the same duration, associated with fragmented sleep, vivid dreams and choking with solids. He also developed depression with severe irritability in last 1 year. Both of his parents were from British-Canadian ancestry. There was a family history of dementia and fidgetiness in his father and dementia in paternal aunt (Fig. 1). In both of them, the symptoms started in late sixth decade and they died in their mid sixties, without any proper diagnosis. On clinical examination, generalised chorea and distal myoclonus in upper limbs were noted. Symmetric appendicular rigidity and bradykinesia of moderate severity were observed in all four limbs along with freezing of gait and frontal release signs. Montreal Cognitive Assessment (MoCA) score was 14/30, with abnormalities in frontal executive, episodic memory and visuospatial domains. Levodopa along with rivastigmine and citalopram was tried without much sustained therapeutic response.

MRI brain showed generalised cortical and cerebellar atrophy along with caudate atrophy (Fig. 2), without any reminiscence of past trauma. Besides this, our patient had a history of severe TBI more than 25 years prior and recovered significantly before new onset deterioration for the past 3 years, unlikely as a sequelae of TBI. Huntington disease (HD), HD phenocopies including *C9ORF72* related disorder, HD like 1 (*PRNP* related), HD like 4 (SCA17) and inherited prion diseases including familial Creutzfeldt–Jakob disease (fCJD), Gertsman–Sträussler–Scheinker disease (GSS) were considered because of a combination of chorea, parkinsonism, myoclonus and dementia in our patient.

Genetic testing for HD and SCA17 was negative. Finally, repeat expansion analysis through amyotrophic lateral sclerosis panel testing was done with special reference to *C9ORF72* and *PRNP* genes. The test revealed normal number of repeats in *C9ORF72*, but a heterozygous repeat expansion in the *PRNP* gene at cytoband 20p13, with four octapeptide in one allele (normal range) and eight octapeptide (four extra octapeptide repeat insertion) in the other. Homozygosity for methionine noted at codon 129 (MM). Insertions leading to expansion of the octapeptide domain of additional four repeats with MM polymorphism at codon 129 has been previously reported with prion disease. The detected expansion was classified as class 1 (pathogenic) according to ACMG criteria. In this panel testing, *C9ORF72* and *PRNP* genes were analysed by polymerase chain reaction (PCR), and repeat primed assay (RPA) was performed to screen for a large expansion in the gene. GeneMapper™ software was used for the detection of expansion. Thus, the final diagnosis was inherited prion disease (4-OPRI in *PRNP*) presenting as HD phenocopy.

Normal prion protein gene (*PRNP*) comprises a nona-peptide followed by a tandem repeat of four copies of an octapeptide (R1-R2-R2-R3-R4) that lies between codons 51 and 91, in its flexible N-terminal domain. R1 encodes a nona-peptide, while R2 to R4 each encode the following amino acids: Pro-(His/Gln)-Gly-Gly-Gly-(-/Trp)-Gly-Gln.¹ Up to twelve additional octapeptide repeat insertion (OPRI) can be seen in the expanded forms. Addition of OPRI in the *PRNP* gene can phenotypically manifest with movement disorders (predominantly ataxia), progressive multifocal dementia and behavioural changes.² Clinical spectrum of OPRI associated prion disease is wide and still evolving. The dominant clinical feature (psychiatric, cognitive, cerebellar and extrapyramidal), age of onset and severity vary within and between OPRI families due to *PRNP* codon 129 methionine/valine polymorphism, variation of the modifier loci and heterogeneity of the misfolded protein.

Eight octapeptide repeat insertion (8-OPRI) has been linked with HDL1 phenotype, characterised by rapidly progressive cognitive decline, psychiatric manifestations and movement disorders. It has been described in French, Dutch, Swedish and Danish families.^{2,3} Psychiatric features include apathy, aggression,

Corresponding author: M. Jog; Email: mandar.jog@lhsc.on.ca

Cite this article: Ganguly J, Tuesta Bernaola M, and Jog M. Four Octapeptide Repeat Insertion (4-OPRI) in *PRNP* Causing Huntington Disease Phenocopy. *The Canadian Journal of Neurological Sciences*, <https://doi.org/10.1017/cjn.2023.279>

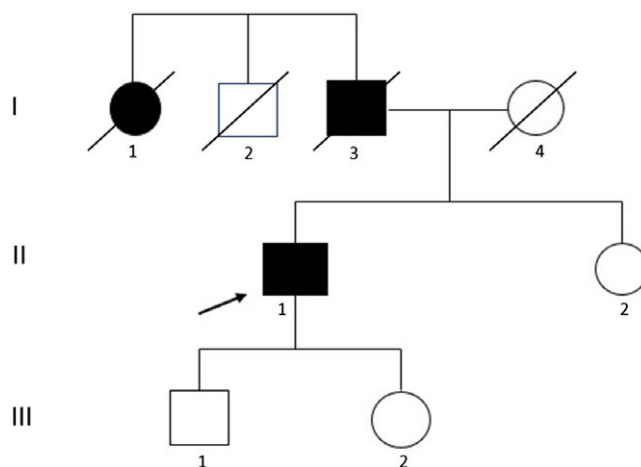


Figure 1: Pedigree of the family. Deceased affected male with dementia and fidgetiness, deceased affected female with dementia, surviving unaffected male, surviving unaffected female, index patient, deceased unaffected male, deceased unaffected female.

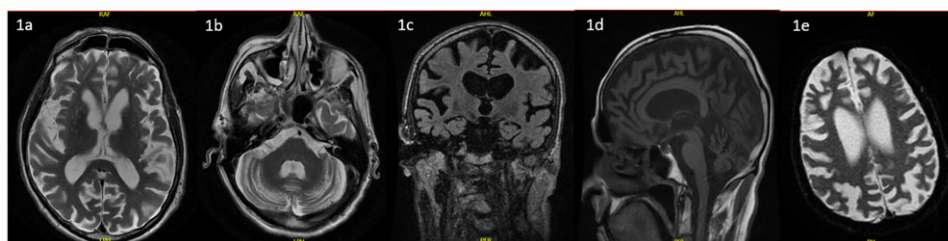


Figure 2: T2 axial (1a, 1b, 1e), T2 coronal (1c) and T2 sagittal (1d) MRI brain images of the patient, showing cortical, cerebellar and caudate atrophy.

mania, perseveration and emotional lability. Progressive dementia is a universal feature that starts with impairment in attention and episodic memory and subsequently affects all the cognitive domains including language, praxis and calculation. Cerebellar ataxia is the most common movement disorder, followed by parkinsonism, dystonia, myoclonus and chorea.^{2,3}

4-OPRI cases reported so far, mostly presented with rapidly developing cortical dementia, myoclonus and ataxia.⁴ Chorea was present in 3 out of 10 patients with 4-OPRI reported by Kaski *et al.*⁴, but it was not the dominant feature in any of these patients unlike in our case. Pure cognitive presentation with episodic memory involvement and executive dysfunction was reported in one of them. Recently, Martin *et al.* reported slowly progressive cerebellar ataxia, parkinsonism in a patient with 4-OPRI and misdiagnosed as multiple system atrophy-cerebellar type (MSA-C).⁵ Associated cognitive impairment, myoclonus and absence of autonomic dysfunction were the clinical red flags for the patient. Family history of dementia was uncommon in the previous case series but was present in the latter, similar to our case.⁴ We have also found homozygosity for methionine (MM) at codon 129, identical to all the eleven patients with 4-OPRI described previously. While majority of patients with repeat insertions of four or less present with phenotype similar to sporadic CJD⁶, presence of larger repeats like 5-, 6-, 7- or 12-OPRIs are often associated with a GSS phenotype characterised by familial frontotemporal dementia with cerebellar ataxia.^{1,7-10} In addition, patients with 6-OPRI can also have parkinsonism and chorea.⁸

To conclude, in patients with HD phenotype with or without family history of dementia, inherited prion disorder with OPRI should never be missed, when genetics for HD, *C9ORF72* and

SCA17 are negative. While 8-OPRI is commonly reported with HDL-1 phenotype, HD phenocopy can be associated with 4-OPRI as well.

Acknowledgement. We acknowledge Dr Antonio Romito, PhD, Clinical Geneticist, CENTOGENE GmbH for the genetic analysis and interpretation.

Funding. Dr Jog receives speaker's fees and research funding from Allergan, AbbVie, Merz Pharmaceuticals, Boston Scientific, Valeo Pharma, Sunovion and Paladin Labs. Dr Jog also receives grants from Parkinson society Canada, CIHR, NSERC, MITACS, Research Council of Norway, Parkinson Society of Southwestern Ontario, Dystonia Medical Research Foundation and Academic Medical Organization of Southwestern Ontario.

Dr Tuesta Bernaola receives fellowship funding from the Parkinson Society of Southwestern Ontario (PSSO).

Dr Ganguly has nothing to disclose.

Competing interests. None.

Ethical statement. The authors confirm that the approval of an institutional review board/patient consent was not required for this work. We also confirm that the patient has given written informed consent for the publication of his imaging. We confirm that we have read the Journal's position on issues involved in ethical publication and affirm that this work is consistent with those guidelines.

Statement of authorship. 1. Research project: A. Conception, B. Organisation, C. Execution.

2. Manuscript Preparation: A. Writing of the first draft, B. Review and Critique.

JG: 1B, 1C, 2A.

MTB: 1B, 1C, 2A.

MJ: 1A, 2B.

References

1. Schmitz M, Dittmar K, Llorens F, et al. Hereditary human prion diseases: an update. *Mol Neurobiol.* 2017;54:4138–49. DOI: [10.1007/s12035-016-9918-y](https://doi.org/10.1007/s12035-016-9918-y).
2. Paucar M, Xiang F, Moore R, Walker RH, Winnberg E, Svenningsson P. Genotype-phenotype analysis in inherited prion disease with 8 octapeptide repeat insertional mutation. *Prion.* 2013;7:501–10. DOI: [10.4161/pri.27260](https://doi.org/10.4161/pri.27260).
3. Areškevičiūtė A, Høgh P, Bartoletti-Stella A, et al. A novel eight octapeptide repeat insertion in PRNP causing prion disease in a danish family. *J Neuropathol Exp Neurol.* 2019;78:595–604. DOI: [10.1093/jnen/nlz037](https://doi.org/10.1093/jnen/nlz037).
4. Kaski DN, Pennington C, Beck J, et al. Inherited prion disease with 4-octapeptide repeat insertion: disease requires the interaction of multiple genetic risk factors. *Brain.* 2011;134:1829–1838. DOI: [10.1093/brain/awr079](https://doi.org/10.1093/brain/awr079).
5. Martin NB, Koga S, Appleby BS, Sekiya H, Dickson DW. Creutzfeldt-jakob disease misdiagnosed as multiple system atrophy. *Mov Disord Clin Pract.* 2023;10:496–500. DOI: [10.1002/mdc3.13654](https://doi.org/10.1002/mdc3.13654).
6. Brennecke N, Cali I, Mok T, et al. Characterization of prion disease associated with a two-octapeptide repeat insertion. *Viruses.* 2021;13:1794. DOI: [10.3390/v13091794](https://doi.org/10.3390/v13091794).
7. Hamada S, Takahashi-Iwata I, Satoh K, et al. Genetic creutzfeldt–jakob disease with 5-octapeptide repeats presented as frontotemporal dementia. *Hum Genome Var.* 2023;10:10. DOI: [10.1038/s41439-023-00237-w](https://doi.org/10.1038/s41439-023-00237-w).
8. Mead S, Poulter M, Beck J, et al. Inherited prion disease with six octapeptide repeat insertional mutation - molecular analysis of phenotypic heterogeneity. *Brain.* 2006;129:2297–2317. DOI: [10.1093/brain/awl226](https://doi.org/10.1093/brain/awl226).
9. Jansen C, Voet W, Head MW, et al. A novel seven-octapeptide repeat insertion in the prion protein gene (PRNP) in a dutch pedigree with Gerstmann–sträussler–scheinker disease phenotype: comparison with similar cases from the literature. *Acta Neuropathol.* 2011;121:59–68. DOI: [10.1007/s00401-010-0656-3](https://doi.org/10.1007/s00401-010-0656-3).
10. Townley RA, Polsinelli AJ, Fields JA, et al. Longitudinal clinical, neuropsychological, and neuroimaging characterization of a kindred with a 12-octapeptide repeat insertion in *PRNP*: the next generation. *Neurocase.* 2020;26:211–9. DOI: [10.1080/13554794.2020.1787458](https://doi.org/10.1080/13554794.2020.1787458).