

## TO THE EDITOR

**Intra-Arterial Verapamil-Induced Seizures: Drug Toxicity or Rapid Reperfusion?**

Verapamil, a calcium channel blocker and vasodilator, is being increasingly used in the endovascular management of medically refractory symptomatic post-hemorrhagic cerebral vasospasm<sup>1</sup>. Intra-arterial (IA) infusion of verapamil has been shown to reduce angiographic vessel narrowing and lead to clinical improvement in treated patients<sup>1</sup>. The side effects of IA verapamil are usually transient and include lowering of heart rate and blood pressure and increased intracranial pressure<sup>1</sup>. Seizures have only been exceptionally reported in this setting and have been postulated to result from a direct proconvulsant effect of the drug on metabolically challenged neurons<sup>2</sup>. We present a case report that calls this concept into question, suggesting that IA verapamil-induced seizures may not necessarily represent an adverse event, but instead may result from rapid drug-induced reperfusion of an ischemic brain.

## CASE REPORT

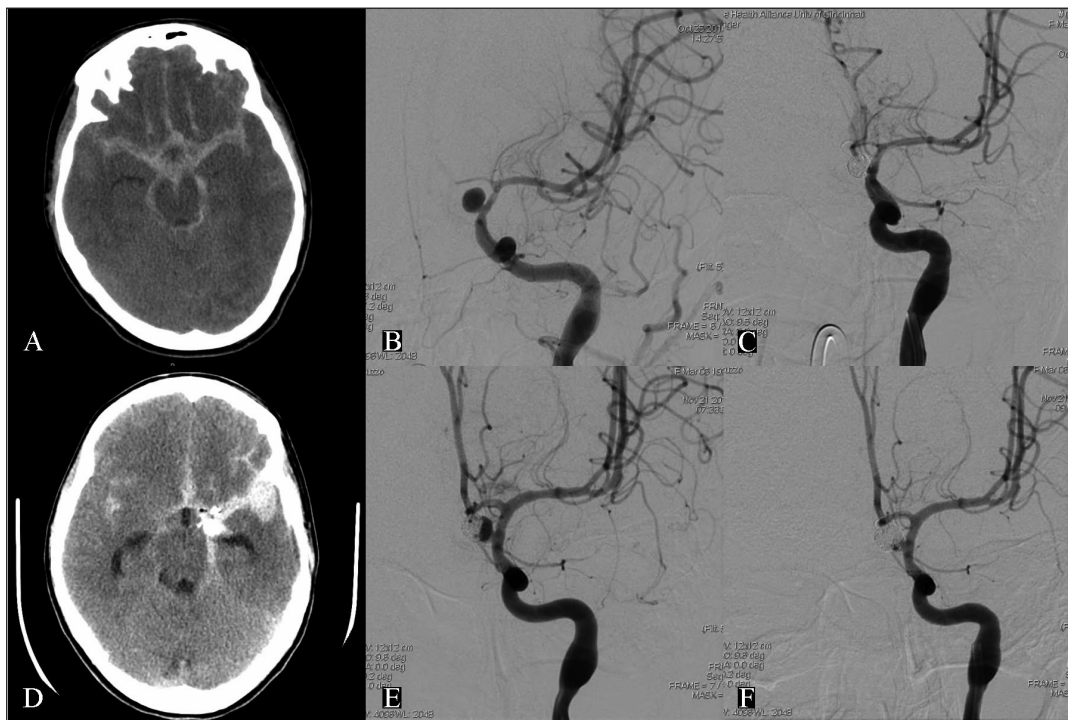
**Initial Presentation and Management**

A 27-year-old previously healthy woman sustained a closed head injury with multiple facial and body fractures and bilateral pulmonary contusions, after being struck by a car while cycling. She was initially unresponsive and underwent endotracheal

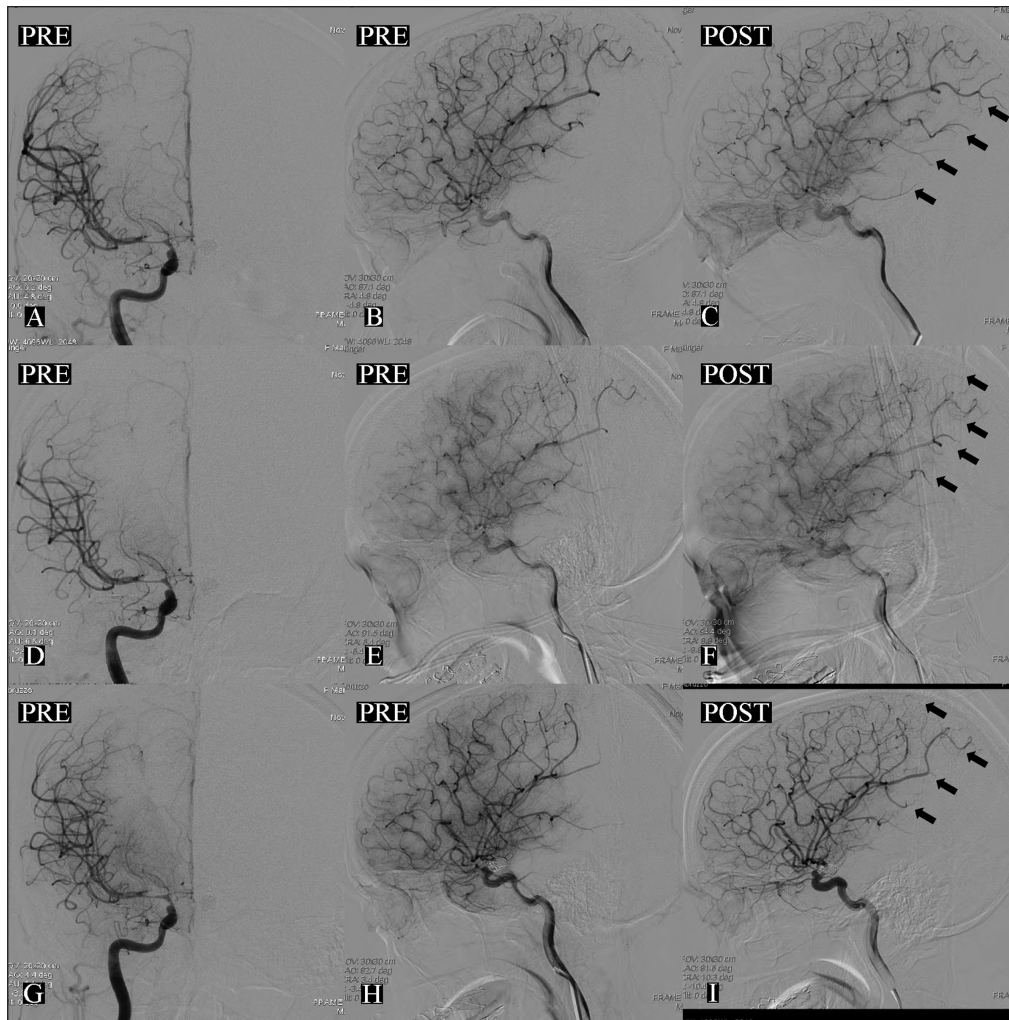
intubation. Following resuscitation, her level of consciousness improved and her neurological examination showed no focal deficits. Head computed tomogram (CT) revealed Fisher grade 3 subarachnoid hemorrhage (SAH) (Figure 1A). The patient was placed on levetiracetam 1,000 mg twice daily for seizure prophylaxis. Findings on CT angiography were suspicious for a 1 to 2-mm aneurysm of the supraclinoid left internal carotid artery (ICA). A few days later, cerebral angiography revealed a 6-mm left posterior communicating artery (PCoM) aneurysm, which was believed to be the source of hemorrhage (Figure 1B). In addition, a 5-mm right ophthalmic artery aneurysm was identified and non-flow-limiting dissection of the distal left cervical ICA was strongly suspected. Given the latter finding, the mechanism of injury, and the rapid growth of the left PCoM aneurysm, this aneurysm was felt to be dissecting in nature. Stent-assisted coiling was thus performed (Figure 1C). The patient had a favorable post-operative course with no new neurological deficits. She was transferred, a few days later, to a rehabilitation facility on dual oral antiplatelet therapy (aspirin 325 mg and clopidogrel 75 mg daily).

**Recurrent Hemorrhage and Symptomatic Vasospasm**

Three weeks later, the patient experienced sudden-onset severe headache with loss of consciousness. Head CT revealed new Fisher grade 3 SAH predominating in the left sylvian fissure (Figure 1D). Cerebral angiography demonstrated recurrence of the left PCoM aneurysm (Figure 1E). Repeat coil embolization



**Figure 1:** A) Head CT reveals Fisher grade 3 subarachnoid hemorrhage. B) Cerebral angiography demonstrates a 6-mm left posterior communicating artery aneurysm. C) Post-treatment cerebral angiography shows complete aneurysm obliteration after stent-assisted coiling. D) Head CT, 3 weeks later, reveals recurrent Fisher grade 3 subarachnoid hemorrhage predominating in the left sylvian fissure. E) Cerebral angiography demonstrates recurrence of the coiled left posterior communicating artery aneurysm. F) Post-treatment cerebral angiography shows subtotal aneurysm obliteration after repeat coiling.



**Figure 2:** A) and B) Cerebral angiography 6 days after recurrent subarachnoid hemorrhage demonstrates severe diffuse vasospasm in the right internal carotid, middle cerebral, and anterior cerebral arteries. C) Repeat angiography immediately following infusion of 20 mg of verapamil in the right internal carotid artery, shows significant improvement of vasospasm and evidence of cortical reperfusion (arrows). B) and C) are identical angiographic views, representing the late arterial phase seen from a lateral projection. Similar findings were observed on post-hemorrhage days 7 (D-F) and 9 (G-I).

was thus performed, resulting in subtotal aneurysm obliteration (Figure 1F). Post-operatively, the patient regained a normal level of consciousness and a normal neurological exam. However, five days later (SAH Day 6), she became obtunded with a dense left hemiparesis. Head CT revealed no new findings. Cerebral angiography was urgently performed and showed severe proximal and distal vasospasm in the right internal carotid, middle cerebral, and anterior cerebral arteries, with markedly delayed contrast transit time in the right hemisphere (Figures 2A,B). Given the diffuse nature of vasospasm, decision was made to treat the patient with IA verapamil. A slow continuous infusion of 20 mg of verapamil (2.5 mg/mL solution) was thus administered into the right ICA.

#### First Verapamil-Induced Seizure

Immediately following this infusion, the patient started complaining of severe headache and became markedly agitated.

Within a few seconds, she exhibited left hemibody clonic convulsions with secondary generalization into a self-limited tonic-clonic seizure, lasting approximately two minutes. Immediate repeat angiography of the right ICA documented substantial improvement in the degree of both proximal and distal vasospasm, with markedly enhanced right hemispheric perfusion (Figure 2C). There was no evidence of contrast extravasation or thromboembolic complications. Angiography of the left ICA revealed moderate proximal and distal vasospasm, which was treated with a slow IA infusion of 10 mg of verapamil. The latter was uneventful and did not cause additional seizures. Post-operative head CT showed no evidence of hemorrhagic or ischemic complications. A complete blood work-up was also negative, including normal sodium, calcium, and glucose levels. Following a transient postictal state, the patient quickly regained a normal level of consciousness and a normal left hemibody motor strength.

### Second Verapamil-Induced Seizure

The next morning (SAH Day 7), the same symptoms (lethargy and dense left hemiparesis) recurred and no new findings were observed on head CT. Cerebral angiography demonstrated recurrent severe vasospasm in the proximal and distal territories of the right ICA (Figures 2D,E). Twenty mg of verapamil were slowly infused into this vessel, which resulted once again in severe headache, marked agitation, and self-limited secondarily generalized tonic-clonic seizure, followed by substantial neurological improvement. Repeat angiography documented immediate improvement of vasospasm and absence of hemorrhagic or thromboembolic complications (Figure 2F). Subsequently, 10 mg of verapamil were infused uneventfully into the left ICA where moderate proximal and distal vasospasm was observed. Post-operative head CT again revealed no new findings.

### Third Verapamil-Induced Seizure

Forty-eight hours later (SAH Day 9), the patient experienced once more the same neurological symptoms. Angiography of the left ICA was performed first and showed moderate-to-severe proximal and distal vasospasm. Twenty mg of verapamil were slowly infused into this vessel without any complications. Subsequently, right ICA angiography demonstrated recurrent severe proximal and distal vasospasm (Figures 2G,H). Twenty mg of verapamil were slowly infused into this vessel, which once more was followed by the same sequence of events: headache, agitation, secondarily generalized tonic-clonic seizure, and marked neurological improvement. Repeat angiography (Figure 2I) and post-operative head CT were again obtained, documenting significant cerebral reperfusion and absence of hemorrhagic or thromboembolic complications.

### Final Outcome

Subsequently, the patient had a favorable hospital course with resolution of vasospasm and no new seizures. She remained neurologically intact with no evidence of brain infarction on head CT, and was eventually discharged home. A few weeks later, after dual antiplatelet therapy was discontinued, she underwent clipping of her incompletely coiled aneurysm. At her three month follow-up office visit, she had regained full independence in her usual daily activities and her neurological examination was completely normal.

### DISCUSSION

The occurrence of seizures after IA verapamil infusion in patients with post-hemorrhagic vasospasm has only been reported once in the literature and has been postulated to result from a direct toxic effect of the drug on a metabolically challenged, ischemic brain<sup>2</sup>. Although SAH patients are naturally prone to develop seizures, a cause-and-effect relationship between IA verapamil and seizures in this patient is strongly suggested by the timing of seizure occurrence in relation to drug administration and by the fact that, each time the patient was rechallenged with verapamil, seizures recurred in an almost stereotypical fashion.

However, the claim that IA verapamil-induced seizures are the result of a direct proconvulsant effect of the drug on the brain, remains speculative. In fact, verapamil has been shown to

have anticonvulsant properties in both animal and human research<sup>3</sup>. Moreover, this medication is commonly used by cardiologists as an antiarrhythmic and antihypertensive agent, and administered systemically at much higher doses than those given for vasospasm (e.g. 240-480 mg daily). Even with such high doses of verapamil, seizures have not been commonly observed. Furthermore, the fact that, in this patient, infusion of a similar dose of verapamil into the left ICA at the time of her third episode was not complicated by seizures, argues against a systemic proconvulsant drug effect.

We propose that seizures induced by IA verapamil are actually the result of rapid reperfusion of an ischemic brain. This is supported by the fact that seizures were always followed by angiographic evidence of immediate reperfusion and by neurological improvement. This phenomenon has similarly been reported following thrombolysis for acute ischemic stroke, where successful recanalization and clinical recovery can be heralded by seizures<sup>4,5</sup>. The mechanism of reperfusion-induced seizures may involve the release of vasoactive compounds during ischemia, which could cause inflammation and cellular damage following reperfusion, thus triggering a focal seizure [4]. Alternatively, reactive oxygen species and free radicals generated during the reperfusion period may lead to reperfusion injury and epileptogenesis<sup>5</sup>.

In conclusion, in patients with post-hemorrhagic cerebral vasospasm, IA verapamil-induced seizures do not necessarily represent an adverse event. In the absence of angiographically demonstrable complications, such as intraprocedural aneurysm rupture or thromboembolism, seizures may be caused by rapid drug-induced reperfusion of an ischemic brain and may herald neurological improvement. Although this phenomenon seems to occur with relatively large doses of verapamil (> 10 mg), the dose effect may be more directly related to the rate at which cerebral perfusion is restored in the ischemic brain.

*Ralph Rahme, Todd A. Abruzzo,  
Mario Zuccarello, Andrew J. Ringer  
University of Cincinnati  
(UC) Neuroscience Institute,  
UC College of Medicine, Mayfield Clinic  
Cincinnati, Ohio, USA  
Email: editor@mayfieldclinic.com*

### REFERENCES

1. Keuskamp J, Murali R, Chao KH. High-dose intraarterial verapamil in the treatment of cerebral vasospasm after aneurysmal subarachnoid hemorrhage. *J Neurosurg.* 2008;108(3):458-63.
2. Westhout FD, Nwagwu CI. Intra-arterial verapamil-induced seizures: case report and review of the literature. *Surg Neurol.* 2007;67(5):483-6.
3. Iannetti P, Spalice A, Parisi P. Calcium-channel blocker verapamil administration in prolonged and refractory status epilepticus. *Epilepsia.* 2005;46(6):967-9.
4. Rodan LH, Aviv RI, Sahlas DJ, Murray BJ, Gladstone JP, Gladstone DJ. Seizures during stroke thrombolysis heralding dramatic neurologic recovery. *Neurology.* 2006;67(11):2048-9.
5. Hafeez F, Razaq MA, Levine RL, Ramirez MA. Reperfusion seizures: a manifestation of cerebral reperfusion injury after administration of recombinant tissue plasminogen activator for acute ischemic stroke. *J Stroke Cerebrovasc Dis.* 2007;16(6):273-7.