

Idiopathic Free-Floating Thrombus of the Common Carotid Artery

Brian Silver, Irene Gulka, Michael Nicolle, Ramesh Sahjpaul,
Vladimir Hachinski

ABSTRACT: Background: The observation of an intraluminal common carotid artery thrombus overlying a wall defect at ultrasonography or angiography is unusual. To our knowledge, there are no previous reports of a free-floating thrombus in the common carotid artery. **Case Report:** A 45-year-old woman who was previously healthy and on no medications presented with acute hemiparesis and aphasia. Following testing that included carotid duplex and transcranial Doppler ultrasonography, diffusion-weighted magnetic resonance imaging, and digital subtraction angiography, the patient underwent emergency open embolectomy. No underlying wall defect was seen at the time of imaging or surgery. No obvious hypercoagulable state could be identified. Her NIH Stroke Scale score improved from 26 at admission to 2 at three months and 1 at one year. **Conclusions:** Multimodal imaging may have improved diagnosis and management in this patient with a unique finding. The source of the thrombus remains obscure.

RÉSUMÉ: Thrombus flottant idiopathique de la carotide primitive. Introduction: Il est inusité d'observer un thrombus intraluminal au niveau d'une lésion de la paroi de la carotide primitive à l'échographie ou à l'angiographie. À notre connaissance, il n'existe pas de cas rapporté d'un thrombus flottant dans la carotide primitive. **Histoire de cas:** Une femme âgée de 45 ans, en bonne santé et ne prenant aucun médicament, a consulté pour une hémiparésie aiguë avec aphasie. Suite à une investigation comprenant un duplex carotidien, une échographie Doppler transcrânienne, une résonance magnétique par diffusion pondérée et une angiographie digitalisée par soustraction, la patiente a subi une embolectomie ouverte d'urgence. Aucune lésion pariétale sous-jacente n'a été observée à l'imagerie ou à la chirurgie. Aucun problème d'hypercoagulabilité n'a été identifié. Son score au NIH stroke scale s'est amélioré, de 26 qu'il était à l'admission à 2 trois mois plus tard et à 1 après un an. **Conclusions:** L'imagerie multimodale a probablement aidé au diagnostic et au traitement de cette patiente porteuse d'une anomalie inusitée. La source du thrombus demeure obscure.

Can. J. Neurol. Sci. 2002; 29: 97-99

The unexpected detection of a common (CCA) or internal (ICA) carotid artery thrombus at angiography or carotid duplex ultrasonography (CUS) is unusual.¹⁻⁴ To our knowledge, no previous documentation of an apparent free-floating thrombus within the CCA alone exists. We report such a phenomenon in a 45-year-old woman.

PATIENT

A 45-year-old right-handed woman began having severe vomiting and diarrhea. During one of several trips to the bathroom, she was heard falling to the floor, and was found unable to move her right side. She presented to our hospital four hours after symptom onset. She had no recent illnesses and had not been taking any medications including hormone replacement therapy or birth control pills. Cerebrovascular risk factors included a 25-year, one pack per day smoking history and a family history of heart disease and stroke. Her initial vital signs were unremarkable. Her general examination was remarkable for a harsh,

rumbling left neck bruit. She was lethargic and intermittently agitated. She was mute and unable to follow commands. Cranial nerve examination showed a gaze tendency to the left, decreased response to visual threat on the right and a right facial droop. Her right upper extremity was flaccid and she withdrew her right lower extremity to noxious stimulation only. A Babinski sign was present on the right. Her National Institutes of Health Stroke Scale (NIHSS)⁵ score was 26.

Initial hematological studies showed a mild anemia and a neutrophilic leukocytosis. Partial thromboplastin time (PTT) and international normalized ratio (INR) were within normal limits. Electrocardiography was normal. A CT scan of the head 4.3 hours after

From the Departments of Neurology, Henry Ford Hospital, Detroit, MI, USA (BS) and Neuroradiology (IG) and Clinical Neurological Sciences (MN, RS, VH) at the University of Western Ontario, London Health Sciences Centre, London, Ontario, Canada.

RECEIVED JANUARY 18, 2001. ACCEPTED IN FINAL FORM OCTOBER 2, 2001.
Reprint requests to: Brian Silver, Department of Neurology, Henry Ford Hospital, 2799 West Grand Boulevard, K-11, Detroit, MI, USA 48202

symptom onset was normal. Initial attempts at MRI failed owing to severe agitation. Emergency CUS 7.3 hours after symptom onset showed a thrombus in the left common carotid artery measuring approximately 2.6 cm in length x 0.5 cm in cross section without an underlying arterial defect (Figure 1). Flow was seen around the thrombus on color-flow imaging and flow velocities were slightly reduced in the left ICA compared to the right. No atheromatous disease was identified. A repeat CT 10 hours after symptom onset showed an early left frontoparietal infarction not seen on the earlier film. At this time, the patient was paralyzed and intubated because of agitation. An MRI with diffusion-weighted imaging 10.5 hours after symptom onset showed hyperacute infarctions in the territory of the left middle cerebral artery (MCA) including temporal, temporo-occipital, high parietal and frontal convexities (Figure 2). Less than a third of the presumed area of MCA territory supply appeared to be infarcted. Digital subtraction angiography 12.4 hours after onset showed an intraluminal thrombus in the left CCA approximately two vertebral bodies in length, located proximal to the bifurcation, which was normal (Figure 3). The proximal left CCA appeared normal without any evidence of atheromatous disease. Contrast was seen around the filling defect. Multiple small-branch occlusions of the left MCA with absent flow distally in the posterior frontal region and angular artery were observed. There was minimal collateral flow. Other vessels were normal. Transcranial Doppler ultrasonography performed at the time of angiography showed decreased velocity of flow and delayed upstroke in the left MCA. At 13.5 hours, transthoracic echocardiography was normal.

On the basis of the findings she underwent emergency surgical removal of the thrombus, 14 hours after symptom onset. A linear 3 cm fresh thrombus was identified in the distal CCA, with the distal portion approximately 0.5–1 cm below the carotid bifurcation. Following arteriotomy there was modest back-flow from the ICA. The thrombus was not occluding the entire lumen of the CCA. The artery appeared normal without any obvious defect in the endothelial lining. The thrombus was only lightly adherent to the arterial wall and was easily removed from it. Following a left carotid embolectomy, she received intravenous heparin for 48 hours.

Twenty-four hours after surgery, she was alert and mute, but followed commands. She had a right facial droop, a left gaze tendency, a flaccid right arm, and weak right leg. Her NIHSS was 15. An MRI two days after symptom onset showed no change from the initial one. Transcranial Doppler ultrasonography one day after symptom onset showed improvement of the left MCA velocity waveform. Transesophageal echocardiography 19 days after symptom onset showed no evidence of thrombus, aortic atherosclerosis, or intracardiac shunting on bubble study. A hypercoagulable workup, including lupus anticoagulant antibody and anti-cardiolipin antibody was negative. No obvious source of malignancy could be identified. Her anemia was due to chronic iron deficiency. She was discharged home 35 days after symptom onset on enteric-coated aspirin (325 mg per day) and ferrous sulfate.

At three months, she was at home and performing all activities that she had been doing prior to symptom onset. She had a right facial droop, dysarthria, and right hand weakness. Her NIHSS was 2. At one year, her NIHSS score had improved to 1 because of resolved dysarthria.

DISCUSSION

A thrombus in the CCA or ICA is an unusual phenomenon, occurring in approximately 4 per 1000 angiograms performed during symptoms of cerebral ischemia.¹ There are few

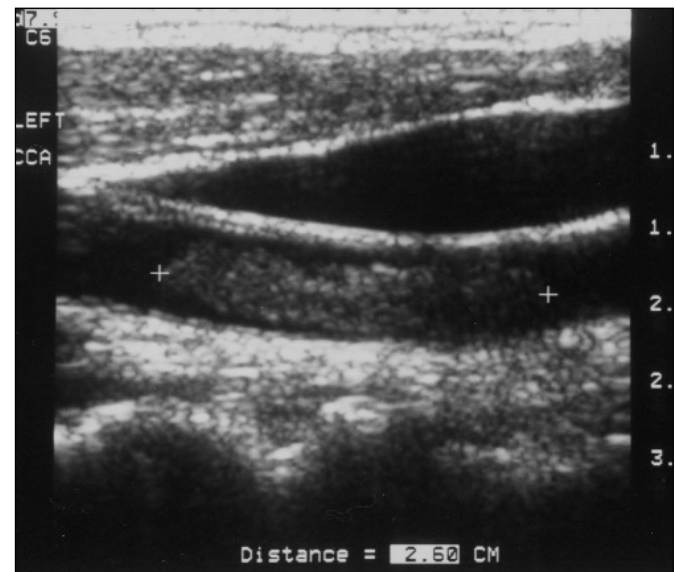


Figure 1: Gray scale, sagittal view carotid ultrasound of the left common carotid artery at presentation showing thrombus and no apparent underlying wall defect. By convention, the patient's head is at left and feet at right.

documented patients with discrete CCA thrombi¹⁻³ and, in all these reports, disease of the underlying wall was present, on which the thrombus was presumed to have formed. The patient in this report is unique because the CCA thrombus was not associated with an underlying wall defect, suggesting that the thrombus was actually an embolus that had become trapped in the CCA. The vascular occlusions distally were likely small embolic debris which had broken off the distal end of the thrombus. The source of the embolus is unclear because there was no evidence of atheromatous disease on ultrasound, on angiography, or at surgery. It is possible that a small dissection at the site of the thrombus was present but was not seen at angiography or at surgery. Besides an occult dissection, another possibility for the occurrence of the thrombus is a hypercoagulable state due to dehydration following vomiting. Aside from dehydration, no other cause for a hypercoagulable state (such as malignancy or an antibody syndrome) could be found.

Carotid duplex ultrasonography and transcranial Doppler ultrasonography did not show evidence of gross hemodynamic compromise, although velocities in the ICA and MCA were mildly decreased on the left. The decreased velocities and altered waveform in the left MCA may have been due to distal occlusions and/or the proximal stenotic effects of the thrombus.

Diffusion-weighted imaging was helpful in this situation because it helped define tissue which had probably already undergone infarction and tissue which was at risk but potentially salvageable. In the absence of formal cerebral blood flow studies, the presumed ischemic penumbra was defined as the mismatch between what was seen on structural neuroimaging and what was seen clinically. The patient's significant

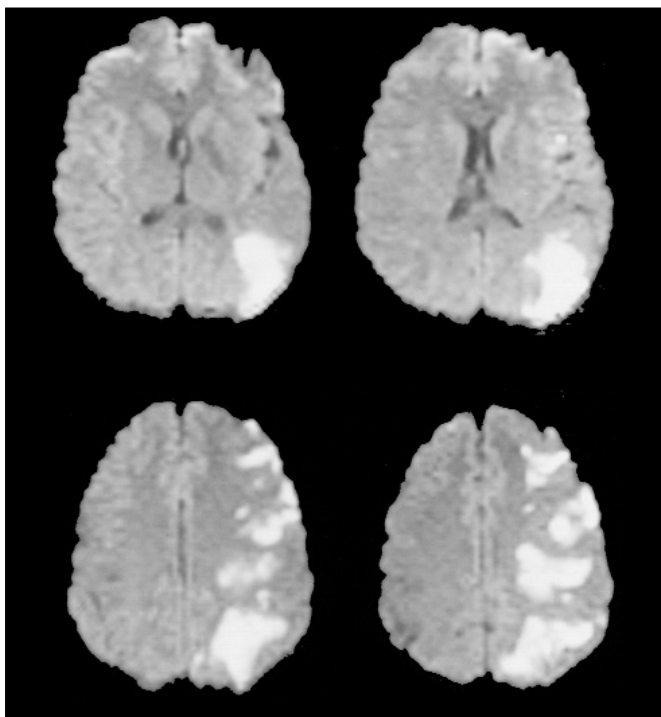


Figure 2: Diffusion-weighted magnetic resonance imaging at presentation showing acute frontal, temporal and parietal infarctions, estimated at less than one-third of the middle cerebral artery territory. By convention, the right hemisphere is at left and the left hemisphere is at right.

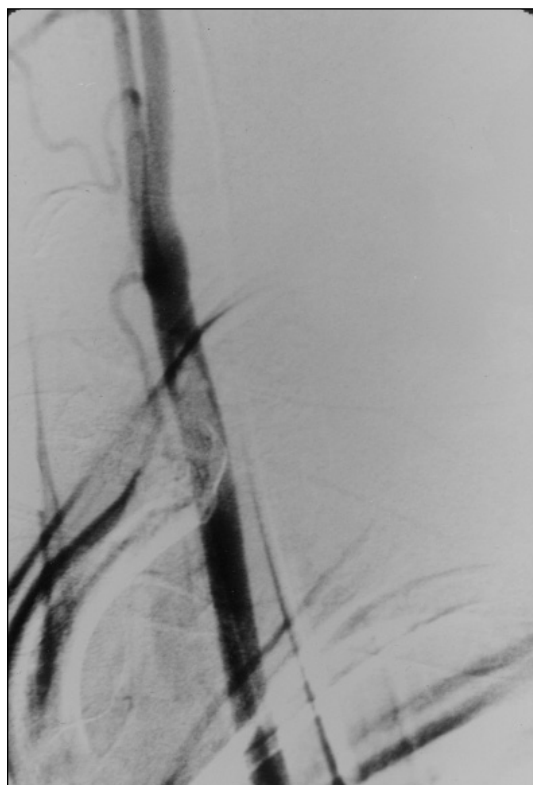


Figure 3: Digital subtraction angiography showing the left common carotid artery thrombus without underlying wall defect.

improvement at 24 hours and at three months suggests that this theory was correct.

Surgery was predicated on the suspicion that further emboli from the thrombus would produce more infarction. Additionally, there existed the possibility that the thrombus was also exerting a hemodynamic effect. Whether heparin alone would have been sufficient is unanswerable. Some small prospective series report similar effectiveness with heparin (and possibly even better results) as compared to emergency embolectomy.^{1,3,4,6-8} These reports differ from this one because (1) they refer to thrombi within the ICA, which may be exposed to different flow dynamics, and (2) most patients in these reports had underlying vessel wall abnormalities. Whether the extrapolation of the observations in these series to this patient would have been appropriate is, at best, uncertain.

This report was presented at the 35th annual Canadian Congress of Neurological Sciences in Ottawa, Ontario on June 17, 2000 as part of the Canadian Consults in Stroke Competition sponsored by AstraZeneca Pharmaceuticals.

REFERENCES

1. Biller J, Adams HP Jr, Boarini D, et al. Intraluminal clot of the carotid artery. A clinical-angiographic correlation of nine patients and literature review. *Surg Neurol* 1986;25:467-477.
2. Dunnick NR, Schuette WH, Shawker TH. Ultrasonic demonstration of thrombus in the common carotid artery. *AJR Am J Roentgenol* 1979;133:544-545.
3. Pessin MS, Abbott BP, Prager RJ, Batson RA, Scott RM. Clinical and angiographic features of carotid circulation thrombus. *Neurology* 1986;36:518-523.
4. Caplan LR, Teal PA. The moving embolus – a case report. *J Neuroimaging* 1993;3:195-197.
5. Lyden P, Brott T, Tilley B, et al. Improved reliability of the NIH Stroke Scale using video training. NINDS TPA Stroke Study Group. *Stroke* 1994;25:2220-2226.
6. Caplan L, Stein R, Patel D, et al. Intraluminal clot of the carotid artery detected radiographically. *Neurology* 1984;34:1175-1181.
7. Buchan A, Gates P, Pelz D, Barnett HJ. Intraluminal thrombus in the cerebral circulation. Implications for surgical management. *Stroke* 1988;19:681-687.
8. Combe J, Poinsard P, Besancenot J, et al. Free-floating thrombus of the extracranial internal carotid artery. *Ann Vasc Surg* 1990;4:558-562.