

Fibre types in the skeletal muscle of blackspot seabream (*Pagellus bogaraveo*, Brunnich) juveniles: a histochemical, immunohistochemical and ultrastructural study

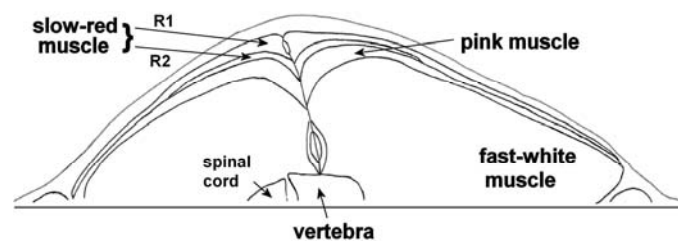
P. Silva^{*,**}, L. M. P. Valente^{*,**}, F. Malhão^{*,**}, M. H. Galante^{**}, R. A. F. Monteiro^{*,**} and E. Rocha^{*,**}

* ICBAS – Institute of Biomedical Sciences Abel Salazar, UPorto - University of Porto, Portugal

** CIIMAR – Interdisciplinary Centre for Marine and Environmental Research, CIMAR Associated Laboratory, University of Porto, Portugal.
erocha@icbas.up.pt

The aim of this work was to gain insights into the muscle fibre phenotype and ultrastructure in blackspot seabream juveniles, a potential candidate for Portuguese aquaculture. Firstly, we used a panel of isoform-specific antibodies as well as histochemical staining for myosin ATPase and for SDH enzyme activity (a marker for mitochondrial content and oxidative metabolism) to identify myosin expression. Secondly, muscle fibre types were also identified by their fine structure where differences in qualitative and quantitative features were studied. The combination of these two powerful approaches contributed to understand the muscle fibre phenotype of blackspot seabream juveniles. We observed that the main part of the musculature consisted of fast-white fibres, with a narrow strip of slow-red fibres situated superficially adjacent to the lateral line. A zone of intermediate-pink muscle fibres was inserted between those muscle domains (Fig. 1).

Fig. 1. Drawing of transverse section of juvenile sampled at anal vent



According to their metabolism, fast-white muscle fibres were identified histochemically by a lack of SDH-activity. Fast-white fibre mATPase activity showed a trend to alkaline stability. In regard to fine structure, large fast-white fibres were packed with myofibrils occupying 85% of the fibre volume and arranged in a radial manner. Fast-white fibre mitochondria were scarce (1%) and lipids were entirely lacking (Fig. 2). Slow-red fibres were identified histochemically by their intense staining for SDH-activity and by their alkaline-labile mATPase activity. Morphologically, slow-red fibres were relatively small and usually highly vascularised as compared to fast-white fibres. The slow-red fibres cytoplasm contained abundant mitochondria (21%) together with lipid droplets (3.6%). Slow-red myofibril cross sections were approximately polygonal in shape, apart from those peripherally located, which showed a radial arrangement (Fig. 2). Intermediate-pink muscle fibres had intermediate levels of oxidative enzymatic activity, with lower levels of oxidative activity than that found in slow-red muscle. Myofibrillar ATPase activity was intermediate between slow-red and fast-white fibre activities, mostly with high alkaline stability. Similarly, the morphological characteristics of intermediate-pink fibres were in many aspects intermediate between those of slow-red and fast-white fibres, *e.g.*, in regards to the arrangement of myofibrils, to the number of mitochondria or to the lipid amount.

References

[1] P. Silva, A. M. Rowlerson, L. M. P Valente, M. Olmedo, R. A. F. Monteiro, E. Rocha, *Tissue Cell*, 40 (2008) 447.

Financed by FCT: PhD Grant SFRH-BD-14068-200 and pluriannual projects.

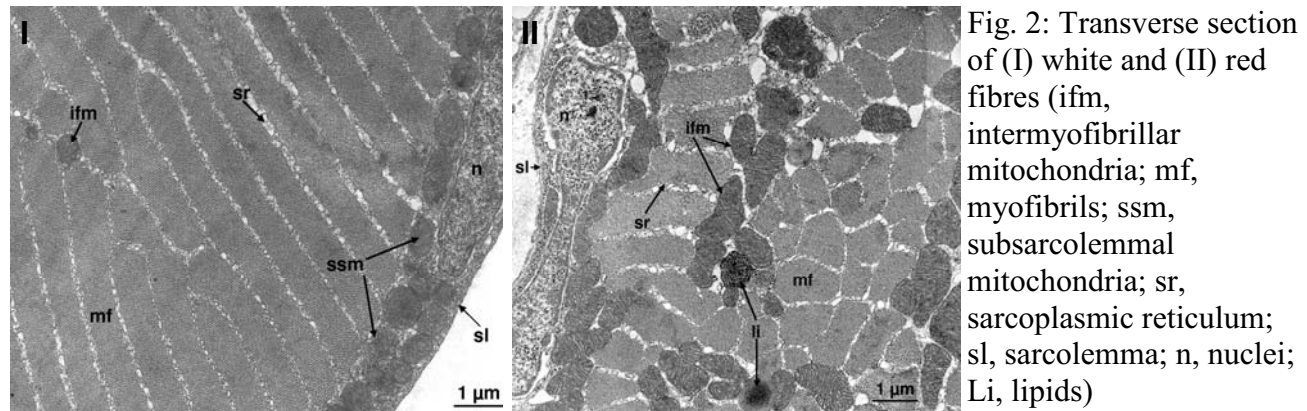


Fig. 2: Transverse section of (I) white and (II) red fibres (ifm, intermyofibrillar mitochondria; mf, myofibrils; ssm, subsarcolemmal mitochondria; sr, sarcoplasmic reticulum; sl, sarcolemma; n, nuclei; Li, lipids)

Surprisingly, an additional slow-red fibre type was identified at the level of transverse septum next to the intermediate-pink muscle (Fig. 4). Our study does not allow conclusions about the exact nature of this fibre type myosin composition, although the combination of differences in both ATPase activity and immunoreactivity do suggest they contain different isoforms of myosin. However, whether these fibres represent some hybrid fibres or not, it cannot be answered solely by the methods used in this study.

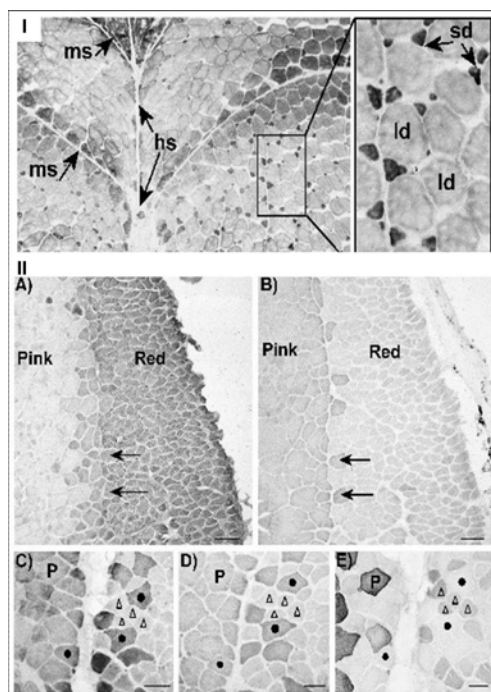


Fig. 3: Transverse section of white fibres stained for (I) mATPase activity after mild alkalai pre-incubation and immunostained for (II) A – 4/96; B – BA-F8; C - BA-G5; D - BA-F8 and E - SC-71 (Adapted from [1])

Anti-myosin antibodies used in this study: 4/96 polyclonal anti-fish slow myosin; BA-G5: monoclonal anti-mammalian cardiac alpha myosin; SC-71: monoclonal anti-mammalian type 2A myosin and BA-F8: monoclonal anti-mammalian slow-beta myosin

(I) Symbols: ld, large diameter fibres, sd, small-diameter fibres. Ms, myosept, hs, horizontal septum. Scale bar = 50 μm (II) for orientation, the same two fibres are indicated with arrows. P – Pink; Scale bar A and B = 100 μm and C, D and E = 50 μm