

# Primary Spinal Malignant Melanoma of Spinal Cord and Conus Medullaris

Gordan Grahovac, Tonko Marinovic, Damir Tomac, Smiljka Lambasa

Can J Neurol Sci. 2013; 40: 104-105

Primary malignant melanoma of the central nervous system is an extremely rare neoplasm and accounts for approximately 1% of all melanoma cases. The occurrence of this lesion in the spinal cord is even rarer.<sup>1-3</sup> Magnetic resonance imaging features of melanoma are determined by the degree of pigment melanin and the presence of acute or chronic hemorrhage and can be easily misdiagnosed with other central nervous system tumors.<sup>2,3</sup> The pathologic examination is critical for proper diagnosis. We report case of primary spinal melanoma.

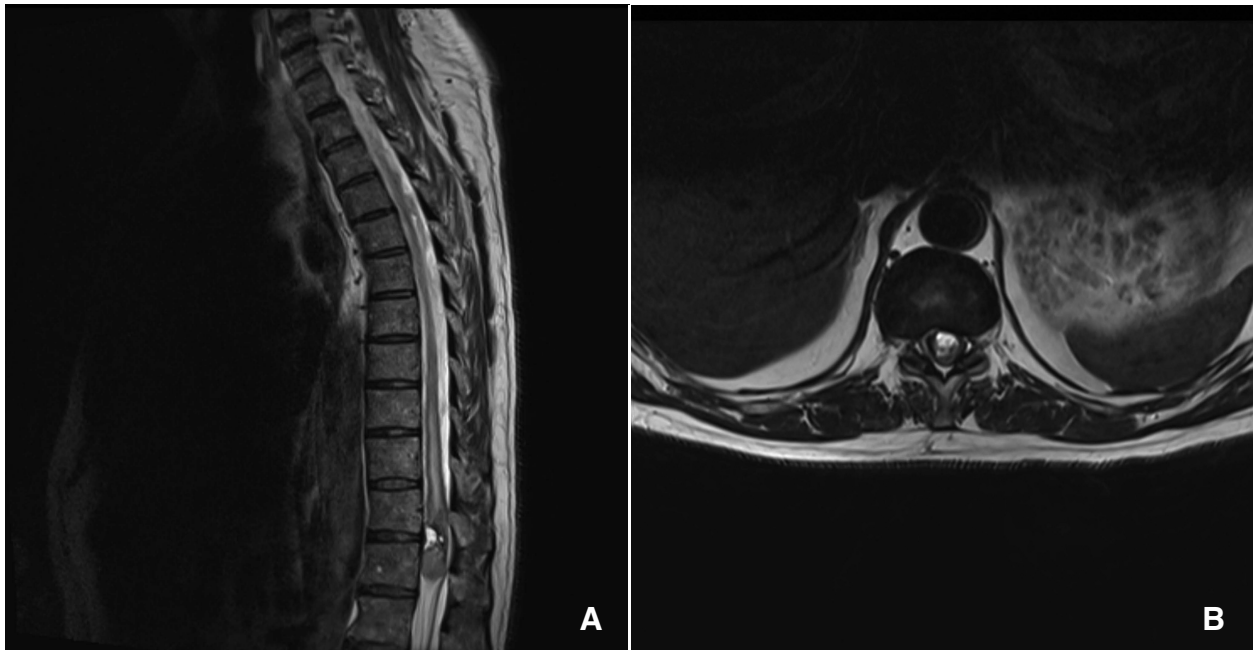
## CASE REPORT

A 76-year-old man presented with a two month history of progressively worsening bilateral sciatica and weakness in the lower extremities, which failed to respond to medical treatment. Neurological examination revealed a 3/5 muscle power in the

lower extremities and all deep tendon reflexes were increased with positive Babinski sign. The sensation of both legs was impaired. There was bladder dysfunction.

Magnetic resonance (MR) imaging revealed well defined intramedullary mass arising of the conus medullaris at the level T12 vertebrae. The tumor was hyperintensive on T1-weighted images and hypointensive on T2-weighted images. The spinal cord was slightly swollen adjacent to the upper border of the mass and showing signs of syringomyelia at the T9-T11 level (Figures 1A, 1B).

The patient underwent T11-T12 laminectomy in the prone position. We found subdural well encapsulated black tumor mass which was attached to the conus medullaris. The tumor invaded the central canal of the spinal cord (Figure 2). Unfortunately, because the tumor invaded the central canal we could not

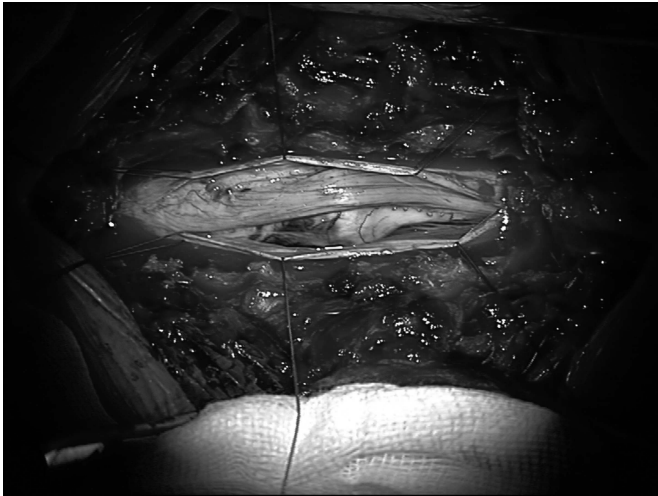


**Figure 1:** A) Sagittal T2-weighted image showing at the T12 level a well-defined lesion of conus medullaris, which is somehow hypointense compared with the spinal cord, B) Axial T2-weighted images demonstrate the intramedullary position of the tumor.

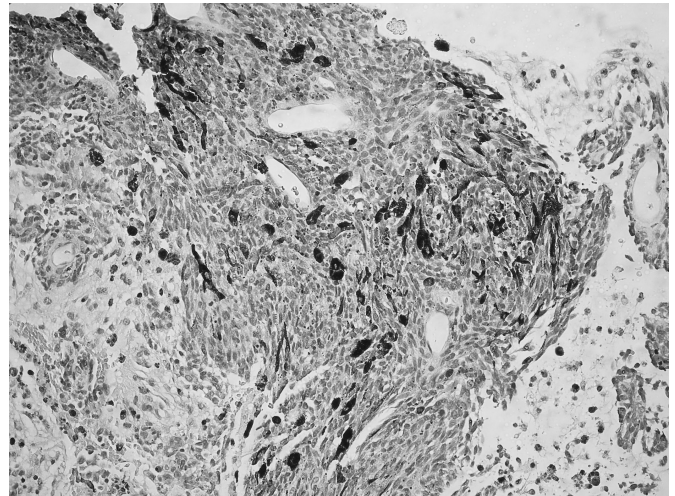
From the Department of Neurosurgery (GG, TM, DT), Department of Pathology (SL), Clinical Hospital Dubrava, Zagreb, Croatia.

RECEIVED MAY 16, 2012. FINAL REVISIONS SUBMITTED AUGUST 20, 2012.

Correspondence to: Gordan Grahovac, Department of Neurosurgery, Clinical Hospital Dubrava, Av. Gojka Suska 6, HR-10000 Zagreb, Croatia. Email: ggrahov@mef.hr.



**Figure 2:** Intraoperative picture of black colored encapsulated tumor mass that is attached to the conus medullaris.



**Figure 3:** Hematoxylin and eosin stain section of the tumor showing tumor cells with moderate cytoplasm and vesicular nuclei containing black granular pigment (magnification, x 200)

remove all tumor tissue. The postoperative period was uneventful.

A search for the primary melanoma site outside of the central nervous system was performed with all results negative. The patient refused radiation therapy and chemotherapy. The patient is still alive three years and six months after surgery and he does not have any significant neurological deficit.

On histopathological examination, the morphology of tumor cells revealed highly cellular tumor with extensive intracellular pigmentation (Figure 3). Immunohistochemical reactions for S100 and HMB-45 showed large areas of immunoreactivity. Based on these findings, a primary spinal melanoma of conus medullaris was diagnosed.

## DISCUSSION

Primary spinal melanoma is a very rare clinical entity, occurring most often in the middle or lower thoracic cord in the middle age group and affecting both sexes equally.<sup>2,3</sup> There are two possible theories that explain the origin of the primary spinal melanoma. The first theory explains that these cells arise from melanoblasts accompanying the pia sheets of vascular bundles, and the second theory explains that these cells arise from neuroectodermal rest cells during embryogenesis.<sup>1,2,4</sup> To establish the diagnosis of primary spinal melanoma of the central nervous system according to Hayward criteria, it is necessary to rule out melanoma outside or inside of the central nervous system with histopathology confirmation of melanoma.<sup>2</sup>

The method of choice in the diagnosis of spinal cord melanoma is magnetic resonance imaging.

Distinction of spinal lesion based on morphologic or signal intensity at magnetic resonance is difficult.<sup>5</sup> Spinal cord melanoma present with slightly increased intensity on T1-weighted images relative to that of the spinal cord, and the same or lower signal intensity on T2-weighted images. The tumor can show slightly increased signal after intravenous administration of a gadolinium contrast. The free paramagnetic radical from melanin and paramagnetic products from hemorrhages alter MR

signal which can easily lead to erroneous diagnoses. Primary spinal malignant melanoma can be misdiagnosed as intramedullary ependymoma or hemorrhagic lesions.<sup>1,4,5</sup> In our case, the appearance of the lesion on magnetic resonance images was misdiagnosed for intramedullary ependymoma.

The treatment of intramedullary malignant melanoma is difficult, and the best treatment is surgical excision of lesion when this is possible. Radiation therapy is recommended after surgery, and chemotherapy is also a possible treatment after surgery and postoperative radiation therapy.<sup>3,4</sup> Mean survival time among patients who underwent surgical excision, alone or with additional treatment, is six years and seven months.<sup>2,3,6</sup> Diagnosis of primary spinal malignant melanoma must be considered when magnetic resonance images show well circumscribed lesion with paramagnetic signal properties. It is also important to stress that primary spinal melanoma has a better prognosis than the same lesion with metastatic origin.

## REFERENCES

1. Farrokh D, Fransen P, Faverly D. MR findings of a primary intramedullary malignant melanoma: case report and literature review. *AJNR Am J Neuroradiol*. 2001 Nov-Dec;22(10):1864-6.
2. Hayward RD. Malignant melanoma and the central nervous system. A guide for classification based on the clinical findings. *J Neurol Neurosurg Psychiatry*. 1976 Jun;39(6):526-30.
3. Larson TC, 3rd, Houser OW, Onofrio BM, Piepgras DG. Primary spinal melanoma. *J Neurosurg*. 1987 Jan;66(1):47-9.
4. Zadro I, Brinar VV, Barun B, et al. Primary diffuse meningeal melanomatosis. *Neurologist*. 2010 Mar;16(2):117-9.
5. Yamasaki T, Kikuchi H, Yamashita J, Asato R, Fujita M. Primary spinal intramedullary malignant melanoma: case report. *Neurosurgery*. 1989 Jul;25(1):117-21.
6. Salpietro FM, Alafaci C, Gervasio O, et al. Primary cervical melanoma with brain metastases. Case report and review of the literature. *J Neurosurg*. 1998 Oct;89(4):659-66.