

## Abstracts.

### PHARYNX.

**Vincent's Angina in Liverpool Camp.**—H. Hastings Willis. "Medical Journal of Australia," May 5, 1917.

The observations are based on a series of eighteen cases, which came under notice last year at Liverpool Military Camp, near Sydney. The camp population varied until February from 16,000 to 18,000, and afterwards was more or less constant at 5000. The distribution of the cases did not suggest any special mode of transmission of the infection. No two consecutive cases came from the same locality. Clinically the disease resembled either diphtheria or syphilis, which was the usual admission diagnosis in the earlier cases.

Pain on swallowing was common to all cases. Swelling of the glands of the neck on the affected side was usual. Two types of case were observed. One, in which a pultaceous membrane covered the tonsils, the membrane could be easily removed, and the tonsils underneath were ulcerated. The other showed scant, if any, membrane, the tonsils were ulcerated to a variable depth in a punched-out manner, very much like a syphilitic ulcer. In the non-membranous cases inflammatory signs were often absent.

Swabbings were always taken and revealed the presence of the two causal organisms, the fusiform bacillus, and the spirillum of Vincent. The diphtheria bacillus was not present. Ordinary septic organisms were always present.

Attempts to grow the causal organisms on ordinary laboratory media under aerobic and anaerobic conditions failed. Methods of staining and examination are described. The most successful treatment was the local application of a solution of silver nitrate 5 to 10 gr. to the ounce.

Solution of hydrogen peroxide, both as a mouth wash and local application, was of value, which from the anaerobic nature of the causal organisms would theoretically be expected.

That the disease is infectious is certain; the mode of infection is not known.

While these cases were under observation the dental officers treated several cases of rapidly-spreading ulcerative gingivitis of sudden and unexplained onset, which healed quickly under local treatment. Neither amœba nor Vincent's organisms were found. The association of both conditions in one case observed leads one to suspect a similar origin. Vincent's angina must be added to the list of diseases which are the results of the aggregation of men in camps.

*A. J. Brady.*

**An Instrument to Maintain a Dry Field in Tonsillectomy.**—Sidney Israel. "The Laryngoscope," February, 1917, p. 102.

Recent reports of a large number of cases of pneumonia following tonsillectomy under general anæsthesia have stimulated Israel to devise an instrument to aspirate the blood which may find its way into the lower air-passages in these cases. The instrument consists of a bent Y-shaped metal tube which is so curved that it conforms to the contour of the nasal dorsum in order that it may lie flat and be out of the way of

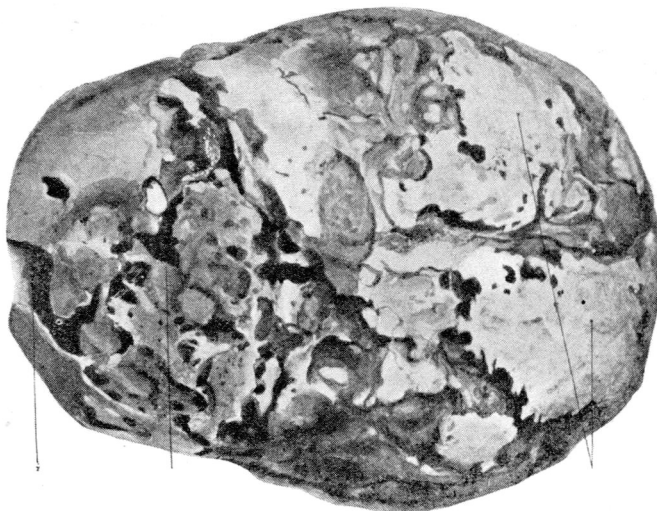
the anæsthetist and operator. To the ends of each of the metal tubes which form the prongs of the Y a piece of rubber tubing is attached. This tubing is about 5 in. in length and has a number of small perforations at the distal end. One tube is inserted into each nostril and passes along the floor of the nose and then through the nasopharynx until it extends about one-half inch below the uvula. From the single barrel of the Y-metal tube a rubber tube connects with the suction apparatus. Israel finds that the gurgling sound that accompanies a general anæsthetic in patients with excessive secretion of mucus is entirely eliminated when suction is thus employed, and that the field of operation is kept free from blood and secretions.

J. S. Fraser.

### NOSE.

**Acute Osteomyelitis of the Frontal Bone: Operation: Recovery.—**  
Herbert Tilley. "Brit. Med. Journ.," July 7, 1917.

Describes a case of acute frontal sinusitis in a lady aged thirty-five. There was intense pain in the left eye and left frontal region, accompanied by redness and œdema and rise of temperature



Specimen from a former and fatal case of cranial osteomyelitis.

At the operation the anterior wall of the sinus was found to be red and soft, and on removing it pus and air-bubbles escaped from the cavity. At the margins of the sinus points of pus were seen in the diploëtic spaces, indicating a commencing osteomyelitis of the frontal bone. The pus contained *Staphylococcus aureus* in pure culture and also a few Gram-negative bacilli.

The after-treatment consisted of daily irrigations with normal saline and hydrogen peroxide. The temperature remained at about 100° F., and there was a free discharge of pus from the wound.

A week later an orbital abscess was opened, and a fortnight after that a mammary abscess appeared, but healed after evacuation.

The condition of the sinus, however, did not improve, and, as the patient was losing ground, a second operation was performed some six weeks after the first. A large flap of scalp was reflected from the frontal region, when it was found that the whole frontal bone was inflamed and partly necrosed. Loose portions of bone were removed, and in two places the dura mater and brain substance came away with the bone. The sinus was drained freely, the flap replaced and sutured, and fomentations applied. Rapid recovery followed, and the patient was able to go home within a fortnight.

Commenting on the case, Mr. Tilley remarks that this is the only case of acute osteomyelitis following acute frontal sinusitis that he has seen cover, although a few others have been recorded.

The case also illustrates the fact that an extensive operation may save a patient in whom osteomyelitis has set in as a complication of acute frontal sinusitis, whereas if the osteomyelitis occurs after, or as the result of, operation on the frontal sinus the condition is nearly always fatal.

In the present instance the writer refrained from removing an extensive area of bone at the first operation, in the hope that free drainage of the sinus would enable the infected surrounding diploë to recover.

To expose the infected area he recommends an incision commencing in the middle line beyond the hair, passing downwards and outwards to the supra-orbital fossa and then forwards to join the frontal sinus incision at the outer angle of the eyebrow. The flap thus outlined is turned inwards.

Opinions vary as to whether osteomyelitis is more liable to follow operation on an acute or chronic empyema of the sinus.

The first ominous sign is inflammatory œdema of the soft parts which covers the margins of the bone wound, together with a rise of temperature. The infected area of bone should be freely removed, and no time should be wasted on small incisions, fomentations, or vaccines.

As measures of prophylaxis, care should be taken during frontal sinus operations to avoid infection of the exposed diploë, and the wound should be left widely open with only the lightest packing in the cavity.

Lastly, the possibility of osteomyelitis following intranasal operation of the frontal sinus is noted.

*Douglas Guthrie.*

## LARYNX.

**Infected Epistaxis in the Larynx Treated as Case of Diphtheria.**—H. L. Lynah.

"The Laryngoscope," February, 1917, p. 93.

Lynah records a case of a boy, aged seven, who was admitted to hospital December 21, 1915, with a history of laryngeal diphtheria of four days' duration. Examination showed no exudate on the tonsils and no nasal discharge. The larynx was not examined, but there was marked croup and retraction of interspaces. Intubation was not considered necessary, but antitoxin was given and the larynx poulticed. The temperature on admission was 103° F., pulse 140, respirations 36. After a series of negative cultures the child was discharged January 6, 1916. On January 28 the child was admitted to another hospital suffering from measles and "laryngeal diphtheria," and a second dose of antitoxin was administered. The resident physician, however, noted that the dyspnoea was caused by a large peritracheal abscess. On incising this a considerable quantity of pus was evacuated. The child gave a cough through the wound and then took a deep breath which aspirated

pus into the trachea and caused marked cyanosis. The Resident now rapidly introduced the tracheal dilator, and was on the point of inserting a cannula when he saw a shining foreign body in the tracheal fistula suddenly disappear downwards. After the introduction of the cannula a large amount of pus was coughed out. On the following day the tracheotomy tube was removed and an intubation tube introduced which passed below the tracheal fistula. Lynah himself now passed a bronchoscope and found the larynx partly filled with granulation tissue. The trachea was œdematous on the anterior wall and covered by granulation tissue. The tube was now passed downwards into the right bronchus and, just opposite the orifice of the superior lobe bronchus, a shining foreign body was seen and recognised as a safety pin with the keeper end presenting. The pin was easily turned, found to be closed and removed along with the bronchoscope. No anæsthetic was employed. The abscess cavity healed and the child was discharged cured.

*J. S. Fraser.*

**Repair of the Tympanic Membrane in Perforations of Long Standing.—**  
**A. M. Dunlap.** "The Laryngoscope," February, 1917, p. 83.

Dunlap believes that it is important to close perforations of the drumhead, not so much in order to improve the hearing as to stop repeated attacks of otorrhœa. Many of his patients in Shanghai were recent arrivals from the United States, where they had been living in a comparatively dry climate. In the damp climate of Shanghai, on the other hand, attacks of rhinitis brought on discharge from the ear. Dunlap, first of all, tried silver nitrate, incision of the edge of the perforation, the application of thin pieces of paper, etc., but got no success. Later he applied a 10 per cent. solution of cocaine for a few minutes, and then touched the edge of the perforation with a small cotton probe wet with a saturated solution of trichloroacetic acid. Care should be taken to wipe away all cocaine before applying the acid. The frequency of cauterisation should be regulated by the rapidity with which scar tissue is destroyed and granulating tissue secured for the entire circumference of the perforation. Treatment every third or fifth day proved to be best. Dunlap found that a perforation will not begin to close until there is an entire circle of granulation tissue. A great many cauterisations must be made in cases of long standing before there is any improvement, but when the perforation has started to close the process is very rapid. In two cases the membrane had become so thin in the part immediately surrounding the perforation that no growth of new membrane could be started until the perforation had been made much larger in order to give a firm base for the growth of granulations. At times it was necessary to use weaker solutions of the acid as the full strength apparently destroyed the new tissue. The tendency probably was to cauterise too frequently. In one case treatment was continued for more than a year without any decrease in the size of the perforation, and in three instances the perforations closed after the cessation of treatment. The size of the perforation and the age of the patient did not influence the final result, but entire absence of a definite drum membrane at some point in the circumference of the perforation did prevent cure. The hearing improved in practically every case, and, further, there was no tendency for the tympanic cavities to be involved during subsequent attacks of rhinitis.

*J. S. Fraser.*

**Wounds of the Larynx and Trachea in War.**—**Moure and Cannyt.**  
 “*Rev. de Chirurgie*,” Nos. 7 and 8, 1917; appeared in February, 1917.

The authors classify such wounds into (1) neuropathic, (2) extrinsic or extra-laryngeal, and (3) lesions of the laryngo-tracheal framework. The remarks on the last of these classes are the most interesting from the point of view of new matter. For gun-shot injuries of the laryngeal box the authors think that, as preventive treatment, tracheotomy is insufficient; they consider that it should be supplemented by laryngostomy and packing the larynx. (In the foetid condition, in which such wounds arrive at the base in France, this precaution against inhalation pneumonia is undoubtedly necessary. More often than not the missile has performed laryngostomy, and it only remains to remove the *débris* of thyroid cartilage and pack through the gap.—*Trans.*) The authors note that if, instead of tracheotomy, intercrico-thyroid laryngotomy be resorted to, subsequent decanulisation is difficult, for cicatricial stenosis has meanwhile occurred just above the tube. (Usually the higher opening is used only as an emergency, and at the earliest possible moment replaced by a high tracheotomy.—*Trans.*)

As regards the authors' classification of laryngeal stenoses (after war-injuries) into “circular or tubular” and “annular,” most surgeons would consider that these strictures are quite irregular in distribution.

Laryngeal autoplasty is referred to but not described.

*H. Lawson Whale.*

### EAR.

**Infection of the “Posterior” Mastoid Cells followed by Extra-dural Abscess.**—**J. Rozier.** “*Rev. de Laryng., d'Otol., et de Rhinol.*,” Mars 15, 1917.

In 1901 Moure described occasional aberrant mastoid cells which he named “posterior.” These are separated from all the cells communicating with the antrum by a thin shell of compact bone. Their average position is one inch behind Henle's spine, and their infection may simulate a suppurating lymphatic gland, and so cause delay in the recognition of an extra-dural abscess.

This is a moral drawn at length from a case, which is described in detail. Readers will agree with the reporter that aberrant cells should not be sought for as a part of the routine of a mastoid exenteration for acute disease, but that their possible existence should be remembered if the post-operative course of a case is not uncomplicated.

*H. Lawson Whale.*

### MISCELLANEOUS.

**Surgery of the Temporo-mandibular Articulation.**—**L. W. Dean and W. F. Boiler.** “*The Laryngoscope*,” February, 1917, p. 65.

The proximity of the temporo-mandibular joint to the middle and external ear makes it of particular interest to the otologist. The fact that it is so frequently involved in diseases of the tonsils and of the peritonsillar structures and in dento-alveolitis makes it of great importance to the laryngologist.

It is not unusual in patients who come complaining of sore throat for the X-ray picture of the temporo-mandibular joint to show a collec-

tion of fluid between the condyle and socket. This condition may be secondary to a throat lesion or may result from a focus of infection in some other part of the body. The patients usually refer the trouble to the ear, but this can be excluded by otoscopic examination.

Ankylosis of the lower jaw joint may vary in degree. According to Blair, trauma is the most common single cause and accounts for 50 per cent. of cases which were usually due to a blow or fall on the chin. Suppuration following scarlatina accounts for 20 per cent., and other cases are due to otitis media, dento-alveolar abscess, typhoid fever, pneumonia, measles, variola, diphtheria, and rheumatoid arthritis. Congenital ankylosis is very rare and is due to trauma during delivery. The obstetrical forceps may cause fracture of the base of the skull or of the mandible, and this may be followed by ankylosis. The writers record three cases: (1) Bilateral complete bony ankylosis of congenital origin cured by operation; (2) fracture of the body of the mandible, in which a fairly good result was obtained; and (3) bilateral forward dislocation of the lower jaw cured by operation.

J. S. Fraser.

---

### CORRESPONDENCE.

To the Editor of THE JOURNAL OF LARYNGOLOGY, RHINOLOGY, AND OTOTOLOGY.

SIR,—I feel that Dr. W. H. Kelson's criticisms of my paper must be answered in detail, in order that the objections which he raises may be met before they deter others from using a method which I believe to be of great value to all those who aim at the rational (and not the rule-of-thumb) treatment of deafness.

Some of Dr. Kelson's objections are well put, some of them are mere "bogies"; to be disposed of, like a certain other "Bogey," by care in play.

I must, therefore, beg you to allow me a little of your valuable space for as short a reply as I can make.

(1) Is endo-rhinocopy all plain sailing, and do the results obtained point to its great practical utility? To these I would reply "No" and "Yes." It is no more plain sailing, especially to the beginner, than is laryngoscopy or posterior rhinoscopy. I say unhesitatingly "Yes" to the second half of the question, and I should say it (on the same grounds as the "one sinner that repenteth") if I could only point to one case in which its use had been instrumental in saving hearing—and I could point to several.

(2) "It is practically useless in children." No, this is by no means the case. Granting that in its present form the instrument is a little too large (of which more anon), I have found it in some cases most valuable. In the cases quoted in my paper, one was a girl aged twelve, one a boy aged ten. With these children I had no difficulty whatever. And they were by no means solitary instances. But it is seldom that the instrument is needed in children. I have had one or two cases in which the instrument, used under an anæsthetic before operation, has yielded information most useful in character. I have had no difficulty in children younger than those mentioned. Personally, I believe that one can carry out with success in a majority of children most forms of examination, *provided* one is gentle, treats them as reasonable beings, takes them into