

# Prospective evaluation of a guideline for the selective elimination of pre-reduction radiographs in clinically obvious anterior shoulder dislocation

Michael Shuster, MD;\* Riyadh B. Abu-Laban, MD, MHSc;† Jeff Boyd, MB BS;\* Charles Gauthier, MD;\* Lance Shepherd, MD;\* Chris Turner, MD\*

## ABSTRACT

**Objective:** Research has demonstrated that experienced emergency physicians can identify a subgroup of patients with shoulder dislocation for whom pre-reduction radiographs do not alter patient management. Based on that research, a treatment guideline for the selective elimination of pre-reduction radiographs in clinically evident cases of anterior shoulder dislocation was developed and implemented. The primary objective of this study was to prospectively determine whether the treatment guideline safely eliminates unnecessary radiographs.

**Methods:** We enrolled a convenience sample of patients who presented to our rural emergency department with possible shoulder dislocation between November 2000 and April 2001. Physicians scored their level of clinical diagnostic certainty on a 10-cm visual analogue scale prior to viewing pre-reduction radiographs (if obtained). Data were collected on clinical scoring and evaluation, compliance with the guideline, and outcomes.

**Results:** A total of 63 patients were enrolled, ranging in age from 17 to 79 years (mean = 33); 87.3% were male. Emergency physicians were certain of shoulder dislocation in 59 (93.7%) patients (95% CI, 84.5%–98.2%) and complied with the treatment guideline in 52 patients (82.5%). Most deviations from the treatment guideline involved the elimination of post-reduction radiographs (which the guideline recommends for all patients). The treatment guideline eliminated 56 (88.9%, 95% CI, 78.4%–95.4%) pre-reduction radiographs, as compared to the standard practice of obtaining pre-reduction films for all cases of suspected shoulder dislocation ( $p < 0.0001$ )

**Conclusions:** Experienced emergency physicians are frequently certain of the diagnosis of anterior shoulder dislocation on clinical grounds alone and can comfortably and safely use this guideline for the selective elimination of pre-reduction radiographs. Compliance with the guideline substantially decreases pre-reduction radiographs. Validation of the guideline in other settings is warranted.

**Key words:** dislocation; shoulder dislocation; radiograph

## RÉSUMÉ

**Objectif :** Des recherches ont démontré que des médecins d'urgence expérimentés peuvent identifier un sous-groupe de patients souffrant d'une dislocation de l'épaule chez qui les radiographies pré-réduction ne modifient pas la prise en charge. À partir de ces recherches, une ligne de conduite thérapeutique pour l'élimination sélective des radiographies pré-réduction dans les cas cliniquement évidents de dislocation antérieure de l'épaule fut élaborée et mise en place. L'objectif principal de la présente étude était de déterminer de manière prospective si la ligne de conduite thérapeutique permettait d'écartier sans danger les radiographies inutiles.

From the \*Department of Emergency Medicine, Mineral Springs Hospital, Banff, Alta., and the †Department of Emergency Medicine, Vancouver General Hospital, Division of Emergency Medicine, University of British Columbia, Vancouver, BC

Received: Nov. 19, 2001; final submission: Mar. 4, 2002; accepted: Mar. 6, 2002

*This article has been peer reviewed.*

**Méthodes :** Nous avons inclu un échantillon pratique de patients qui s'étaient présentés à notre service d'urgence en milieu rural entre novembre 2000 et avril 2001 pour une dislocation possible de l'épaule. Les médecins notèrent leur niveau de certitude diagnostique sur une échelle visuelle analogue de 10 cm avant d'examiner les radiographies pré-réduction (si disponibles). Les données furent colligées quant au score clinique et à l'évaluation, au respect de la ligne de conduite et au devenir des patients.

**Résultats :** Au total, 63 patients furent inclus dans l'étude, leur âge variant entre 17 et 79 ans (âge moyen = 33 ans); 87,3 % d'entre eux étaient des hommes. Les médecins d'urgence étaient certains de leur diagnostic de dislocation d'épaule chez 59 patients (93,7 %) (IC 95 %, 84,5 %–98,2 %) et respectèrent la ligne de conduite thérapeutique pour 52 patients (82,5 %). La plupart des déviations de la ligne de conduite impliquaient l'élimination des radiographies post-réduction (que la ligne de conduite recommandait pour tous les patients). La ligne de conduite thérapeutique permit d'éliminer 56 radiographies pré-réduction (88,9 %, IC 95 %, 78,4 %–95,4 %), comparative-ment à la pratique habituelle qui était d'obtenir des radiographies pré-réduction pour tous les cas soupçonnés de dislocation de l'épaule ( $p < 0,0001$ ).

**Conclusions :** Des médecins d'urgence expérimentés sont souvent certains de leur diagnostic de dislocation antérieure de l'épaule en se basant uniquement sur des critères cliniques et peuvent avoir recours à cette ligne de conduite en toute confiance et en toute sécurité pour l'élimination sélective de radiographies pré-réduction. Le respect de la ligne de conduite réduit substantiellement le besoin de radiographies pré-réduction. La validation de cette ligne de conduite dans d'autres contextes est justifiée.

## Introduction

Current recommendations for the management of shoulder dislocation are for pre- and post-reduction radiographs;<sup>1-4</sup> however, it is common — particularly on ski hills and other out-of-hospital locales — for shoulder reductions to be performed without pre-reduction radiographs, thus saving patients from long and often painful treatment delays waiting for x-rays.<sup>5</sup> The need for both pre-reduction and post-reduction radiographs when treating anterior shoulder dislocation has recently been questioned.<sup>6-11</sup>

The discrepancy between current recommendations and common practice prompted us to undertake a prospective study to see whether emergency physicians could identify a subgroup of patients with shoulder dislocation for whom pre-reduction radiographs would not alter management.<sup>6</sup> We found that when emergency physicians were clinically certain of the diagnosis of shoulder dislocation (68% of cases) they were 100% accurate, and that pre-reduction radiographs would not have changed patient management in these cases.<sup>6</sup>

The results of that study, published in 1999, led us to develop and implement a treatment guideline (see Fig. 1), the Banff Shoulder Dislocation Guideline, for the selective elimination of pre-reduction radiographs in cases of clinically obvious anterior shoulder dislocation. The objective of the present study was to prospectively evaluate physicians' use of the Banff guideline and to determine whether the guideline safely eliminated unnecessary radiographs. A secondary objective was to identify which elements of the

history and physical exam emergency physicians found most useful in reaching a clinical diagnosis.

## Methods

### Setting

Our current prospective, observational study was conducted

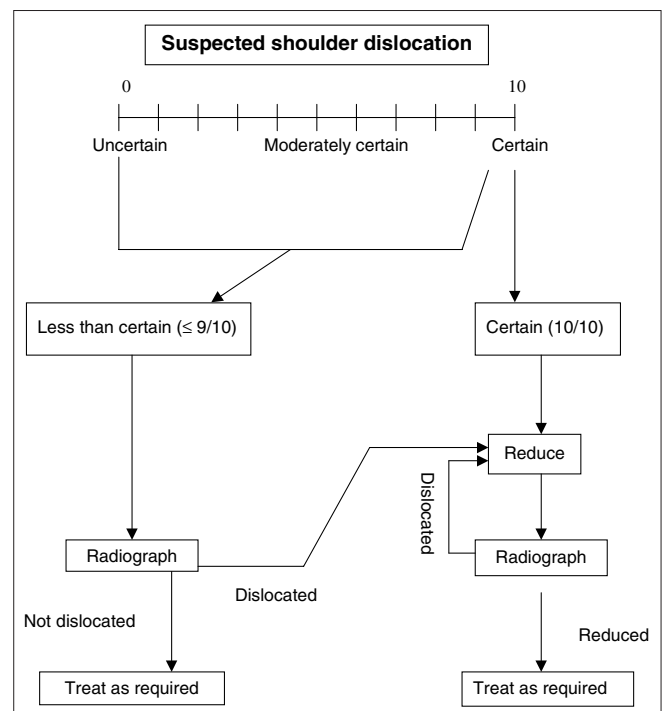


Fig. 1. Banff Shoulder Dislocation Guideline

at Mineral Springs Hospital, a rural community hospital that treats 15 000 patients annually and is staffed by full-time specialty-trained emergency physicians. The hospital is located in Banff, Alta., a mountain community of 7600, inside a national park. Over 5 million people visit Banff National Park every year, and the 3 ski resorts in the park report over 750 000 skier and snowboarder days per annum.

### Treatment guideline

We developed the treatment guideline for the selective elimination of pre-reduction radiographs in clinically obvious shoulder dislocation based on our previous findings<sup>6</sup> and circulated the guideline to our emergency physician group (Fig. 1). No training in the use of the guideline was provided, and physicians were advised that use of the guideline was voluntary.

### Study procedures

During a 5-month period, all patients presenting with suspected anterior shoulder dislocation were eligible for study inclusion. Triage nurses screened patients at the time of initial patient contact and enrolled eligible patients by initiating a study data collection form. Patients could also be enrolled by the attending emergency physician. After evaluating the patient, and before viewing pre-reduction radiographs (if any were taken), treating emergency physicians documented their clinical certainty of diagnosis on a 10-cm visual analogue scale (Fig. 1). In addition, emergency physicians were asked to rank the importance of the clinical criteria that they used to diagnose shoulder dislocation. Following reduction, physicians rated the difficulty of reduction and their level of confidence that reduction was successful. Physicians were then asked to identify which clinical findings were most helpful in confirming successful reduction. Emergency physicians' radiographic assessments were compared to the radiologist's dictated report, which was used as the diagnostic reference standard.

The study consisted of data collection alone; the study protocol did not mandate adherence to the treatment guideline. Patient management — including the use of radiography and analgesia and the method of reduction — was at the discretion of the treating physician. The Provincial Research Ethics Board (IRB [Institutional Review Board]) approved the study and, since the study did not alter care, deemed consent to be unnecessary.

### Data analysis

Data were entered into a Microsoft Excel 2000 spreadsheet and analyzed using SPSS. Binomial 95% confidence intervals for proportions, and tests of differences between pro-

portions for secondary purposes were calculated using Stata. All tests were two-tailed, and  $p \leq 0.05$  was considered statistically significant.

## Results

Between Nov. 1, 2000, and Apr. 30, 2001, 98 patients with shoulder injuries were screened. Of these, 35 were excluded because the emergency physician was clinically certain that the shoulder was not dislocated. Sixty-three patients were enrolled, and a subsequent medical records search confirmed that no other patients with dislocated shoulder were missed or excluded during the study period. Table 1 summarizes characteristics of the 63 enrolled patients, Table 2 shows emergency physicians' accuracy in making a clinical diagnosis, and Table 3 shows the ultimate radiographic diagnoses. In 59 (93.7%) of 63 cases, emergency physicians were "certain" prior to radiography that the shoulder was dislocated. In these cases, 56 (94.9%) were managed without pre-reduction radiography.

Figure 2 shows that physicians complied with the shoulder dislocation treatment guideline in 52 cases and diverged from it in 11. In 8 of 11 cases of divergence from the guideline, neither pre- nor post-reduction films were ordered. In the other 3 cases, "non-guideline" pre-reduction films were ordered by nurses who were attempting to expedite care when physicians were too busy to attend to the patient immediately. In these 3 cases, the emergency physician assessed confidence in the diagnosis of dislocation prior to viewing the radiographs. The guideline was followed in all 4 cases where the diagnosis was less than "certain." Overall, the treatment guideline eliminated 56

**Table 1. Characteristics of 63 patients with possible anterior shoulder dislocation who were enrolled in the study**

Characteristic	
Mean age, yr (and SD)	33 (14.5)
Age range, yr	17–79
Male, no. (%)	55 (87)
Skiing or snowboarding injury, no. (%)	54 (86)

**Table 2. Accuracy of emergency physicians in diagnosing clinically obvious anterior shoulder dislocation before viewing pre-reduction radiographs**

Emergency physician accuracy	No. of correct diagnoses / no. of patients (and % correct)
When "certain" of dislocation	59 / 59 (100)
When "uncertain" of dislocation	3 / 4 (75)

(88.9%, 95% CI, 78.4%–95.4%) pre-reduction radiographic series compared to the standard practice of obtaining pre-reduction radiographs for all cases of suspected shoulder dislocation. ( $p < 0.0001$ )

One of the 63 patients entered in the study had a humeral neck fracture and no dislocation. This case was 1 of 4 cases in which the physician was uncertain of dislocation, and no attempt was made at reduction. Sixty-two patients did undergo reduction, and treating physicians were clinically “certain” of successful reduction in 59 (95.2%) cases. Fifty-four of 62 patients subsequently had post-reduction radiographs, in all cases confirming successful relocation. In 3 cases (4.8%) where physicians were uncertain regarding the success of reduction, post-reduction films confirmed adequate reduction. Box 1 shows the key historical and physi-

cal elements that our physicians use to “confirm” dislocation and reduction, based on physician responses during our previous study.<sup>6</sup>

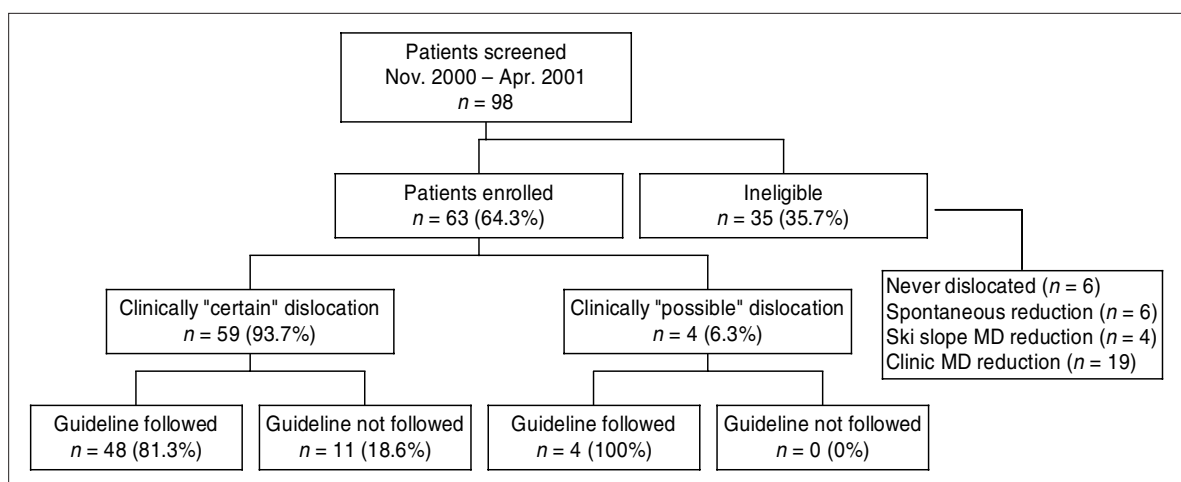
### Discussion

This study demonstrates that experienced emergency physicians can clinically diagnose anterior shoulder dislocation with a high level of accuracy, that they are comfortable following a treatment guideline for the selective elimination of pre-reduction radiographs, and that this guideline can substantially decrease pre-reduction radiography. Moreover, the data suggest that the guideline is safe and does not result in inappropriate reduction attempts or patient harm.

**Table 3. Radiographic findings for 63 patients enrolled in the study**

	Radiography		Total
	Performed (%)	Not performed (%)	
<b>Pre-reduction radiography</b>			
Physician clinically certain of dislocation, $n = 59$	3* (5.1)	56 (94.9)	59
Dislocation; no fracture	2	36	38
Dislocation + Hill-Sachs deformity	–	7	7
Dislocation + greater tuberosity fracture	1†	3	4†
Dislocation + glenoid fracture	1†	2	3†
No post-reduction radiograph	–	8	8
Physician clinically uncertain of dislocation, $n = 4$	4 (100)	0	4
Dislocation; no fracture	2	–	2
Dislocation; greater tuberosity fracture	1	–	1
No dislocation; humeral neck fracture	1	–	1
<b>Post-reduction radiography</b>			
	6	48	54

\* Radiographs ordered by nurses who were attempting to expedite care.  
 † One patient had both greater tuberosity and glenoid rim fractures.



**Fig. 2. Physician compliance with the shoulder treatment guideline**

### **A treatment guideline**

In patients with shoulder dislocation, a treatment guideline that eliminates unnecessary pre-reduction radiographs reduces costs, shortens time to reduction, decreases pain duration, and reduces ED length of stay, thus freeing resources for other patients. However, such a guideline will be adopted only if physicians are capable of accurate clinical diagnosis, if they feel the guideline is intuitively sensible and if they are willing to act on their clinical judgement without x-ray confirmation.

In the previous study we found that when emergency physicians were clinically "certain" of shoulder dislocation (68% of cases) they were 100% accurate.<sup>6</sup> However, that study mandated pre-reduction imaging; therefore, it did not demonstrate that physicians were confident enough in their clinical diagnosis to forego pre-reduction x-rays. The current study confirms that emergency physicians are clinically certain of the diagnosis in a large proportion (93.7%) of dislocations and that when they were certain, they were, again, 100% accurate.

Despite their ability to make accurate clinical diagnoses, physicians might continue to order radiographs because of the ready availability of radiographs and because of their own discomfort at performing reductions without x-ray confirmation. Our study shows, however, that in all 59 cases where physicians were clinically certain of dislocation, they proceeded with reduction, without imaging, in every case — although 3 patients had radiographs ordered by nurses. This result suggests that experienced emergency physicians generally believe it is safe and appropriate to forego pre-reduction films, and that they are willing to act on clinical judgement alone, when supported by a guideline.

#### **Box 1. Clinical criteria used to confirm dislocation and reduction**

##### **Dislocation criteria**

History suggestive of dislocation  
Severe pain with attempted passive range of motion  
Absent or severely restricted passive external rotation  
Arm in fixed position and patient unwilling to move it  
Shoulder contour lost or flattened  
Humeral head palpable anteriorly  
Absence of humeral head in the glenoid fossa

##### **Reduction criteria**

Normalization of anatomy  
"Clunk" felt on manipulation  
Elimination of pain  
Marked reduction of pain  
Improved range of motion

### **Potential savings**

In the current study, 82.5% of patients were treated according to our shoulder algorithm, and 56 sets of pre-reduction radiographs were eliminated in the 59 patients for whom the diagnosis of dislocation was certain — a decrease of 94.9%. Greater savings would be possible by eliminating post-reduction radiographs, but we do not recommend that approach. Our guideline calls for every patient to receive post-reduction radiographs, irrespective of the physician's certainty that the shoulder has been successfully reduced. This recommendation is based on the need to diagnose and evaluate any coexistent fractures and to be certain that the dislocation has been reduced. Some suggest, however, that if no fractures are evident on pre-reduction films, then post-reduction radiography may not be necessary.<sup>9</sup> This suggestion is based on data showing that emergency physicians are highly accurate in the clinical determination of shoulder reduction.<sup>6,9</sup> Our study corroborated this claim for accuracy, showing that emergency physicians were clinically certain of reduction in 59 of 62 patients (95.2%), and that successful reduction was radiologically confirmed in all 54 patients who underwent post-reduction x-ray.

Other authors have described important and potentially disastrous errors in the diagnosis of shoulder dislocation. Hendey<sup>9</sup> documented a case of persistent dislocation and glenoid fracture in a patient whom the physician was confident was "reduced." Tannebaum and colleagues<sup>10</sup> also describe a case of persistent dislocation that was "a surprise" to the physician. We therefore believe that only experienced physicians who have performed pre-reduction radiographs showing no fracture, or who can determine from history that a fracture is unlikely (atraumatic mechanism of injury), and who are certain of the reduction, should contemplate omitting post-reduction radiographs.

In this study, 12 (21%) of 56 patients who had no pre-reduction x-rays had fractures reported on post-reduction films. This proportion is in keeping with a reported 10.2%–68% incidence of fracture in anterior shoulder dislocation.<sup>9,12</sup> Fractures seen in this study included Hill–Sachs lesions, Bankart lesions and greater tuberosity fractures — all commonly associated with shoulder dislocation.<sup>3,4</sup> There was no evidence that any of these fractures were caused by manipulation, nor would we expect fractures to occur with modern reduction techniques, which involve gentle continuous traction or rotation without leverage. We found no reported cases of fracture caused by shoulder reduction in the literature from 1966 to present.

### **Limitations**

Our patients were mainly young and athletic, and our con-



clusions may not apply to the elderly, where the increased likelihood of fracture and altered response to injury might affect physician diagnostic accuracy. In addition, our physicians are highly experienced with shoulder dislocations; they may be more “certain” of their clinical diagnosis and perhaps more accurate than less experienced physicians.

Eight patients did not receive any radiographs. All were offered post-reduction films and refused because of time concerns, expense, transportation problems, or a history of recurrent dislocation. It is possible that, in this group, a fracture or persistent dislocation could have been missed and therefore that the true proportion of fractures is higher than we report.

Although physicians were always certain of reduction in cases without post-reduction radiographs and we have never found a shoulder to be dislocated when reduction was certain, without post-reduction radiographs it is conceivable that one or more shoulders remained dislocated after they were “successfully reduced.” We have not been notified of any such cases.

It could be argued that some patients we were “certain” were dislocated might not have been, since we have no radiograph to prove the dislocation. Misdiagnoses do occur, but we believe it is exceedingly unlikely that an experienced physician could be mistaken, first in thinking that there is a shoulder dislocation based on physical examination, and then, after manipulation, in observing the typical clinical findings that occur with reduction, in a patient who did not actually have a dislocation.

Finally, less experienced physicians may not be “certain” of dislocation as often as the highly experienced physicians who participated in this study, and their accuracy of diagnosis could conceivably be lower. We encourage validation of our findings in other settings.

## Conclusion

Experienced emergency physicians are frequently certain of the diagnosis of anterior shoulder dislocation on clinical grounds alone and can comfortably and safely use our guideline for the selective elimination of pre-reduction radiographs. Such a guideline can substantially decrease the need for pre-reduction radiography.

**Competing interests:** None declared.

**Contributors:** Dr. Shuster proposed the study. All authors contributed to the study design. Drs. Shuster, Boyd, Gauthier, Shepherd, and Turner collected the data. Drs. Shuster and Abu-Laban interpreted the data, and Dr. Abu-Laban performed the statistical analysis. Dr. Shuster wrote the initial draft of the manuscript, and Drs. Shuster, Abu-Laban and Boyd participated in revising the manuscript.

**Acknowledgements:** We thank the Mineral Springs Hospital emergency nursing staff, without whose assistance this study would not have been possible.

## References

1. Roberts J, Hedges J. Clinical procedures in emergency medicine. 3rd ed. Philadelphia: WB Saunders; 1998. p. 820-9.
2. Linscott MS. Joint dislocations. In: Harwood-Nuss A, Linden C, Luten R, Sternbach G, Wolfson AB, editors. The clinical practice of emergency medicine. Philadelphia: JB Lippincott; 1991. p. 382-90.
3. Simon RR, Koenigsnecht SJ. Orthopedics in emergency medicine. 3rd ed. New York: Appleton-Century-Crofts; 1995. p. 392-400.
4. Daya M. Shoulder. In: Rosen P, Danzel DF, Hockberger RS, Ling L, Marcovchick V, Marx J, et al, editors. Emergency medicine. 4th ed. St. Louis: CV Mosby; 1998. p. 709-39.
5. Macnab AJ, Cadman R, MacPhail I, Wing PC. Ski-injury research and safety initiatives in British Columbia: a review. *BC Med J* 1997;39:320-3.
6. Shuster M, Abu-Laban RB, Boyd J. Prereduction radiographs in clinically evident anterior shoulder dislocation. *Am J Emerg Med* 1999;17(7):653-8.
7. Harvey RA, Trabulsy ME, Roe L. Are postreduction anteroposterior and scapular Y views useful in anterior shoulder dislocations? *Am J Emerg Med* 1992;10:149-51.
8. Hendey GW, Kinlaw K. Clinically significant abnormalities in post-reduction radiographs after anterior shoulder dislocation. *Ann Emerg Med* 1996;28:399-402.
9. Hendey GW. Necessity of radiographs in the emergency department management of shoulder dislocations. *Ann Emerg Med* 2000;36:108-13.
10. Tannebaum RD, Kondabala RK, Stockmal PJ. Postreduction radiographs for anterior shoulder dislocation: a reappraisal [letter]. *Ann Emerg Med* 2001;37:418.
11. Hendey GW. Postreduction radiographs for anterior shoulder dislocation: a reappraisal [letter]. *Ann Emerg Med* 2001;37:419.
12. Pasila M, Jaroma H, Kiviluoto O, Sundholm A. Early complications of primary shoulder dislocations. *Acta Orthop Scand* 1978;49:260-3.

**Correspondence to:** Dr. Michael Shuster, Mineral Springs Hospital, Box 1050, Banff AB T1C 1H7; mshuster@telusplanet.net