

## The direct fluorescent antibody test for detection of *Brucella abortus* in bovine abortion material

BY M. J. CORBEL

*Ministry of Agriculture, Fisheries and Food,  
Central Veterinary Laboratory, Weybridge, Surrey*

(Received 27 June 1972)

### SUMMARY

The direct fluorescent antibody test was assessed for detection of *Brucella abortus* in bovine abortion material. *Br. abortus* organisms could be readily detected as characteristic intra-cellular clumps, in smears stained with fluorescent antibody. Counterstaining with Evans Blue was necessary to suppress tissue auto-fluorescence. The method was specific and enabled brucella infection to be differentiated, *inter alia*, from Q-fever infection.

### INTRODUCTION

At present the methods available for detection of *Brucella abortus* in abortion material include direct staining by the modified Köster method (Christoffersen & Ottosen, 1941) and the modified Ziehl Neelsen method, or isolation of the organism by culture and guinea-pig inoculation. When used conjointly these methods enable an accurate diagnosis to be made in most cases. Unfortunately, isolation by animal inoculation takes a long time and is not always practicable and so reliance is often placed on direct microscopical examination and culture. However, many samples of abortion material are unsuitable for cultural examination, even on selective media, because of overgrowth by contaminating organisms. In these circumstances presumptive diagnosis may depend solely upon the results of microscopical examination.

Although relatively specific for brucellas, the modified Köster's procedure will not differentiate them from *Coxiella burnetii* and in areas where Q-fever is prevalent this may cause serious problems in diagnosis. The direct fluorescent antibody test (FAT) appeared to offer a more specific alternative to the modified Köster's procedure and so was assessed for its value in detecting *Br. abortus* in bovine abortion material.

### MATERIALS AND METHODS

#### *Bacterial strains*

The strains used in this study were from stock cultures maintained at this laboratory.

#### *Pathological material*

Material from bovine abortions, which was submitted for routine diagnosis, was used in this study. Samples were examined by conventional staining, culture and

in some cases also by animal inoculation. Smears of abortion material known to be infected with *Coxiella burnetti*, *Campylobacter fetus* (*Vibrio fetus*), *Leptospira* spp., *Salmonella dublin*, *Salmonella enteritidis*, *Listeria monocytogenes* and *Aspergillus fumigatus* were also available for examination.

#### *Preparation of antisera*

Antiserum to *Br. abortus* was produced by intramuscular injection of a single dose of ca.  $10^{10}$  *Br. abortus* 544 organisms into 4-month-old rabbits. Blood samples were collected at weekly intervals and those showing high titres in agglutination, complement fixation and precipitin tests at 4 weeks after inoculation, were pooled and stored frozen at  $-20^{\circ}\text{C}$ . until required.

#### *Preparation of conjugate*

Pooled high titre serum was fractionated by repeated precipitation with sodium sulphate (Keckwick, 1940). The  $\gamma$ -globulin was dialysed against PBS at  $4^{\circ}\text{C}$ . until sulphate was no longer detectable with  $\text{BaCl}_2$  and, after clarification by centrifugation, the protein content determined by ultra-violet absorption spectroscopy according to Cullen & Corbel (1970). The protein concentration was adjusted to 1.0 g. per 100 ml. and the pH raised to 9.5 by addition of 1.0 M- $\text{Na}_2\text{CO}_3$ . Fluorescein isothiocyanate (FITC) (Isomer 1; British Drug Houses, Poole) dissolved in 0.1 M carbonate-bicarbonate buffer, pH 9.5, was then added to give a final proportion of 10 mg. FITC per 1.0 g. of protein, and the mixture agitated in a sealed flask on a magnetic stirrer for ca. 18 hr. at  $4^{\circ}\text{C}$ . The reaction was stopped by adjusting the pH to 7.0 and excess FITC removed by dialysis against PBS at  $4^{\circ}\text{C}$ . Residual unreacted FITC and labelled globulin with non-specific staining activity were removed by absorption with acetone-dried bovine liver powder at a final concentration of 50 mg. per ml. After absorption for 2–3 hr. at  $4^{\circ}\text{C}$ . the globulin was recovered after centrifugation at 30,000 g for 15 min. The conjugate was assayed for FITC/protein ratio according to The & Feltkamp (1970) and for free FITC by thin layer chromatography on Sephadex G200 superfine according to a modification of the method of Morris (1964).

The conjugate was adjusted to pH 7.5 and sodium azide added to 0.1% final concentration and the preparation sterilized by membrane filtration. For storage, the material was kept frozen in 1.0 ml. ampoules at  $-20^{\circ}\text{C}$ .

#### *Performance of the test*

Smears of abortion material, usually bovine placenta or foetal stomach contents, were made on clean microscope slides as soon as possible after collection. The smears were fixed by thorough but not excessive heating. Sufficient conjugate was then pipetted on each slide to cover an area of ca. 10 mm.  $\times$  20 mm. of the smear. Reaction was allowed to proceed in a moist atmosphere at  $37^{\circ}\text{C}$ . for 30 min. Surplus conjugate was rinsed off with PBS and the smears washed in two changes of PBS with constant agitation. The preparations were then counterstained with 0.25% Evans Blue in 0.15 M- $\text{NaCl}$  for 1–2 min., the surplus stain rinsed off in PBS and the preparations mounted in buffered glycerol (90%, v/v, glycerol A.R.; 10%, v/v, 0.1 M phosphate buffer, pH 8.0).

Smears were examined with a Leitz Orthoplan fluorescent microscope fitted with HBO 200 mercury burner, 4 mm. BG 38 + 5 mm. BG 12 exciting filters and incident illuminator (after Ploem) with TK 495 dichroic beam-splitting mirror and 490 nm. suppression filter. Photographs were made on Kodak High Speed Ektachrome film (EH 135-20) with exposure times of *ca* 2 min.

#### *Evaluation of smears*

Smears were scanned for fluorescent areas under low power magnification ( $\times 125$ ) and on locating any such areas closer inspection was made under high power magnification ( $\times 1250$ ). For placental smears only the presence of fluorescent intracellular organisms was considered diagnostic, but for smears of foetal stomach contents fluorescent intracellular or extracellular organisms with the morphological characteristics of brucellas were considered significant. Control smears of smooth *Br. abortus* suspensions were included in each series of tests. Blocking tests with unconjugated antiserum to *Br. abortus* were also performed to check the specificity of staining (Cherry, Goldman, Carski & Moody, 1960).

#### *Determination of the specificity of the conjugate*

The specificity of the conjugate was checked by staining heat fixed smears of pure cultures of *Aspergillus fumigatus*, *Bordetella pertussis*, *Br. abortus* 544, *Br. abortus* biotype 5, *Br. abortus* 45/20, *Br. abortus* strain 19, *Br. canis* RM6-66, *Br. melitensis* 16 M, *Br. neotomae* 5K33, *Br. ovis* 63/92, *Br. suis* 1330, *Campylobacter fetus*, *Escherichia coli*, *Francisella tularensis*, *Listeria monocytogenes*, *Pasteurella multocida*, *Proteus vulgaris*, *Pseudomonas aeruginosa*, *Staphylococcus aureus*, *Yersinia enterocolitica* NCTC 10461, *Y. enterocolitica* IX, *Y. pseudotuberculosis*.

### RESULTS

Unstained smears of bovine placental material from both infected and uninfected sources produced a pronounced yellowish fluorescence in ultra-violet light (Plate 1, fig. 1). This was sufficiently intense to obscure specific fluorescence of micro-organisms in infected tissues stained with FITC-labelled antibody. The use of Evans Blue as a counterstain did however enable this difficulty to be overcome. Uninfected tissue and also infected tissue in the absence of fluorescent antibody staining showed a uniform red fluorescence after counter-staining (Plate 1, fig. 2).

Smears of tissue infected with brucella organisms, after fluorescent antibody staining and counterstaining, showed the presence of yellowish-green fluorescent organisms of brucella morphology located in clumps apparently within cells. The surrounding uninfected cells were stained red by the counterstain (Plate 1, fig. 3). These structures were not visible in smears of uninfected tissues stained similarly nor in smears of infected tissue stained with FITC-labelled globulin from unimmunized rabbits. Occasionally in all types of preparation, isolated particles showing yellowish fluorescence or indistinct patches showing similar fluorescence, were observed. However, fluorescent clumps of intracellular organisms were not seen in

Table 1. Comparison of the results of the direct FAT for *Brucella abortus* with those of conventional tests

Number of samples	Köster's stain	Results of conventional methods		Number positive to FAT = (%)
		Culture	Animal inoculation	
47	+	<i>Brucella abortus</i>	<i>Brucella abortus</i>	47 (100)
23	+	<i>Br. abortus</i>	ND	23 (100)
11	+	—	ND	7 (63)
7	+	—	<i>Br. abortus</i>	6 (85.8)
17	+	—	<i>Cox. burnetii</i> *	0 (0)
2	+	<i>Br. abortus</i>	<i>Br. abortus</i> + <i>Cox. burnetii</i> *	2 (100)
3	—	<i>Campylobacter fetus</i>	— or ND	0 (0)
2	—	<i>Leptospira</i> spp.	<i>Leptospira</i> spp.	0 (0)
4	—	<i>Listeria monocytogenes</i>	<i>Listeria monocytogenes</i>	0 (0)
18	—	<i>Asp. fumigatus</i>	— or ND	0 (0)
12	—	<i>Salmonella</i> spp.	<i>Salmonella</i> spp.	0 (0)
5	+	<i>Salmonella dublin</i> + <i>Br. abortus</i>	ND	5 (100)
111	—	—	— or ND	2 (1.9)

ND = not done. — = negative or inconclusive.

\* Q-fever samples were accumulated over several years and include replicate smears from single animals.

smears of uninfected tissue and such fluorescent clumps were taken as the index of infection in assessing smears stained by FITC-labelled antibody.

Examination of the FITC-labelled anti-*Br. abortus* conjugate showed that it produced bright fluorescence with all of the smooth brucella strains tested, including *Br. abortus*, *Br. melitensis*, *Br. neotomae* and *Br. suis*. No staining was observed with *Br. ovis* and rough strains of *Br. abortus* and only weak staining with *Br. canis*. The other organisms tested were not stained by the conjugate with the exception of *Yersinia enterocolitica* IX and *Staph. aureus*. *Yersinia enterocolitica* IX has not been reported in bovine abortion material as yet, although other *Y. enterocolitica* strains have been detected occasionally. It was included in the present study because of its serological relationship to *Brucella* spp. (Ahvonen, Jansson & Aho, 1969; Corbel & Cullen, 1970). If it should occur it is unlikely to be confused with *Brucella* spp. because of its preferred extracellular location. The reaction of the conjugate with *Staph. aureus* was not simply the result of reaction with antibodies to this organism naturally present in the  $\gamma$ -globulin fraction, as was shown by the fact that the cross-reaction was not eliminated by absorption with *Staph. aureus* without simultaneously removing specific antibody activity and most of the  $\gamma$ -globulin.

A similar reaction was also given by FITC conjugated  $\gamma$ -globulin from uninoculated rabbits. It may have been a result of non-immune reaction between the protein A of *Staph. aureus* and the Fc-component of the  $\gamma$  G-globulins (Forsgren & Sjöquist, 1967). In any event, even though staphylococci are frequently present as contaminants in smears of abortion material, they are unlikely to be confused with

brucellas because of their morphology and location. Furthermore, *Staph. aureus* can easily be differentiated from *Brucella* spp. in smears stained by Gram's method.

Special attention was paid to the reaction of the anti-*Br. abortus*-FITC conjugate with smears of material infected with *Cox. burnetii*. No cross-reaction was obtained with this material and fluorescent intra-cellular organisms were not observed. This suggested that this method could be useful in differentiating brucellosis from Q-fever infection in cases of bovine abortion.

A series of smears of material from abortions for which a diagnosis of *Cox. burnetii* infection had been established by animal inoculation, were examined by the FAT (Plate 1, fig. 4). None of these smears gave a positive reaction to the FAT although all reacted with Köster's stain to give appearances indistinguishable from *Br. abortus* infection. Similarly smears of material from abortions, the cause of which had been determined by culture or microscopy to be infection with *C. fetus*, *L. monocytogenes*, *Salmonella* spp., *S. dublin*, *Leptospira* spp., or *Asp. fumigatus*, all gave negative reactions to the FAT. A small number of positive reactions to the FAT were obtained in smears from material in which infection with *Br. abortus* and other pathogens was simultaneously present.

The results obtained in a series of examinations of material from abortions due to various causes are summarized in Table 1.

#### DISCUSSION

The principal reason for adopting a fluorescent antibody method for detection of brucellas in smears of bovine abortion material was the necessity for differentiation of *Brucella* spp. from *Cox. burnetii*. Differentiation cannot reliably be obtained by Köster's method and indeed reliance on this may be the source of an incorrect diagnosis when culture or animal inoculation are unsuccessful or impractical. The need for an effective differential test for brucellosis and Q-fever infections under conditions where both are prevalent has been emphasized by Schweizer (1964) and by Lapraik, MacKinnon & Slavin (1967).

The direct FAT for the detection of brucellas in cultures or infected tissues has been studied by Moulton & Meyer (1958); Moody, Biegeleisen & Taylor (1961); Chistov, Pesina & Voronova (1961); Ignat'eva (1961, 1962); Janney & Berman (1962); Biegeleisen, Moody, Marcus & Flynt, (1962); Meyer (1966) and others. However, the application of this test to smears of bovine abortion material is impeded by the pronounced auto-fluorescence often encountered in these samples. The present results showed that this difficulty can be overcome by counter-staining the smears with Evans Blue. Failure to adopt some method of suppressing auto-fluorescence makes interpretation of fluorescent antibody stained smears extremely difficult. Examination of the results obtained in the present study showed that the FAT was at least as sensitive as Köster's method for detecting *Br. abortus* in smears of infected material. A comparison of the results of the direct FAT with conventional staining, culture and animal inoculation gave consistent results. The only smears giving negative reactions to the FAT and positive reactions to Köster's stain were from animals known to have been infected with *Cox. burnetii*.

The number of false positive reactions given by the FAT could not be determined accurately when the results could only be checked by Köster's method. Rather more positive reactions were obtained with the FAT than with Köster's stain but when the results of cultural examination and animal inoculation were available, these confirmed the FAT results.

On smears of placental material, a positive diagnosis was confined to those specimens in which fluorescent clumps of intracellular organisms were visible. On smears of foetal stomach contents, in many instances, more fluorescent extracellular than intracellular organisms were visible and the presence of these was considered diagnostic of *Br. abortus* infection (Plate 1, fig. 5).

Apart from differentiating *Br. abortus* from *Cox. burnetii*, the FAT also successfully differentiated it from *Listeria monocytogenes*, *Salmonella* spp., *C. fetus*, *Leptospira* spp. and fungi. These pathogens are frequently associated with bovine abortion and differentiation is essential, although not likely to be a problem in practice because of the distinctive morphology of these organisms.

These results indicated that the FAT could be of value in the examination of bovine abortion material, particularly when differentiation of brucellas from *Cox. burnetii* was necessary. In such circumstances the FAT should be used in conjunction with the modified Köster's or Ziehl Neelsen procedure. Samples negative to the FAT but positive to the tinctorial stain could then be considered as probably infected with *Cox. burnetii*.

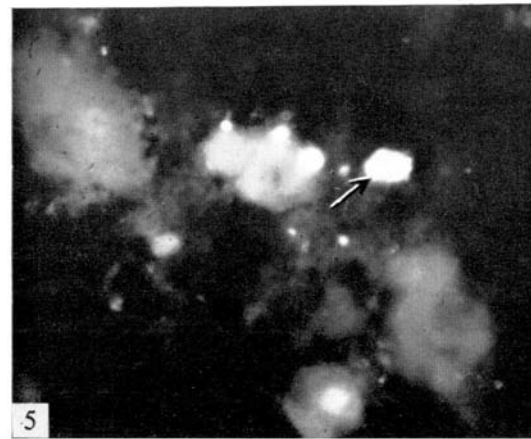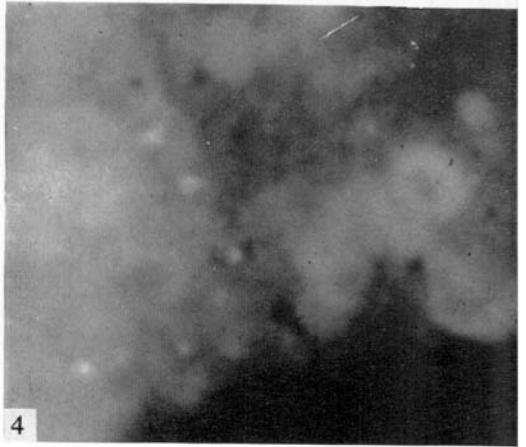
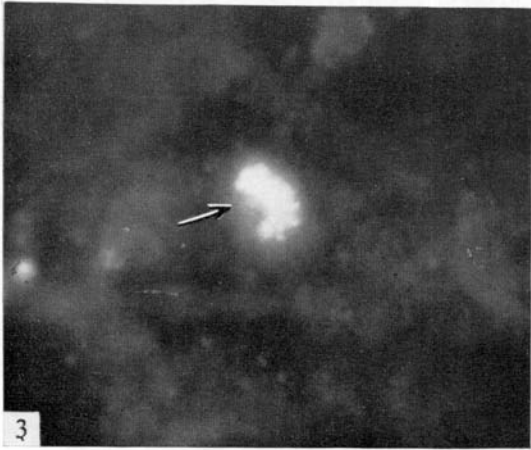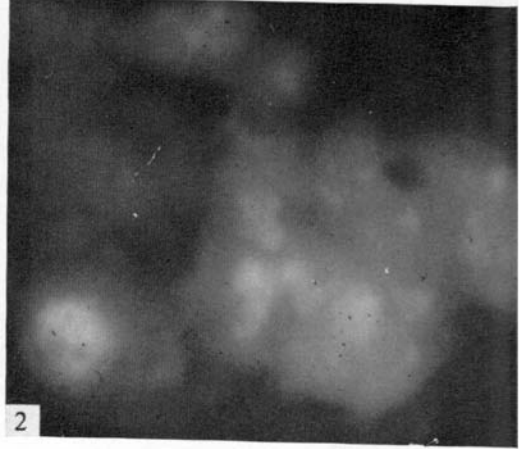
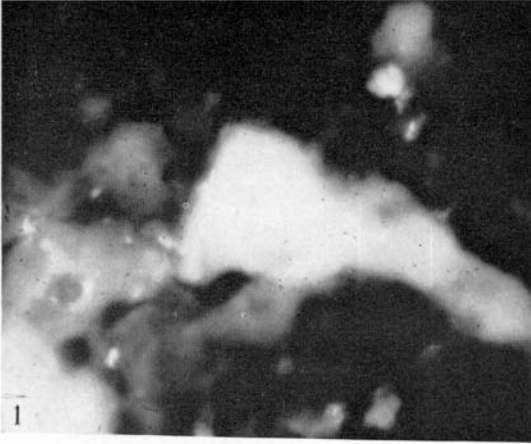
The importance of rapid and accurate identification of *Br. abortus* infection in abortion material is likely to increase as the Brucellosis Eradication Scheme of the Ministry of Agriculture, Fisheries and Food progresses and the incidence of brucellosis declines. Then it will be essential to identify sources of infection as rapidly as possible in order to prevent spread to disease-free animals. In such circumstances the FAT could be of particular value.

The author would like to thank Dr W. J. Brinley Morgan and Mr M. Gitter, M.R.C.V.S. for generously providing field material for examination. The invaluable assistance of Mrs C. A. Day, A.I.M.L.T. and Mr A. C. Hodges is also gratefully acknowledged.

#### REFERENCES

- AHVONEN, P., JANSSON, E. & AHO, K. (1969). Marked cross-agglutination between Brucellae and a sub-type of *Yersinia enterocolitica*. *Acta pathologica et microbiologica scandinavica* **75**, 291.
- BIGELEISEN, J. Z. JR., MOODY, M. D., MARCUS, B. B. & FLYNT, J. W. (1962). The use of fluorescein-labeled anti-*Brucella suis* globulin for demonstrating *Brucella* antigen in animal tissues. *American Journal of Veterinary Research* **23**, 592.
- CHERRY, W. B., GOLDMAN, M., CARSKI, T. R. & MOODY, M. D. (1960). In *Fluorescent Antibody Techniques in the Diagnosis of Communicable Diseases*. U.S. Department of Health, Education and Welfare, Atlanta, Ga.
- CHISTOV, N. P., PESINA, A. G. & VORONOVA, L. A. (1961). Primeneniye fluorestsiruyushchikh antitel dlya vyyavleniya brutsell. *Sbornik trudov Leningradskiy nauchno-issledovatel'skiy Veterinarnyy Institut* **9**, 9.
- CHRISTOFFERSEN, P. A. & OTTOSEN, H. E. (1941). Recent staining methods. *Skandinavisk veterinärtidskrift* **31**, 599.





M. J. CORBEL

(Facing p. 129)

- CORBEL, M. J. & CULLEN, G. A. (1970). Differentiation of the serological response to *Yersinia enterocolitica* and *Brucella abortus* in cattle. *Journal of Hygiene* **68**, 519.
- CULLEN, G. A. & CORBEL, M. J. (1970). Observations on some possible causes of variation in the titre of brucella antibodies in cattle. *Veterinary Record* **87**, 101.
- FORSQREN, A. & SJÖQUIST, J. (1967). 'Protein A' from *Staphylococcus aureus*. III. Reaction with rabbit  $\gamma$ -globulin. *Journal of Immunology* **99**, 19.
- IGNAT'eva, O. A. (1961). Uskorennoye opredeleniye brutsell v organizme zhivotnykh v period inkubatsii s ispol'zovaniem mechenykh izotsionat fluorestseinom antitel. *Uchenyye Zapiski Kazanskogo veterinarnogo Instituta* **81**, 57.
- IGNAT'eva, O. A. (1962). Uskorennoye opredeleniye brutsell v organizme zhivotnykh v ranney stadii inkubatsii s primeneniym fluorestsiruyushchikh antitel. *Uchenyye Zapiski Kazanskogo Veterinarnogo Instituta* **84**, 59.
- JANNEY, G. C. & BERMAN, D. T. (1962). Staining intracellular *Brucella* organisms by means of fluorescent antibodies. *American Journal of Veterinary Research* **23**, 596.
- KECKWICK, R. A. (1940). The serum proteins in multiple myelomatosis. *Biochemical Journal* **34**, 1248.
- LAPRAIK, R. D., MACKINNON, D. J. & SLAVIN, G. (1967). Bovine abortion: possible confusion of *Br. abortus* and 'Q' fever infections. Scientific letter. *Veterinary Record* **81**, 414.
- MEYER, M. (1966). Identification of *Brucella* organisms by immunofluorescence. *American Journal of Veterinary Research* **27**, 424.
- MOODY, M. D., BIEGELEISEN, J. Z. JR. & TAYLOR, G. C. (1961). Detection of brucellae and their antibodies by fluorescent antibody and agglutination tests. *Journal of Bacteriology* **81**, 990.
- MORRIS, C. J. O. R. (1964). Thin layer chromatography of proteins on Sephadex G-100 and G-200. *Journal of Chromatography* **16**, 167.
- MOULTON, J. E. & MEYER, M. E. (1958). The pathogenesis of *Brucella suis* infection in guinea pigs. Lesions of the spleen, liver, testis and articulations. *Cornell Veterinarian* **48**, 165.
- SCHWEIZER, R. (1964). Bang-oder Q-fever Abort. *Schweizer Archiv für Tierheilkunde* **106**, 213.
- THE, T. H. & FELTKAMP, T. E. W. (1970). Conjugation of fluorescein isothiocyanate to antibodies. 1. Experiments on the conditions of conjugation. *Immunology* **18**, 865.

## EXPLANATION OF PLATE

Fig. 1. Unstained smear of bovine placental cotyledon showing intense autofluorescence in ultra-violet light.  $\times 1250$ .

Fig. 2. Bovine placental smear stained with Evans Blue to suppress autofluorescence. The cytoplasm of the cells was stained red and the nuclei orange-red.  $\times 1250$ .

Fig. 3. Bovine placental smear infected with *Br. abortus*. This was stained with FITC-labelled antiserum to *Br. abortus* and counterstained with Evans Blue. The brucellas were visible at centre as an intracellular cluster of yellow-green fluorescent organisms (arrowed).  $\times 1250$ .

Fig. 4. Bovine placental smear infected with *Cox. burnetii* and stained as in Fig. 3. No fluorescent organisms were visible.  $\times 1250$ .

Fig. 5. Smear of bovine foetal stomach contents infected with *Br. abortus*. The organisms were visible as fluorescent yellow-green clumps of intracellular organisms (arrowed) and as extra-cellular individual organisms.  $\times 1250$ .