



## Electrocardiographic changes in hospitalised children with COVID-19

Gulhadiye Avcu<sup>1</sup> , Asli Arslan<sup>1</sup>, Zümrüt Sahbudak Bal<sup>1</sup> , Oguzhan Ay<sup>2</sup>, Erturk Levent<sup>2</sup>, Ferda Ozkinay<sup>1</sup> and Zafer Kurugol<sup>1</sup>

## Original Article

**Cite this article:** Avcu G, Arslan A, Bal ZS, Ay O, Levent E, Ozkinay F, and Kurugol Z (2023) Electrocardiographic changes in hospitalised children with COVID-19. *Cardiology in the Young* 33: 525–531. doi: [10.1017/S1047951123000100](https://doi.org/10.1017/S1047951123000100)

Received: 30 April 2022

Revised: 23 July 2022

Accepted: 8 January 2023

First published online: 23 January 2023

**Keywords:**

COVID-19; electrocardiography; atrioventricular conduction abnormalities; arrhythmia children

**Author for correspondence:**

G. Avcu, MD, Division of Pediatric Infectious Diseases, Department of Pediatrics, Faculty of Medicine, Ege University, 35100, Bornova, Izmir, Turkey. Tel: +902323903000. E-mail: [gul\\_akbas@yahoo.com.tr](mailto:gul_akbas@yahoo.com.tr)

<sup>1</sup>Division of Pediatric Infectious Diseases, Department of Pediatrics, Faculty of Medicine, Ege University, Izmir, Turkey and <sup>2</sup>Department of Pediatric Cardiology, Faculty of Medicine, Ege University, Izmir, Turkey

**Abstract**

**Objectives:** Cardiac manifestations of the coronavirus disease 2019 (COVID-19) have mainly been reported in adults. Therefore, we aimed to determine the electrocardiographic abnormalities in hospitalised paediatric patients with COVID-19 and multisystemic inflammatory syndrome in children. **Methods:** We retrospectively evaluated hospitalised paediatric patients <18 years of age with a diagnosis of COVID-19 (n = 168) and multisystemic inflammatory syndrome in children (n = 48) between March 2021 and December 2021. A daily electrocardiography was performed for the patients who had electrocardiographic abnormalities on admission or developed electrocardiographic abnormality on the follow-up. The characteristics of these patients, underlying predisposing conditions, and clinical course were also examined. **Results:** Two-hundred sixteen paediatric patients (55% were male) with a mean age of  $10.7 \pm 4.69$  years were evaluated. There was an underlying disease in 84 (38.8%) patients and 51 (23.6%) required paediatric ICU admission. Electrocardiography abnormality was detected in 12 (5.5%) which were as follows: 7 (3.2%) had sinus bradycardia, 3 (1.4%) patients had transient ST elevation and concomitant T negativity, and 2 (0.9%) developed first-degree Atrioventricular (AV) block. The median time from the onset of disease symptoms to detecting electrocardiographic abnormality was 9 days. Electrocardiographic abnormalities returned to normal uneventfully 3 days later. **Conclusions:** The prevalence of arrhythmia in paediatric patients with COVID-19 was detected in 5.5% of the patients. While two-thirds of the electrocardiography abnormalities were sinus bradycardia, ST elevation was remarkable (1.4%). Clinicians should be aware of electrocardiographic abnormalities and consider electrocardiographic monitoring in paediatric patients with COVID-19 and multisystemic inflammatory syndrome in children.

The disease caused by a novel coronavirus identified as severe acute respiratory coronavirus 2 (SARS-CoV-2) was named Coronavirus Disease 2019 (COVID-19). The disease quickly spread to hundreds of countries within a few months, becoming a pandemic in March 2020. In childhood, COVID-19 mainly showed mild clinical course, and severe disease can be seen in 2–6% of cases.<sup>1,2</sup> A hyperinflammatory syndrome characterised by fever longer than 24 hours, skin rashes, conjunctivitis, and multisystemic findings emerged from the United Kingdom and Italy in April 2020 and was named a multisystemic inflammatory syndrome in children.<sup>2,3</sup> Cardiac complications in children have been mainly reported among multisystemic inflammatory syndrome in children cases, such as coronary artery dilatation and aneurysms. However, several cardiac manifestations, including asymptomatic myocardial injury, myocarditis, and pericardial effusion, can be observed in COVID-19 patients.<sup>4</sup> Arrhythmias such as ST/T wave abnormalities, QTc prolongation, and atrioventricular block due to these cardiac changes have been reported mostly in adult studies.<sup>5</sup> However, data on paediatric COVID-19 patients with cardiac manifestation and electrocardiographic abnormalities are still scarce.<sup>6,7</sup> Therefore, we aimed to determine the electrocardiographic abnormalities in hospitalised children with COVID-19 and multisystemic inflammatory syndrome in children.

**Methods**

The study was conducted at the Pediatric Infectious Diseases Division of the Faculty of Medicine, Ege University, Turkey, between March 2021 and December 2021. Patients aged 0–18 years with the diagnosis of COVID-19 and multisystemic inflammatory syndrome in children were included. Patients with a positive result of SARS-CoV-2 PCR and showing symptoms attributable to COVID-19 were hospitalised in the Pediatric Infectious Diseases Department. Multisystemic inflammatory syndrome in children was defined according to criteria declared by the Central Diseases Center of the United States.<sup>8</sup>

The patients' medical records were collected retrospectively, and demographic characteristics (age, gender, comorbidities), clinical features, and laboratory findings were recorded. A daily

© The Author(s), 2023. Published by Cambridge University Press. This is an Open Access article, distributed under the terms of the Creative Commons Attribution licence (<http://creativecommons.org/licenses/by/4.0/>), which permits unrestricted re-use, distribution and reproduction, provided the original article is properly cited.

**Table 1.** Heart rate by age.

Age	Percentile 2nd (beats per minute)
0–3 months	<126
3–6 months	<116
6–12 months	<106
1–3 years	<97
3–5 years	<77
5–8 years	<64
8–12 years	<59
12–16 years	<53

electrocardiography was performed for the patients who had electrocardiographic abnormalities on admission or developed electrocardiographic abnormality on the follow-up.

The patients with electrocardiographic abnormalities were also evaluated in terms of length of hospital stay, paediatric ICU admission, the medical treatments given (steroid, intravenous immunoglobulin, antiviral therapy, anticoagulant therapy), and the levels of inflammatory markers (C-reactive protein, ferritin) and cardiac markers (troponin T and pro-brain-natriuretic peptide).

### Electrocardiography

Two different 12-lead standard electrocardiographic devices were used. Records were taken with the Philips ECG TC10 ECG device in the paediatric intensive care and emergency department and with the Cardiofax model 1250K ECG device in the paediatric infectious diseases department (Philips ECG TC10, Andover, MA, USA; Cardiofax GEM, Model 1250K; Nihon Kohden, Tokyo, Japan). Two different 12-lead standard electrocardiographic devices were performed with a speed of 25 mm/s and an amplitude of 10 mm/mV while the patients lay in supine. Electrocardiographics were read by a blind paediatric cardiologist. Paediatric cardiologists did not examine patients. Normal paediatric electrocardiographic parameters for age were used to determine heart rate and PR interval normal limits. Bradycardia was defined as a heart rate below the second percentile for age (Table 1). The first-degree Atrioventricular (AV) block on the electrocardiography was defined as PR interval >200 ms without associated disruption of atrial to ventricular conduction. ST-T segment normalised is the isoelectric line. In addition, elevation and depression of chest lead greater than 1 mV from the isoelectric line were considered as abnormal.<sup>9–11</sup>

### Microbiological methods

In a viral transport medium containing VNat, combined nasopharyngeal and oropharyngeal swab specimens were obtained (Bioeksen, Turkey). All samples were evaluated at our Molecular Virology Laboratory using the Bio-speedy® SARS CoV-2 Double Gene RT-qPCR (Bioeksen, Turkey). The Rotor-Gene was used to reverse transcription-polymerase chain reaction (Qiagen, Luxemburg). This assay amplifies and detects two viral targets (ORF1ab and N), with a detection limit of 200 genomes per mL. The human gene target RNase P (RP) was evaluated in each sample to employ an internal control. Results were considered positive if the signal was detected (Ct < 35) for RP, ORF1ab, and N genes.

Anti-spike immunoglobulin G (IgG) and IgM antibodies were detected in serum samples using rapid lateral flow immunoassay (Colloidal Gold-Hotgen, Germany).

### Statistical methods

Statistical analysis was performed with SPSS statistical package (version 25 for Windows). Data were expressed as either mean ± SD or percentages.

### Ethics

This research was approved by Ege University Clinical Research Ethics Committee on 16.12.2021 (Number: 21-12.1T/22).

### Results

A total of 216 paediatric patients hospitalised between March 2020 and December 2021 were included in the study. Of these, 168 (77.7%) were diagnosed with COVID-19 and 48 (22.2%) with multisystemic inflammatory syndrome in children, 98 (45%) were female and 118 (55%) were male. The mean age of the patients was 10.7 ± 4.69 years. There was an underlying disease in 84 (38.8%) of the hospitalised patients; neurometabolic disorders [n = 18, 8.2% (nine epilepsy and epileptic syndromes, three neurodegenerative disease, three organic acidemia, two glycogen storage disease, one mucopolysaccharidosis)], endocrinological pathologies [n = 14, 6.4% (11 obesity and 3 type 1 diabetes mellitus)], hemato-oncological malignancy [n = 11, 5% (five acute lymphoblastic leukaemia, three central nervous system tumour, one lymphoma, one neuroblastoma, one osteosarcoma)] were the most common comorbidities. It was remarkable that 5% of the patients were obese. Length of hospital stay-in median range was 6.1 days (1–22 days), and 51 (23.6%) patients had paediatric ICU admission. The variant analysis could not be performed in patients with positive SARS-CoV-2 PCR, but the delta variant was the most prevalent in Turkey from March to December of 2021. The demographic characteristics of the hospitalised patients are summarised in Table 2.

Electrocardiographic abnormality was detected in 12 (5.5%) hospitalised patients; 58.3% were male. Three (25%) were hospitalised for multisystemic inflammatory syndrome in children (with positive COVID-19 antibodies) and 9 (75%) for COVID-19 (with positive SARS-CoV-2 PCR). The mean age was 12.4 ± 3.4 years. Comorbidity was present in only 1 (obese) patient. While 5% (n = 11) of 216 patients in the study group were obese, sinus bradycardia developed as a result of severe COVID-19 pneumonia in only one of those with obesity. Length of hospital stay-in median range was 8.2 days (6–10 days). On admission, seven patients had respiratory symptoms such as cough, shortness of breath, and high-grade fever. Pneumonia findings were confirmed on thorax tomography imaging, favipiravir, antibiotherapy (ceftriaxone or ceftriaxone + vancomycin), low molecular weight heparin, and dexamethasone treatments were given. Intravenous immunoglobulin and high-dose methylprednisolone were given to three patients diagnosed with multisystemic inflammatory syndrome in children, and inotropic support was given to one patient. In addition, a patient diagnosed with myocarditis due to COVID-19 was given IVIG therapy. Eight (66.6%) patients had respiratory distress and seven (58.3%) patients had paediatric ICU admission. Bilevel positive airway pressure support was given to four patients following high-flow oxygen therapy. The length of stay-in median range at paediatric ICU was 2.6 days (2–7 days). The demographic

**Table 2.** Characteristics of the hospitalised patients.

Characteristics of the patients	n (%)
Age	10.7 ± 4.69
Gender	
Female	98 (45%)
Male	118 (55%)
Disease	168 (77.7%)
COVID-19	48 (22.2%)
MIS-C	84 (38.8%)
Comorbidities	
Neurometabolic disorders	18 (8.2%)
Endocrinological pathologies	14 (6.4%)
Hemato-oncological malignancy	11 (5%)
Cardiovascular disease	10 (4.6%)
Chronic pulmonary disease	10 (4.6%)
Bone marrow/solid organ transplantation	8 (3.7%)
Primary immune deficiency	7 (3.2%)
Others	6 (2.7%)
Length of hospital stay (day)–median (range)	6.1 (1–22)
PICU admission	51 (23.6%)
ECG abnormality	12 (5.5%)

COVID-19 = coronavirus disease 2019; ECG = electrocardiography; MIS-C = multisystem inflammatory syndrome; PICU = paediatric ICU.

characteristics and laboratory findings of the patients with electrocardiographic abnormality are summarised in Tables 3 and 4.

Electrocardiographic abnormalities were as follows: 2 (0.9%) patients developed first-degree AV block, 3 (1.4%) patients had transient ST elevation and concomitant T negativity, and the other 7 (3.2%) had sinus bradycardia. None of the patients received anti-arrhythmic medications such as  $\beta$ -blockers and calcium channel blockers. Electrocardiographic abnormality was experienced in the second week of the disease in most patients ( $n = 10$ , 83.3%); the median time from the onset of disease symptoms to the detection of electrocardiographic abnormality was 9 days (range: 4–12 days). The median time to detection after admission and steroid therapy was 4 days (3–7 days). The patients did not undergo 24-hour Holter recording during the hospital stay, but daily electrocardiography was recorded for the patients who had electrocardiographic abnormality on admission or developed electrocardiographic abnormality on the follow-up. Patients who developed bradycardia were continuously monitored with bedside monitors. Although very low cardiac pulse values were recorded (even deeper while asleep), the patients did not suffer from haemodynamic deterioration. The electrocardiographic abnormality returned to normal without any medication or pacing on the third day after the initial abnormalities in all patients except one patient whose sinus bradycardia lasted 4 days. Most of the patients ( $n = 10$ ) did not develop any symptoms due to the severe course of the disease, close monitoring of their vitals allowed these electrocardiographic changes to be noticed. Except for arrhythmias occurring during hospital follow-up, there were two patients with electrocardiographic abnormality and SARS-CoV2 PCR positivity at admission; one of them presented with syncope, first-degree AV

**Table 3.** Characteristics of the patients with ECG abnormalities.

Patients, n	12
Age, years, (mean±SD)	12.4 ± 3.4
Gender, male, n (%)	7 (58.3%)
Length of hospital stay(day)–in median (range)	8.2 (6–10)
Paediatric ICU admission n (%)	7 (58.3%)
COVID-19 laboratory testing	
SARS-CoV-2 PCR positive	9 (75%)
SARS-CoV-2 PCR negative, serology positive	3 (25%)
ECG abnormality	
Sinus bradycardia	7 (3.2%)
Transient ST elevation, T negativity	3 (1.4%)
First-degree AV block	2 (0.9%)
Laboratory findings	
WBC (mean ± SD)/mm <sup>3</sup>	8926 ± 7129
ANC (mean ± SD)/mm <sup>3</sup>	6438 ± 7089
ALC (mean ± SD)/mm <sup>3</sup>	1681 ± 2335
Hb (mean ± SD), g/dL	12.3 ± 1.54
PLT (mean ± SD)/mm <sup>3</sup>	247,700 ± 105,430
CRP (mean ± SD), mg/L	97.3 ± 113.9
PCT (mean ± SD), µg/L	1.38 ± 1.65
D-dimer (mean ± SD), µg/L	1509 ± 1162
Fibrinogen (mean ± SD), mg/dl	531.4 ± 180.4
Troponin. (mean ± SD), ng/L	32 ± 57
NT-pro-BNP (mean ± SD),ng/L	2601 ± 6050

ALC = absolute lymphocyte count; ANC = absolute neutrophil count; CRP = C-reactive protein; ECG = electrocardiography; Hb = hemoglobin; NT-pro-BNP = N-terminal-pro-brain natriuretic peptide; PCT = procalcitonin; PLT = platelet count; WBC = white blood cell.

block was detected, and the other presented with chest pain and fever, ST elevation was seen, and diagnosed as myocarditis due to COVID-19 (electrocardiographic findings are shown in Figs 1 and 2).

Although it was observed that the detection of sinus bradycardia and first-degree AV block did not have a significant effect on patient management, it was important to detect ST changes, which can be considered as an indicator of myocardial injury, in 1.4% (3/216) patients, because in this way, the examinations and treatments (IVIg, steroid) of the patients were expanded and longer follow-up was planned. Also it has been shown in our data that COVID-19 can cause substantial myocarditis (1 of 216 cases; approximately 0.5%) in childhood and may present with significant electrocardiographic abnormalities.

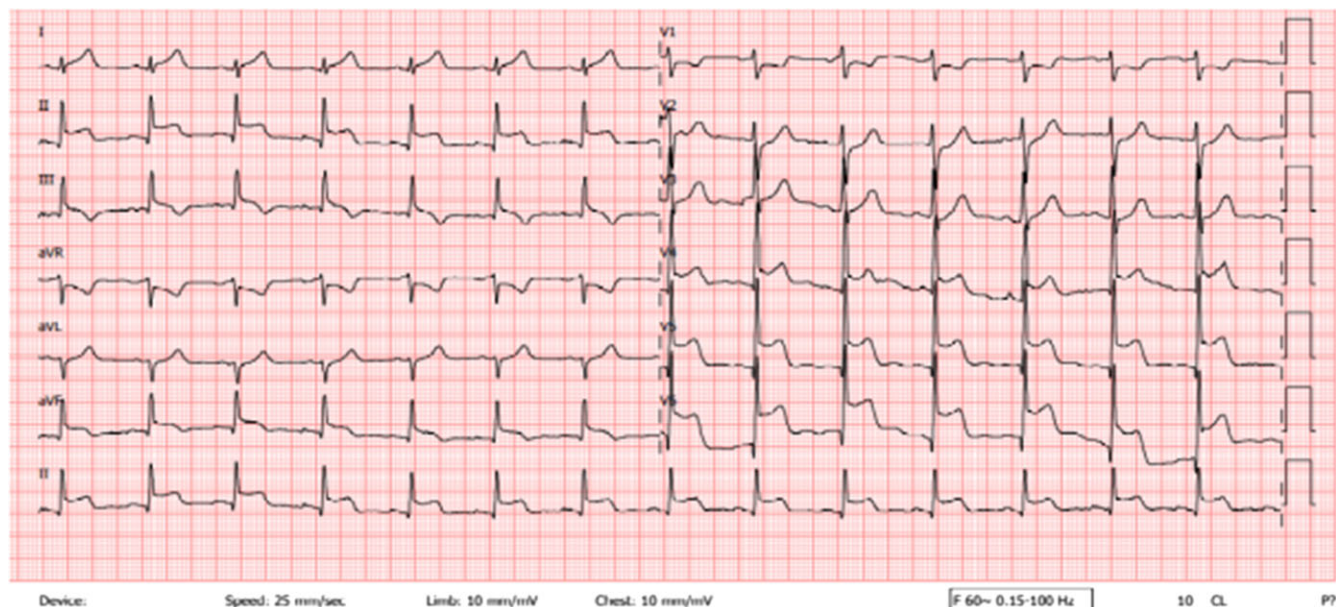
In laboratory tests, there was a significant increase in cardiac markers troponin T and pro-BNP in multisystemic inflammatory syndrome in children patients and one patient with myocarditis. At the same time, no elevation was found in other COVID-19 patients.

In echocardiographic evaluation, pathology was detected only in patients with multisystemic inflammatory syndrome in children; one of the patients had mild mitral regurgitation, one had pericardial effusion, and the other one had low ejection fraction (35–40%), which completely regressed in follow-up. No pathology

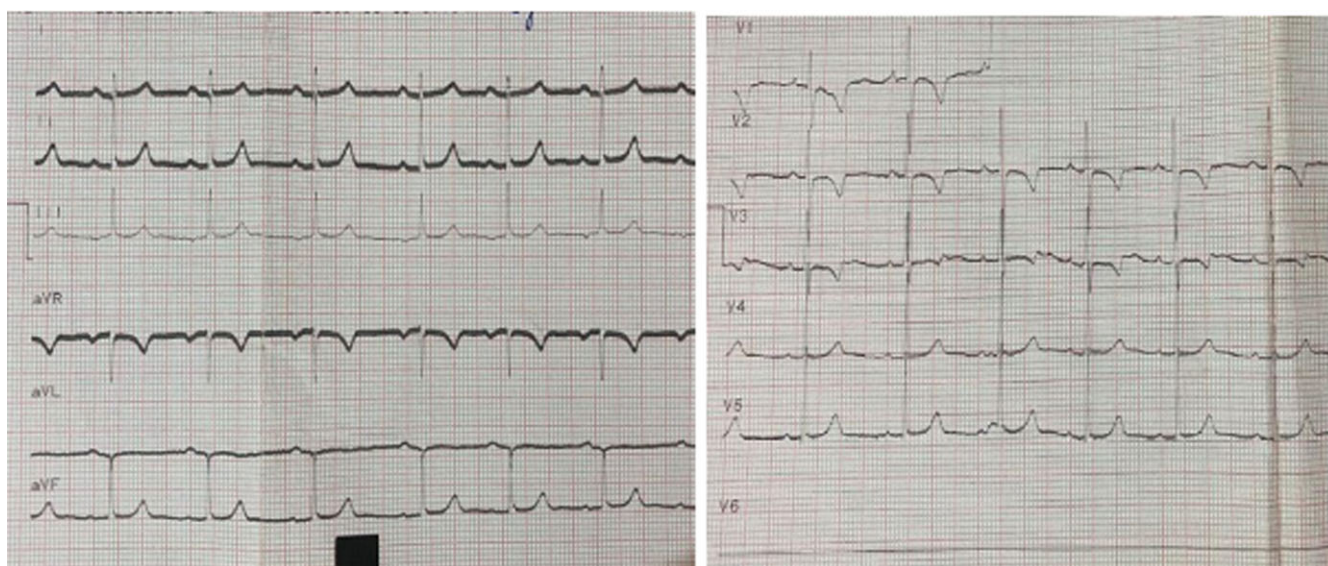
**Table 4.** Summary of patients with ECG abnormalities.

Patient	Symptoms on admission	Disease	PICU admission	Inotropic support	Respiratory support	Antibiotic therapy	Antiviral therapy	Steroid therapy	IVIG therapy	Radiology	Elevated cardiac markers	ECG	Echocardiography
1	Fever, shortness of breath	COVID-19	Yes	No	HFNO	Ceftriaxone	Favipiravir	Dexamethasone 6 mg/gün iv	No	Bilateral pneumonia	no	sinus bradycardia	No abnormality
2	Fever, abdominal pain, diarrhoea, shortness of breath	MIS-C	Yes	Yes	BIPAP	Ceftriaxone	No	Pulse methylprednisolone	2 g/kg	Normal chest X-ray	Yes	Sinüs bradycardia	Mild mitral regurgitation
3	Fever, cough	COVID-19	No	No	No, only O <sub>2</sub> support with nasal cannula	Ceftriaxone	Favipiravir	Dexamethasone 6 mg/daily iv	No	Bilateral pneumonia	No	First degree AV block	No abnormality
4	Fever, shortness of breath	COVID-19	Yes	No	HFNO	Ceftriaxone	Favipiravir	Dexamethasone 6 mg/daily iv	No	Bilateral pneumonia	No	Sinüs bradycardia	No abnormality
5	Fever, cough, shortness of breath	COVID-19	Yes	No	HFNO	Ceftriaxone	Favipiravir	Dexamethasone 6 mg/daily iv	No	Bilateral pneumonia	No	Sinüs bradycardia	No abnormality
6	Fever, cough, shortness of breath	COVID-19	No	No	HFNO	Ceftriaxone	Favipiravir	Dexamethasone 6 mg/daily iv	No	Bilateral pneumonia	No	Sinüs bradycardia	No abnormality
7	Fever, cough, shortness of breath	COVID-19	Yes	Yes	BIPAP	Ceftriaxone	Favipiravir	Dexamethasone 6 mg/daily iv	No	Bilateral pneumonia	No	Sinüs bradycardia	No abnormality
8	Fever, cough, shortness of breath	COVID-19	No	No	Nasal O <sub>2</sub> requirement	Ceftriaxone	Favipiravir	Dexamethasone 6 mg/daily iv	No	Bilateral pneumonia	No	ST- elevation, T negativity	No abnormality
9	Fever, sore throat, cough, swelling in the neck, shortness of breath	MIS-C	Yes	No	BIPAP	Ceftriaxone	No	Methylprednisolone 2 mg/kg/daily iv	2 g/kg	Bilateral pleural effusion	Yes	ST-elevation	Low ejection fraction (35-40%)
10	Fever, vomiting, abdominal pain, rash	MIS-C	Yes	No	Nasal O <sub>2</sub> requirement	Ceftriaxone+ vancomycin	No	Methylprednisolone 2 mg/kg/daily iv	2 g/kg	Pulmonary oedema	Yes	Sinüs bradycardia	Minimal pericardial effusion
11	Chest pain, fever	COVID-19/ myocarditis	No	No	No	No	No	No	1 g/kg	Normal	Yes	ST-elevation	No abnormality
12	Syncope	COVID-19	No	No	No	No	No	No	No	Normal	No	First-degree AV block	No abnormality





**Figure 1.** Electrocardiography demonstrating ST elevation in a 15-year-old male patient (patient 11) with myocarditis.



**Figure 2.** Electrocardiography demonstrating first-degree AV block in a 7-year-old female patient (patient 12) with syncope.

was detected in other patients. All patients recovered; no deaths from SARS-CoV-2 infection nor multisystemic inflammatory syndrome in children were recorded.

### Discussion

In our single-centre experience, we detected an electrocardiographic change in 5.5% of the hospitalised paediatric patients with COVID-19. Sinus bradycardia accounted for more than half of the electrocardiographic abnormalities, followed by transient ST elevation-T negativity and first-degree AV block. Only three of the patients were multisystemic inflammatory syndrome in children patients from whom we expected cardiac involvement, but the others were COVID-19-related conditions. While multisystemic inflammatory syndrome in children data are found more

frequently, and there are many adult studies of arrhythmias in COVID-19 patients in the literature, the number of studies examining electrocardiographic changes in paediatric patients with COVID-19 is very few.

Among cardiovascular manifestations associated with COVID-19, various articles have reported arrhythmias in adults, but there have been past arrhythmic history or significant comorbidities in most cases.<sup>12,13</sup> A study involving adult patients diagnosed with COVID-19 detected a new arrhythmia attack in 9% of hospitalised patients. Atrial fibrillation and atrial tachycardia were the most common arrhythmias.<sup>14</sup> The patients were clinically stable, older and had longer in-hospital stays. Ventricular arrhythmias have also been reported as the first clinical manifestation of COVID-19. In the adult literature, AV block was noticed in the acute phase of the hospitalisation, and most were considered

due to hypoxia or electrolyte imbalance.<sup>15</sup> However, the cause and mechanism of arrhythmia in children have not been fully elucidated.<sup>16</sup>

The short- and long-term effects of new-onset bradyarrhythmias in patients with COVID-19 are unknown. A series of seven patients with COVID-19 and severe bradyarrhythmias requiring pacemakers was reported in adults.<sup>17</sup> Amir et al. reported a case series of six paediatric patients with symptomatic bradycardia in COVID-19.<sup>18</sup> As in our study, all of them were hospitalised for respiratory disease and needed oxygen support. The myocardial lesion was excluded with normal cardiac markers and echocardiogram. Half of the patients with persistent complete AV block or sinus bradycardia underwent permanent pacemaker implantation due to symptomatic (syncope, haemodynamic instability) clinical course. Our patients did not develop haemodynamic instability, and their self-limiting condition did not require additional medication or intervention during the follow-up.

Various theories have been proposed on the mechanism of cardiac involvement during COVID-19. During acute illness, bradycardia may develop due to invasion of myocardial tissue by SARS-CoV-2, hypotension, hypoxia due to pulmonary damage or inflammatory system activation, and collateral damage due to cytokine storm.<sup>19</sup> ACE2 overexpression in sino-atrial node cells has also been associated with conduction abnormalities.<sup>20,21</sup> In our study, COVID-19-related myocarditis was the cause of transient ST elevation in one patient. It was thought that moderate pneumonia and hypoxia, which required severe respiratory support and oxygen, could be the causative factors in seven patients.

Arrhythmic manifestations are described in 7–60% of patients with multisystemic inflammatory syndrome in children with different presentation patterns.<sup>22</sup> The most frequently reported electrocardiographic anomalies were non-specific and included ventricular repolarization abnormality, QTc prolongation, and premature atrial or ventricular beats. In a study examining multisystemic inflammatory syndrome in children and cardiac conduction abnormalities, 32 patients were included, and first-degree AV block was detected in 6 (19%) patients. Cardiac enzymes, inflammatory markers, and cardiac function were not associated with AV block. The onset of first-degree AV block occurred at a median of 8 days after the initial onset of symptoms and resolved after 3 days in the follow-up.<sup>23</sup> The mechanism of myocardial dysfunction in multisystemic inflammatory syndrome in children has not been cleared, and probably several pathophysiological mechanisms may play a role. Possible causes include acute myocarditis, post-viral immunological reaction, and systemic inflammatory response syndrome.<sup>24</sup> Choi et al.<sup>23</sup> emphasised that hyperinflammation and myocardial damage may be responsible for conduction defects in multisystemic inflammatory syndrome in children patients and that early immunosuppressive therapy (steroid and IVIG) also leads to conduction anomalies.

Some medications may also contribute to the development of arrhythmias. In COVID-19, paediatric cases with QT prolongation due to the combined use of hydroxychloroquine and azithromycin and paediatric cases with sinus bradycardia due to remdesivir use draw attention in the literature.<sup>25,26</sup> Remdesivir was approved for severe COVID-19 in adults and patients 12 years of age and older as of October 2020 and was recently approved for all children beyond 28 days of age.<sup>27,28</sup> Besides the expected side effects of remdesivir, cardiovascular effects are also frequently mentioned due to increased use. Asymptomatic sinus bradycardia and QT interval prolongation, which develops during treatment and disappears when treatment is discontinued, are also reported in

paediatric and adult cases.<sup>23,29</sup> Remdesivir-associated mitochondrial dysfunction causing cardiotoxicity and the structural relationship of remdesivir with adenosine which can cause AV block is proposed to be potential mechanism.<sup>30</sup> None of our patients had a history of antiarrhythmic use, and none of them received azithromycin-hydroxychloroquine or remdesivir treatment. The literature reported bradycardia as a side effect of dexamethasone and other steroid therapies in some populations like oncological patients and Kawasaki disease.<sup>31,32</sup> Steroid-induced decrease in the sensitivity of myocardial alpha-adrenergic and beta-adrenergic receptors, leading to a reduction in heart rate and mineralocorticoid activity causing hypertension and reflex bradycardia, are predicted as potential mechanisms. In our study, all of our patients who developed sinus bradycardia were treated with steroids, dexamethasone for those with COVID pneumonia, and low dose (2 mg/kg) or pulse-methylprednisolone for those with multisystemic inflammatory syndrome in children.

In conclusion, bradyarrhythmias and various electrocardiographic abnormalities may occur as a part of the clinical course in paediatric patients with COVID-19, not only in multisystemic inflammatory syndrome in children patients. Moderate to severe pneumonia-induced hypoxia, steroid therapy, and direct cardiac effects of SARS-CoV-2 may be potential causes of arrhythmias detected in our patients in the second week of the disease. Although these arrhythmias seem to have a benign course and most electrocardiographic abnormalities (sinus bradycardia, first-degree AV block) do not have a prominent effect on patient management, the reports of many patients requiring pacemakers and the scarce paediatric data raise doubts. It should also be kept in mind that significant electrocardiographic findings (ST-T abnormalities) may develop which changes the management of the patients considerably and electrocardiographic monitoring should be considered in these patients. Further prospective studies are needed to reveal the cardiac findings, arrhythmias, the underlying mechanism, and the short- and long-term effects of COVID-19 in the paediatric population.

**Acknowledgements.** None.

**Financial support.** This research received no specific grant from any funding agency, commercial, or not-for-profit sectors.

**Conflicts of interest.** None.

## References

1. Dong Y, Mo X, Hu Y, et al. Epidemiology of COVID-19 among children in China. *Pediatrics* 2020; 145: e20200702.
2. Centers for Disease Control and Prevention. Multisystem inflammatory syndrome in children (MIS-C) associated with coronavirus disease 2019 (COVID-19), 2020. Retrieved May 19, 2020, from <https://emergency.cdc.gov/han/2020/han00432.asp>
3. Verdoni L, Mazza A, Gervasoni A, et al. An outbreak of severe Kawasaki-like disease at the Italian epicentre of the SARS-CoV-2 epidemic: an observational cohort study. *Lancet* 2020; 395: 1771–1778.
4. Clerkin KJ, Fried JA, Raikhelkar J, et al. COVID-19 and cardiovascular disease. *Circulation* 2020; 141: 1648–1655.
5. Mohammad M, Emin M, Bhutta A, Gul EH, Voorhees E, Afzal MR. Cardiac arrhythmias associated with COVID-19 infection: state of the art review. *Expert Rev Cardiovasc Ther* 2021; 19: 881–889. DOI [10.1080/14779072.2021.1997589](https://doi.org/10.1080/14779072.2021.1997589).
6. Azevedo RB, Botelho BG, Hollanda JVG, et al. Covid-19 and the cardiovascular system: a comprehensive review. *J Hum Hypertens* 2021; 35: 4–11.



7. Sisko SG, Atik SU, Karadeniz C, Guzeltas A, Ergul Y. Complete heart block, severe right ventricular dysfunction in a child with COVID-19 infection. *Cardiol Young* 2021; 4: 1–3.
8. CDC Health Alert Network. Multisystem inflammatory syndrome in children (MIS-C) associated with coronavirus disease 2019 (COVID-19). Retrieved October 22, 2020, from <https://emergency.cdc.gov/han/2020/han00432.asp>
9. Park MK. *Pediatric Cardiology for Practitioners* E-Book. Elsevier Health Sciences, Philadelphia, PA, 2014: 41–66.
10. Fleming S, Thompson M, Stevens R, et al. Normal ranges of heart rate and respiratory rate in children from birth to 18 years of age: a systematic review of observational studies. *Lancet* 2011; 377: 1011–1018.
11. Saarel EV, Granger S, Kaltman JR, et al. Electrocardiograms in healthy North American children in the digital age. *Circ Arrhythm Electrophysiol* 2018; 11: e005808.
12. Guo T, Fan Y, Chen M, et al. Cardiovascular implications of fatal outcomes of patients with coronavirus disease 2019 (COVID-19). *JAMA Cardiol* 2020; 5: 811–818 11.
13. Ruan Q, Yang K, Wang W, Jiang L, Song J. Clinical predictors of mortality due to COVID-19 based on an analysis of data of 150 patients from Wuhan, China. *Intensive Care Med* 2020; 46: 846–848. Published correction appears in *Intensive Care Med* 2020; 46: 1294–1297.
14. Sala S, Peretto G, De Luca G, et al. Low prevalence of arrhythmias in clinically stable COVID-19 patients. *Pacing Clin Electrophysiol* 2020; 43: 891–893.
15. Siripanthong B, Nazarian S, Muser D, et al. Recognizing COVID-19-related myocarditis: the possible pathophysiology and proposed guideline for diagnosis and management. *Heart Rhythm* 2020; 17: 1463–1471.
16. American College of Cardiology Foundation Task Force on Expert Consensus Documents, Hundley WG, Bluemke DA. ACCF/ACR/AHA/NASCI/SCMR 2010 expert consensus document on cardiovascular magnetic resonance: a report of the American College of Cardiology Foundation Task Force on Expert Consensus Documents. *J Am Coll Cardiol* 2010; 55: 2614–2662.
17. Chinitz JS, Goyal R, Harding M, et al. Bradyarrhythmias in patients with COVID-19: Marker of poor prognosis? *Pacing Clin Electrophysiol* 2020; 43: 1199–1204.
18. Amir M, Yoseph H, Farisi ATA, Phie JKP, Adam ATS. Symptomatic bradycardia in Covid-19 hospitalized patients: a case series. *Int J Infect Dis* 2021; 111: 1–4.
19. Kochi A, Cagliari AP, Forelo B, Fassini GM, Tondo C. Cardiac and arrhythmic complications in patients with COVID-19. *J Cardiovasc Electrophysiol* 2020; 21: 1003–1008.
20. Ferreira AJ, Moraes PL, Foureaux G, Andrade AB, Santos RA, Almeida AP. The angiotensin-(1-7)/Mas receptor axis is expressed in sinoatrial node cells of rats. *J Histochem Cytochem* 2011; 59: 761–8 10.
21. Danilczyk U, Penninger JM. Angiotensin-converting enzyme II in the heart and the kidney. *Circ Res* 2006; 98: 463–471.
22. Sperotto F, Friedman KG, Son MBF, VanderPluym CJ, Newburger JW, Dionne A. Cardiac manifestations in SARS-CoV-2-associated multisystem inflammatory syndrome in children: a comprehensive review and proposed clinical approach. *Eur J Pediatr* 2021; 180: 307–322.
23. Choi NH, Fremed M, Starc T, et al. MIS-C and cardiac conduction abnormalities. *Pediatrics* 2020; 146: e2020009738.
24. Ciccarelli GP, Bruzzese E, Aisle G, et al. Bradycardia associated with multi-system inflammatory syndrome in children with COVID-19: a case series. *Eur Heart J Case Rep* 2021; 5: ytab405. DOI [10.1093/ehjcr/ytab405](https://doi.org/10.1093/ehjcr/ytab405).
25. Chow EJ, Maust B, Kazmier KM, Stokes C. Sinus bradycardia in a pediatric patient treated with remdesivir for acute coronavirus disease 2019: a case report and a review of the literature. *J Pediatric Infect Dis Soc* 2021; 10: 926–929.
26. Barkas F, Style CP, Bechlioulis A, Milonias H, Liberopoulos E. Sinus bradycardia associated with remdesivir treatment in COVID-19: a case report and literature review. *J Cardiovasc Dev Dis* 2021; 8: 18.
27. US Food and Drug Administration (FDA). Frequently asked questions on the Emergency Use Authorization for Veklury® (remdesivir) for hospitalized COVID-19 patients, October 22, 2020. Retrieved October 27, 2020, from <https://www.fda.gov/media/137574/download>
28. US Food and Drug Administration (FDA) approves the first COVID-19 treatment for young children. The latest Updates and Resources on Novel Coronavirus (COVID-19). <https://www.aha.org/news/news/2022-04-25-fda-approves-first-covid-19-treatment-youngchildren#:~:text=The%20Food%20and%20Drug%20Administration,progressing%20to%20severe%20COVID%2D19>
29. Gubitosa JC, Kakar P, Gerula C, et al. Marked sinus bradycardia associated with remdesivir in COVID-19: a case and literature review. *JACC Case Rep* 2020; 2: 2260–2264.
30. Paw Cho Sing E, Schechter T, Ali M, Sung L, Dupuis LL. Safety of dexamethasone for nausea and vomiting prophylaxis in children receiving hematopoietic stem cell transplantation. *J Pediatr Hematol Oncol* 2018; 40: e278–e282.
31. Üsküdar Cansu D, Bodakçi E, Korkmaz C. Dose-Dependent bradycardia as a rare side effect of corticosteroids: a case report and review of the literature. *Rheumatol Int* 2018; 38: 2337–2343.
32. Nagakura A, Morikawa Y, Sakakibara H, Miura M. Bradycardia associated with prednisolone in children with severe Kawasaki disease. *J Pediatr* 2017; 185: 106–111.