

LETTER TO THE EDITOR**TO THE EDITOR****Adult-Onset Anti-N-methyl-D-aspartate-receptor Encephalitis Presenting as a Non-Fluent Aphasia**

Keywords: Anti-NMDA-receptor encephalitis, Non-fluent aphasia, Frontal, Operculum

In the late 1990s and early 2000s, cases were described of previously healthy young women who presented with a benign ovarian teratoma and subacute limbic encephalitis, which reversed at least partially following teratoma resection and immunosuppression.¹ In 2007, Dalmau et al.² coined the term “anti-N-methyl-D-aspartate-receptor (NMDAR) encephalitis” after discovering that these patients had antibodies against the NMDAR. Most patients initially present with a non-specific prodrome of headaches, fever, nausea, and psychiatric symptoms. Many also develop short-term memory impairment, seizures, and movement disorders, often progressing to decreased level of consciousness and autonomic instability requiring intensive care unit admission.²⁻⁴ Poor outcome, usually defined as

a modified Rankin Scale of 3-5, occurs in ~10% of patients and death in another 10%. Early identification and treatment of the disorder is thought to be of prime importance in improving outcomes.^{4,5} Aphasia as a sign of anti-NMDAR encephalitis has been poorly characterized and is neither typically thought to be a localizing sign nor a presenting feature of this disorder. We describe a case of anti-NMDAR encephalitis that presented as a progressive non-fluent aphasia.

A 29-year-old English-speaking female with no significant past medical history reported a 6-day history of progressive word-finding difficulties followed by a 3-day history of multiple stereotypic episodes. The latter episodes lasted a few minutes each and were characterized by a prodrome of metallic taste, and a “scratching” sensation in her teeth, which then evolved into right-sided facial twitching, right hand cramping, and right face and arm paresthesiae without loss of consciousness, presumably representing simple partial seizures. She was brought to the emergency department following a first witnessed generalized tonic-clonic seizure.

Initial neurological examination revealed agrammatic non-fluent speech and writing (see Figure 1A). She could name only

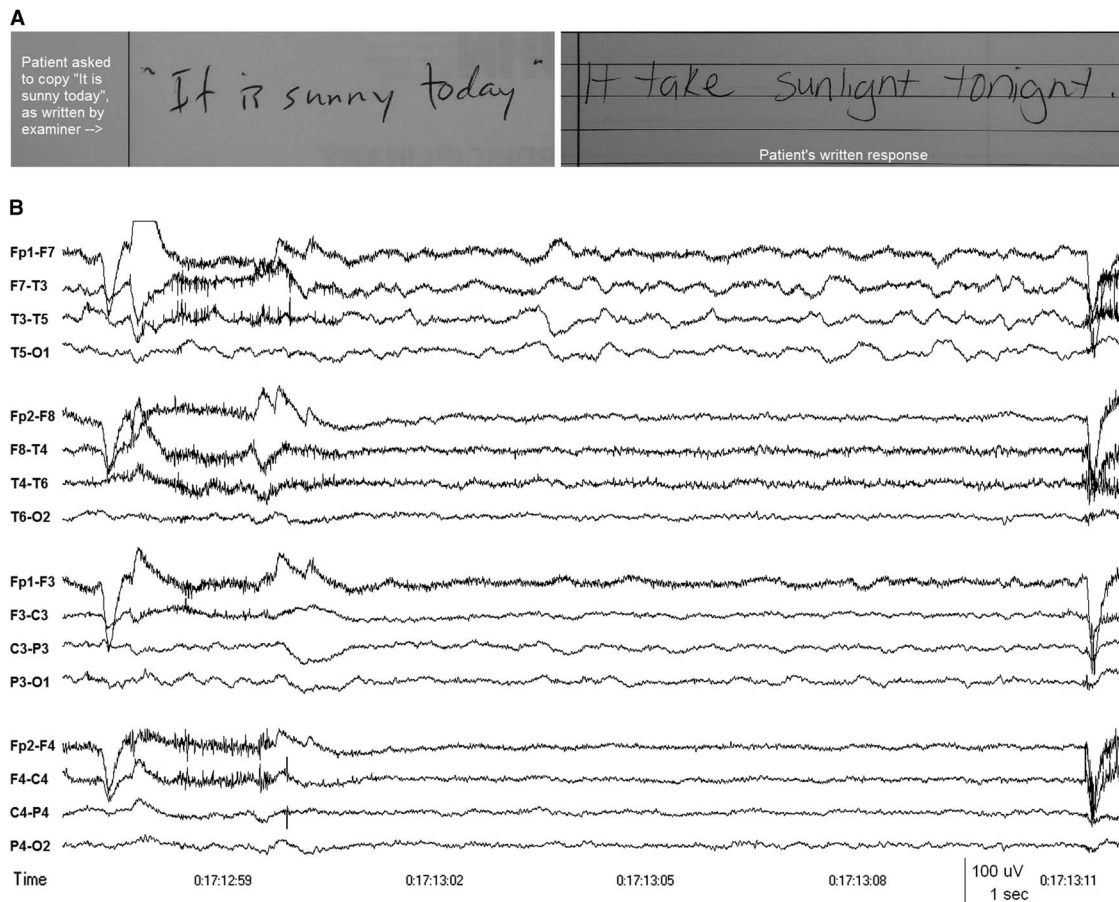


Figure 1: (A) Patient's attempt to copy the written phrase “It is sunny today,” demonstrating multiple phonemic paraphasic errors. (B) EEG showing intermittent slow wave activity in the delta and theta frequency bands over the left frontotemporal region (maximal at T3 or F7-T3), indicating dysfunction affecting the left mid temporal and anterior Sylvian regions. Patient's eyes were open at the time and she was attempting to write a response to a question, having just been unable to answer the questions verbally. Anterior-posterior longitudinal bipolar montage. Time constant 0.3 sec. High frequency filter 70 Hz.

Table 1: Reported cases of anti-N-methyl-D-aspartate receptor encephalitis associated with aphasia

Study	Study type	N	Median age (years) (range)	Presenting symptoms (n)	Language as presenting symptom (n (%))	Proportion developing aphasia at some point (n (%))	Delay from onset to aphasia (days)	Description of language difficulties
Florance et al. ⁷	Retrospective case series	32	14 (2–18)	Fever, headache, URTI symptoms, vomiting, and/or diarrhoea (15) Mood, behaviour, or personality changes (28) Seizures (6)	1 (3)	17 (53)	Not specified	“[...] reduction of verbal output or mutism, mumbling, or perseveration”
Dalmau et al. ³	Retrospective case series	100	23 (5–76)	Headaches, low-grade fevers, non-specific viral like illness (86) Psychiatric symptoms (77) Short-term memory loss or seizures (23)	0 (0)	6 (6)	Within 21 days of symptom onset	“Some patients mumbled unintelligible words or had echolalia” “Transient aphasia”
Titulaer et al. ⁵	Observational cohort study	31	>45 (45–85)	Behaviour change (18) Speech (2) Seizures (4) Cognition (2) Memory loss (5)	2 (6.5)	19 (61.3)	0–30	“Speech disturbance”
Kumaran et al. ⁸	Case report	1	4	Right partial motor seizures and fever	0 (0)	1 (100)	8	“[...] Receptive language preserved but [...] expressive language was affected associated with anomia, and anarthria suggestive of Broca’s aphasia”
Vahter et al. ⁶	Case report	1	29	Generalized tonic-clonic seizure	0 (0)	1 (100)	30	“Sensorimotor aphasia”
Wang et al. ⁴	Retrospective case study	51	21.6 (9–39)	Psychiatric (32) Seizures (14) Memory deficits (1) Speech disturbances (2) Headaches (1) Ataxia (1)	2 (3.9)	23 (45)	0–21	“Speech disturbances”
Leon-Salas et al. ⁹	Case report	1	17	Headache, anxiety, sleep changes followed by two left arm focal motor seizures Back to normal 5 days later 19 months later, presents anew with headache, nausea, and vomiting, followed by speech difficulties 15 days later	0 (0)	1 (100)	570	“[...] expressive language disturbances, including reduced non-fluent spontaneous speech, altered repetition and nomination with phonemic paraphasias, as in motor aphasia “In naming tests, she exhibited anomia and paraphasic errors. Spontaneous speech (narrative) was severely reduced and agrammatical, and she replied only in monosyllables and isolated words. However, tone, inflection, and rhythm (prosody) were preserved. In addition, language comprehension was severely disturbed, as she was only able to follow instructions consisting of one or two elements. Alexia and agraphia were also present”

URTI = upper respiratory tract infection.

one of the six objects on the National Institutes of Health (NIH) stroke scale. She had no spontaneous speech and could only provide single-word answers. She made frequent phonemic paraphasic errors (e.g., “tea” for “key”), demonstrated apraxia of speech, articulatory groping, and impaired sentence repetition. She was unable to read any of the NIH stroke scale sentences. She could obey commands, including “take this paper in your hands and fold it in half and put it on the bed”. There was no obvious ideomotor apraxia as she could use her smartphone. The rest of the neurological examination was normal.

CT angiogram of the head and MRI of the brain with gadolinium obtained at presentation were normal. CSF analysis was within normal limits (two white blood cells $\times 10^6/L$, 95% lymphocytes, protein 0.20 g/L, glucose 3.7 mmol/L) with normal cytology. Electroencephalography (EEG) showed abundant intermittent polymorphic slow wave activity over the left lateral frontotemporal area (see Figure 1B). She was started on acyclovir initially, which was discontinued after a negative CSF Polymerase Chain Reaction for herpes simplex virus, varicella-zoster virus, human herpesvirus-6, cytomegalovirus, and Epstein-Barr virus. Her generalized and partial seizures were controlled with levetiracetam and carbamazepine, and no seizures were recorded during 48 hours of continuous video-EEG obtained 5 days after presentation to the hospital. Fluctuating sensory symptoms of right-sided numbness (leg more than arm) and a sensation of something “cutting” her were not associated with EEG changes apart from the left frontotemporal slow wave activity. There was no EEG evidence of the extreme delta brush pattern and no definite interictal epileptiform activity was recorded. Her aphasia progressed with increasing phonemic errors and agrammatism to eventual mutism 22 days after symptom onset, by which time she could obey only simple one-step commands. By then, she had also developed prolonged periods of confusion and emotional lability.

Her CSF anti-NMDAR NR-1 antibody (Cell-based assay; Mitogen Advanced Diagnostic Laboratory, Calgary, Alberta, Canada) was positive and an MRI of her abdomen revealed a 5.3 cm right adnexal cystic teratoma (confirmed on pathology). She underwent a right oophorectomy 19 days after symptom onset without appreciable clinical improvement postoperatively. Thirty days after symptom onset, she received a 2-day course of 2 mg/kg of intravenous immunoglobulin and there was subsequent gradual improvement of her aphasia. Sixty-three days after symptom onset, she was discharged to a neurocognitive rehabilitation facility on carbamazepine and clobazam. At that time, she could produce short sentences such as “it’s good to see you”, but was still making frequent phonemic errors. Her comprehension was intact.

One hundred and twenty days after symptom onset, she had a normal routine EEG and she was successfully tapered off her anti-epileptic medications. Ten months after symptom onset, formal neurocognitive assessment showed complete resolution of her language impairments, but she did have impaired recollection of the events surrounding her hospitalization.

To our knowledge, this is the first detailed description of adult-onset anti-NMDAR encephalitis presenting primarily as a progressive non-fluent aphasia affecting left frontal and opercular structures. Lesser associated sensory disturbances and focal seizures without loss of awareness (before admission and commencement of antiepileptic medication) were also compatible with a localization to the left opercular region, and EEG provided

neurophysiological evidence of dysfunction restricted to the same left frontotemporal area.

A review of the literature revealed only four cases of adult anti-NMDAR encephalitis possibly presenting with aphasia, but described only as “speech disturbance”. Neither a detailed description nor a timeline of symptom progression were provided for those cases, and it is uncertain whether the speech disturbance presented in isolation or with other symptoms.^{4,5} Aphasia has been more commonly described as a symptom that evolves following an initial presentation with psychiatric symptoms or seizure, rather than as the main presenting symptom. Dalmau et al.³ found that 6% of patients with anti-NMDAR encephalitis developed “mumbled unintelligible words”, “echolalia”, or “transient aphasia” within 3 weeks of symptom onset. Vahter et al.⁶ described a case of anti-NMDAR encephalitis that developed “sensorimotor aphasia” approximately 1 month after initial presentation with generalized tonic-clonic seizure. In the paediatric literature, Florance et al.⁷ reported that, in a case series of 32 children with a median age of 14 years, 17 (53%) developed “reduction of verbal output or mutism, mumbling, or perseveration”, but this was the presenting symptom in only one case. Deiva et al.⁸ reported on a 4-year-old female who presented with right partial motor seizures and fever and developed Broca’s aphasia 8 days after symptom onset. Recently, Leon-Salas et al.⁹ described a 17-year-old female who suffered a relapse of anti-NMDAR encephalitis with aphasic features that included, similar to our patient, reduced non-fluent spontaneous speech, impaired naming and repetition, and phonemic paraphasias, in addition to orofacial, ideomotor, and constructive apraxias, the cortical aphasia and apraxias developing 15 days after initial presentation with headache, dizziness, nausea, and vomiting (Table 1).

This study is limited in that it is a single case report, but the case clearly demonstrates that anti-NMDAR encephalitis can present as a focal cortical disturbance, such as a non-fluent aphasia, without associated features of limbic encephalitis. Consideration should therefore be given to including focal cortical deficits as a possible presentation of this autoimmune condition to ensure early identification and treatment of future cases.

ACKNOWLEDGEMENT

The authors would like to thank the patient and her family.

STATEMENT OF AUTHORSHIP

Julien Hébert contributed to the drafting of the manuscript. Farah El-Sadi contributed clinical information on the case. Catherine Maurice contributed clinical information on the case and to the critical revision of the manuscript. Richard A. Wennberg contributed clinical information on the case and to the critical revision of the article. David F. Tang-Wai contributed to the critical revision of the manuscript and original conception and design of the manuscript. All authors approved the final version of the manuscript to be published.

DISCLOSURE INFORMATION

Julien Hébert, Farah El-Sadi, Catherine Maurice, Richard A. Wennberg, and David F. Tang-Wai have nothing to disclose.

FINANCIAL SUPPORT

None.

CONFLICTS OF INTEREST

The authors declare no conflicts of interest.

Julien Hébert
 Division of Neurology
 University of Toronto, Toronto
 ON, Canada (JH, FE-S)

Farah El-Sadi
 Division of Neurology
 University of Toronto, Toronto
 ON, Canada (JH, FE-S)

Catherine Maurice
 Princess Margaret Hospital, Toronto
 ON, Canada (CM)

Richard A. Wennberg
 Division of Neurology
 University of Toronto, Toronto Western Hospital
 Toronto, ON, Canada (RAW, DFT-W)

David F. Tang-Wai
 Division of Neurology
 University of Toronto, Toronto Western Hospital
 Toronto, ON, Canada (RAW, DFT-W)

Correspondence to: Julien Hébert, Toronto Western Hospital,
 399 Bathurst, St. 5WW441, Toronto, ON, Canada M5T 2S8.
 Email: julien.hebert@mail.utoronto.ca

REFERENCES

1. Taylor R, Mason W, Kong K, Wennberg RA. Reversible paraneoplastic encephalomyelitis associated with a benign ovarian teratoma. *Can J Neurol Sci.* 1999;26:317-20.
2. Dalmau J, Tüzün E, Wu H, et al. Paraneoplastic anti-N-methyl-D-aspartate receptor encephalitis associated with ovarian teratoma. *Ann Neurol.* 2007;61:25-36.
3. Dalmau J, Gleichman AJ, Hughes EJ, et al. Anti-NMDA-receptor encephalitis: case series and analysis of the effects of antibodies. *Lancet Neurol.* 2008;7:1091-8.
4. Wang W, Li J-M, Hu F-Y, et al. Anti-NMDA receptor encephalitis: clinical characteristics, predictors of outcome and the knowledge gap in southwest China. *Eur J Neurol.* 2015;23:621-9.
5. Titulaer MJ, McCracken L, Iñigo G, et al. Late-onset anti-NMDA receptor encephalitis. *Neurology.* 2013;81:1058-63.
6. Vahter L, Kannel K, Sorro U, Jaakmees H, Talvik T, Gross-Pajuu K. Cognitive dysfunction during anti-NMDA-receptor encephalitis is present in early phase of the disease. *Oxf Med Case Reports.* 2014;7:74-6.
7. Florance NR, Davis RL, Lam C, Szperka C, Zhou L, Ahmad S. Anti-N-methyl-D-aspartate receptor (NMDAR) encephalitis in children and adolescents. *Ann Neurol.* 2009;66:11-18.
8. Kumaran D, Pera MC, Maurey H, Chrétien P, Archambaud F, Bouilleret V. Sudden and isolated Broca's aphasia: a new clinical phenotype of anti NMDA receptor antibodies encephalitis in children. *Eur J Paediatr Neurol.* 2014;18:790-2.
9. Leon-Salas JM, Rosas R, Diaz-Victoria AR, Flores J, Ojeda-Lopez C, Espinola-Nadurille M. Cortical aphasia and apraxia as main clinical presentation of anti-NMDAR encephalitis relapse with a positive CSF PCR for cytomegalovirus. *Neuropsychiatry.* 2017;7:620-8.