

## DIAGNOSTIC CHALLENGE

## Answer

Naveed Nazir Shah, MD; Rakesh Bhargava, MD; Zuber Ahmed, MD; Deepak Kumar Pandey, MD; Mohd Shameem, MD; Arshad Altaf Bachh, MD; Khurshid Ahmad Dar, MD

The most likely diagnosis is bullous emphysema (answer a). The patient's chest x-ray shows hyperlucency of the left hemithorax with a mediastinal shift to the right. This radiologic pattern is seen with tension pneumothorax; however, the clinical scenario is not in keeping with this diagnosis (absence of shock, jugular venous pressure elevation or muffled heart sounds). The patient had no history of thoracic trauma or sudden chest pain suggestive of a pneumothorax. In addition, his symptoms progressed gradually. The appearance of the right hemithorax is due to atelectasis secondary to hyperinflation of the left lung and mediastinal shift toward the right, and is not in keeping with a diagnosis of pneumonia.

A contrast-enhanced CT scan of the chest was subsequently performed. This revealed large emphysematous bullae involving the entire left lung with a shift of the mediastinum to the right (Fig. 1). The patient's alpha-1 anti-trypsin level was normal (186 IU/L; normal range 93–224).

On the recommendation of our thoracic surgeons, a left pneumonectomy was performed. Postoperatively, the patient reported reduced dyspnea and improved exercise tolerance, and his pulmonary function tests were slightly improved (forced expiratory volume in 1 second [FEV<sub>1</sub>] = 2.21 L; 52% of predicted).

## Commentary

Emphysema is a pathologic process characterized by permanent enlargement of air spaces distal to the terminal bronchioles. Hyperinflation results from destruction of interalveolar septae and alveolar fusion into large air sacs. Leakage of air into the interstitium leads to the formation

of blebs and bullae. Giant bullae, while uncommon, can lead to the compression of the adjacent normal lung tissue. When emphysema is associated with large bullae, the condition is referred to as bullous emphysema.

Bullous emphysema usually occurs as a complication of chronic obstructive pulmonary disease; however, primary bullous emphysema can occur. This phenomenon was originally reported in 1937 by Burke,<sup>1</sup> who referred to it as “vanishing lung syndrome.” Burke described a series of young men who developed progressive dyspnea associated

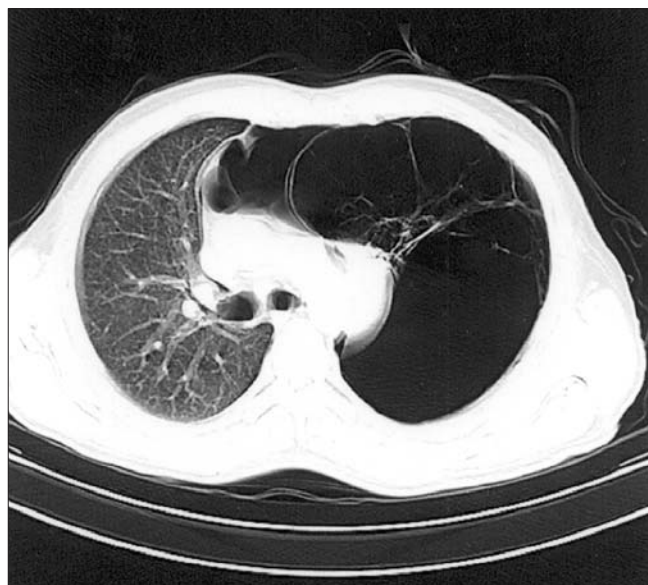


Fig. 1. A contrast-enhanced CT scan of the patient's chest showing large emphysematous bullae on the left with a shift of the mediastinum to the right. The radiolucent spaces divided by contrast-enhanced lines are bullae with their associated septae.

From the Department of Tuberculosis and Chest Diseases, Jawaharlal Nehru Medical College, Aligarh Muslim University, Aligarh, Uttar Pradesh, India

*Can J Emerg Med* 2007;9(3):233-4

with extensive and predominantly asymmetric upper lobe emphysema, eventually leading to respiratory failure.

Differentiating between bullous emphysema and a pneumothorax can be challenging. Patients with bullous emphysema complain of progressive dyspnea owing to a gradual increase in bullae size. Of note, bullae may occasionally regress spontaneously. Pneumothorax classically involves a history of sudden deterioration in respiratory function associated with chest pain, but some patients may present atypically. Moreover, bullae rupture in patients with bullous emphysema can lead to the development of acute respiratory distress. In unclear cases, a CT scan of the patient's chest will establish the diagnosis.<sup>2</sup> Emergency department ultrasonography may also be helpful in differentiating between these 2 diagnoses. In bullous emphysema, a bedside scan may reveal sliding of the lung tissue against the pleura during inspiration associated with "comet tail" artifacts, whereas in a pneumothorax such movement is absent.<sup>3</sup>

Patients with bullous emphysema may require a bullectomy. Indications for surgery include increasing bullae

size, pneumothorax, pulmonary insufficiency and bullous infection.<sup>4</sup> Total pneumonectomy may be indicated in patients with severe unilateral disease.

## References

1. Burke R. Vanishing lungs: a case report of bullous emphysema. *Radiology* 1937;28:367-71.
2. Waseem M, Jones J, Brutus S, et al. Giant bulla mimicking pneumothorax. *J Emerg Med* 2005;29:155-8.
3. Simon BC, Paolinetti L. Two cases where bedside ultrasound was able to distinguish pulmonary bleb from pneumothorax. *J Emerg Med* 2005;29:201-5.
4. Mehran RJ, Deslauriers J. Indications for surgery and patient work-up for bullectomy. *Chest Surg Clin N Am* 1995;5:717-34.

For the Challenge, see page 170.

---

**Correspondence to:** Dr. Naveed Nazir Shah, Department of Tuberculosis and Chest Diseases, Jawaharlal Nehru Medical College, Aligarh Muslim University, Aligarh, Uttar Pradesh, India 202002; naveednazirshah@yahoo.com